Settings

1 2 3 4 5 6 7 8 9 10 11 12 13 14 15 16 17 18 19 20 21 22 23 24 25 26 27 28 29 30

Item 1 of 40
Question Id: 1268

Mark | Previous | Next | Full Screen | Tutorial | Lab Values | Notes | Calculator | Reverse Color | Text Zoom | Settings

A 21-year-old Caucasian male suffers from weakness and gait disturbance. He noticed that he has had difficulty releasing the doorknob lately. Physical examination shows cataracts, frontal baldness, and gonadal atrophy. Biopsy shows muscle atrophy involving mostly type 1 fibers. The patient's condition is best described as which of the following?

A. Denervation muscle atrophy

B. Myotonic dystrophy

C. Inflammatory myopathy

D. Ion channel myopathy

E. Myasthenia gravis

F. Oxidative phosphorylation disease

Submit

Block Time Remaining: 00:00:02
TUTOR

2 | Feedback | Suspend | End Block

A 21-year-old Caucasian male suffers from weakness and gait disturbance. He noticed that he has had difficulty releasing the doorknob lately. Physical examination shows cataracts, frontal baldness, and gonadal atrophy. Biopsy shows muscle atrophy involving mostly type 1 fibers. The patient's condition is best described as which of the following?

- A. Denervation muscle atrophy (8%)
- ✓ B. Myotonic dystrophy (58%)
- C. Inflammatory myopathy (5%)
- D. Ion channel myopathy (6%)
- E. Myasthenia gravis (4%)
- F. Oxidative phosphorylation disease (16%)

Omitted
Correct answer
B

58%
Answered correctly

03 secs
Time Spent

02/03/2020
Last Updated

Explanation

Abnormally slow relaxation of muscles is called myotonia. Classic symptoms of myotonic muscular dystrophy are difficulty loosening one's grip after a handshake or inability to release the doorknob. Myotonic muscular dystrophy is the second most common inherited muscle disorder (Duchenne muscle dystrophy is the most common).

Abnormally slow relaxation of muscles is called myotonia. Classic symptoms of myotonic muscular dystrophy are difficulty loosening one's grip after a handshake or inability to release the doorknob. Myotonic muscular dystrophy is the second most common inherited muscle disorder (Duchenne muscle dystrophy is the most common).

Myotonic dystrophy is inherited as an autosomal dominant trait. It occurs because of an abnormal trinucleotide repeat expansion (CTG) of the gene that codes for a myotonia-protein kinase. The number of repeats increases with subsequent generation, causing increasingly severe disease in each generation (anticipation).

Age of presentation varies from early childhood to late adulthood. Skeletal muscle involvement includes myotonia (sustained muscle contraction). Cataracts are seen in almost all patients—frontal balding and gonadal atrophy are other common features.

On light microscopy, atrophy of muscle fibers is prominent. Type 1 fibers are more affected. Unlike Duchenne muscular dystrophy, necrosis of muscle fibers and fibrofatty replacement are not common in myotonic dystrophy.

(Choice A) Denervation muscle atrophy is caused by axonal destruction. It occurs due to trauma, ischemia, or generalized disease (such as amyotrophic lateral sclerosis). Clinically, denervation leads to muscle paralysis and atrophy.

(Choice C) Dermatomyositis and polymyositis are examples of inflammatory myopathies.

(Choice D) Ion channel myopathies manifest with myotonia and episodes of hypotonic paralysis (often associated with exercise). No muscle atrophy is seen on light microscopy. PAS-positive intracytoplasmic vacuoles are found in these conditions.

(Choices E and F) Neither myasthenia gravis, nor mitochondrial myopathies lead to myotonia with preferential atrophy of type 1 fibers.

Educational Objective:
Myotonic dystrophy is an autosomal-dominant disorder. It is caused by an increased number of trinucleotide repeats on myotonia-protein kinase gene. Sustained muscle contraction (myotonia), along with weakness and atrophy, is common. Cataracts are seen in almost all patients. Frontal balding and gonadal atrophy are other common features.

Pathology Nervous System Myotonic Dystrophy

Myotonic dystrophy is inherited as an autosomal dominant trait. It occurs because of an abnormal trinucleotide repeat expansion (CTG) of the gene that codes for a myotonia-protein kinase. The number of repeats increases with subsequent generation, causing increasingly severe disease in each generation (anticipation).

Age of presentation varies from early childhood to late adulthood. Skeletal muscle involvement includes myotonia (sustained muscle contraction). Cataracts are seen in almost all patients—frontal balding and gonadal atrophy are other common features.

On light microscopy, atrophy of muscle fibers is prominent. Type 1 fibers are more affected. Unlike Duchenne muscular dystrophy, necrosis of muscle fibers and fibrofatty replacement are not common in myotonic dystrophy.

(Choice A) Denervation muscle atrophy is caused by axonal destruction. It occurs due to trauma, ischemia, or generalized disease (such as amyotrophic lateral sclerosis). Clinically, denervation leads to muscle paralysis and atrophy.

(Choice C) Dermatomyositis and polymyositis are examples of inflammatory myopathies.

(Choice D) Ion channel myopathies manifest with myotonia and episodes of hypotonic paralysis (often associated with exercise). No muscle atrophy is seen on light microscopy. PAS-positive intracytoplasmic vacuoles are found in these conditions.

(Choices E and F) Neither myasthenia gravis, nor mitochondrial myopathies lead to myotonia with preferential atrophy of type 1 fibers.

Educational Objective:
Myotonic dystrophy is an autosomal-dominant disorder. It is caused by an increased number of trinucleotide repeats on myotonia-protein kinase gene. Sustained muscle contraction (myotonia), along with weakness and atrophy, is common. Cataracts are seen in almost all patients. Frontal balding and gonadal atrophy are other common features.

Pathology	Nervous System	Myotonic Dystrophy
Subject	System	Topic

Copyright © UWorld. All rights reserved.

Settings

1 2 3 4 5 6 7 8 9 10 11 12 13 14 15 16 17 18 19 20 21 22 23 24 25 26 27 28 29 30

Item 2 of 40
Question Id: 672

Mark | Previous | Next | Full Screen | Tutorial | Lab Values | Notes | Calculator | Reverse Color | Text Zoom | Settings

A 15-year-old boy is brought to the office by his mother due to difficulty with movement. The patient enjoys playing high school basketball but had to leave the team this year due to his progressively worsening symptoms. On examination, he is found to have significant kyphoscoliosis and a high plantar arch. His older brother suffered from a neurologic disorder and died of heart failure at age 25. This patient most likely has which of the following neuropathologic findings?

A. Atrophy of the caudate nucleus

B. Cerebral cortex atrophy

C. Degeneration of the spinocerebellar tracts

D. Demyelination of peripheral nerves

E. Loss of neurons in the anterior horn of the spinal cord

F. Loss of neurons in the substantia nigra

Submit

Block Time Remaining: 00:00:03
TUTOR

3 | Feedback | Suspend | End Block

A 15-year-old boy is brought to the office by his mother due to difficulty with movement. The patient enjoys playing high school basketball but had to leave the team this year due to his progressively worsening symptoms. On examination, he is found to have significant kyphoscoliosis and a high plantar arch. His older brother suffered from a neurologic disorder and died of heart failure at age 25. This patient most likely has which of the following neuropathologic findings?

- A. Atrophy of the caudate nucleus (5%)
- B. Cerebral cortex atrophy (3%)
- ✓ C. Degeneration of the spinocerebellar tracts (62%)
- D. Demyelination of peripheral nerves (12%)
- E. Loss of neurons in the anterior horn of the spinal cord (15%)
- F. Loss of neurons in the substantia nigra (1%)

Omitted
Correct answer
C

62%
Answered correctly

01 sec
Time Spent

05/23/2020
Last Updated

Explanation

Friedreich ataxia

1
2
3
4
5
6
7
8
9
10
11
12
13
14
15
16
17
18
19
20
21
22
23
24
25
26
27
28
29
30

Friedreich ataxia

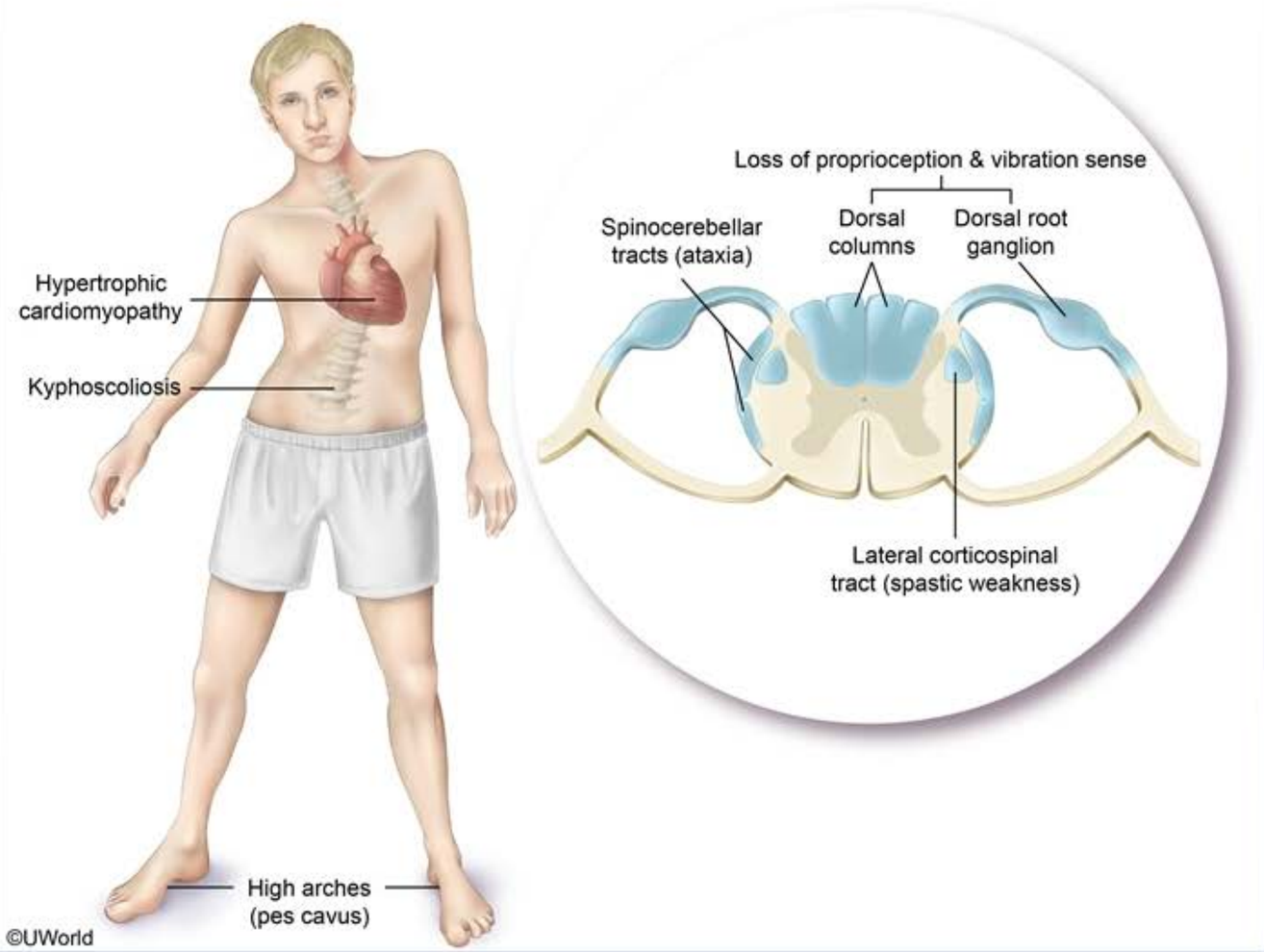

Friedreich ataxia is an autosomal recessive disorder caused by mutation of the frataxin (*FXN*) gene. This gene codes for an essential

©UWorld

Friedreich ataxia is an autosomal recessive disorder caused by mutation of the frataxin (*FXN*) gene. This gene codes for an essential mitochondrial protein involved in the assembly of iron-sulfur enzymes. An increased number of trinucleotide repeats (GAA) is present in the mutated gene, causing decreased *FXN* expression. This leads to decreased mitochondrial energy production and increased oxidative stress, resulting in degeneration of neural tracts and peripheral nerves. The following sites of involvement are characteristic:

1. Spinocerebellar and lateral corticospinal tract degeneration causes **gait ataxia** and spastic muscle weakness, respectively.
2. Degeneration of the dorsal columns and dorsal root ganglia causes **loss of position and vibration** sensation.
3. **Kyphoscoliosis and foot abnormalities** (pes cavus) are characteristic skeletal deformities.
4. Heart involvement includes **hypertrophic cardiomyopathy** and congestive heart failure.
5. **Diabetes mellitus** develops in about 10% of patients with Friedreich ataxia.

(Choice A) Huntington disease is an autosomal dominant disorder caused by trinucleotide repeats (CAG) in the huntingtin (*HTT*) gene, which results in severe neuronal loss in the caudate nucleus. This condition manifests with dementia, behavioral abnormalities, and choreiform movements.

(Choice B) Cerebral cortex atrophy occurs in Alzheimer and Pick diseases. Alzheimer disease is characterized by diffuse, mild cortical atrophy and progressive memory loss. Pick disease causes pronounced frontotemporal atrophy, illustrated by behavioral and emotional abnormalities.

(Choice D) Charcot-Marie-Tooth disease is an autosomal dominant disorder associated with demyelination of peripheral nerves. Typical findings include distal leg weakness/atrophy with sensory deficits, pes cavus, and kyphoscoliosis; cardiomyopathy is not characteristic.

(Choice E) Loss of neurons in the anterior horn of the spinal cord occurs in poliomyelitis and leads to flaccid paralysis, atrophy, areflexia, and muscle fasciculations. Damage of these neurons also occurs in amyotrophic lateral sclerosis.

(Choice F) Loss of neurons of the substantia nigra occurs in Parkinson disease, which manifests with bradykinesia, rigidity, and a resting "pill-rolling" tremor.

Educational objective:
Friedreich ataxia is characterized by cerebellar ataxia (spinocerebellar tract degeneration) and loss of position/vibration sensation (dorsal

5. **Diabetes mellitus** develops in about 10% of patients with Friedreich ataxia.

(Choice A) Huntington disease is an autosomal dominant disorder caused by trinucleotide repeats (CAG) in the huntingtin (*HTT*) gene, which results in severe neuronal loss in the caudate nucleus. This condition manifests with dementia, behavioral abnormalities, and choreiform movements.

(Choice B) Cerebral cortex atrophy occurs in Alzheimer and Pick diseases. Alzheimer disease is characterized by diffuse, mild cortical atrophy and progressive memory loss. Pick disease causes pronounced frontotemporal atrophy, illustrated by behavioral and emotional abnormalities.

(Choice D) Charcot-Marie-Tooth disease is an autosomal dominant disorder associated with demyelination of peripheral nerves. Typical findings include distal leg weakness/atrophy with sensory deficits, pes cavus, and kyphoscoliosis; cardiomyopathy is not characteristic.

(Choice E) Loss of neurons in the anterior horn of the spinal cord occurs in poliomyelitis and leads to flaccid paralysis, atrophy, areflexia, and muscle fasciculations. Damage of these neurons also occurs in amyotrophic lateral sclerosis.

(Choice F) Loss of neurons of the substantia nigra occurs in Parkinson disease, which manifests with bradykinesia, rigidity, and a resting "pill-rolling" tremor.

Educational objective:
Friedreich ataxia is characterized by cerebellar ataxia (spinocerebellar tract degeneration) and loss of position/vibration sensation (dorsal column/dorsal root ganglia degeneration), kyphoscoliosis, and hypertrophic cardiomyopathy. Foot abnormalities and diabetes mellitus are also common.

References

- Clinical features of Friedreich's ataxia: classical and atypical phenotypes.

Pathology	Nervous System	Friedreich ataxia
Subject	System	Topic

Copyright © UWorld. All rights reserved.

Settings

1 2 3 4 5 6 7 8 9 10 11 12 13 14 15 16 17 18 19 20 21 22 23 24 25 26 27 28 29 30

Item 3 of 40
Question Id: 23

Mark | Previous | Next | Full Screen | Tutorial | Lab Values | Notes | Calculator | Reverse Color | Text Zoom | Settings

A 58-year-old homeless man is brought to the emergency department after being found unresponsive on a sidewalk. The patient has been hospitalized on several occasions for alcohol and illicit drug intoxication. He also has a history of hypertension but is not adherent with medical therapy. On arrival, the patient is obtunded, febrile, and hypotensive. Physical examination reveals lung crackles and a new blowing diastolic murmur consistent with aortic regurgitation. Appropriate treatment is started, but the patient dies several days later. Autopsy examination shows symmetric, bilateral wedge-shaped strips of necrosis over the cerebral convexity, parallel and a few centimeters lateral to the interhemispheric cerebral fissure. Which of the following is the most likely cause of this patient's cerebral findings?

A. Amyloid deposition in cerebral arteries

B. Cerebral embolization of heart valve vegetations

C. Generalized reduction of cerebral perfusion

D. Hypertension-induced microaneurysm formation

E. Localized weakness and rupture of arterial walls

Submit

Block Time Remaining: 00:00:04
TUTOR

4 | Feedback | Suspend | End Block

Settings

1 2 3 4 5 6 7 8 9 10 11 12 13 14 15 16 17 18 19 20 21 22 23 24 25 26 27 28 29 30

Item 3 of 40
Question Id: 23

Mark | Previous | Next | Full Screen | Tutorial | Lab Values | Notes | Calculator | Reverse Color | Text Zoom | Settings

A 58-year-old homeless man is brought to the emergency department after being found unresponsive on a sidewalk. The patient has been hospitalized on several occasions for alcohol and illicit drug intoxication. He also has a history of hypertension but is not adherent with medical therapy. On arrival, the patient is obtunded, febrile, and hypotensive. Physical examination reveals lung crackles and a new blowing diastolic murmur consistent with aortic regurgitation. Appropriate treatment is started, but the patient dies several days later. Autopsy examination shows symmetric, bilateral wedge-shaped strips of necrosis over the cerebral convexity, parallel and a few centimeters lateral to the interhemispheric cerebral fissure. Which of the following is the most likely cause of this patient's cerebral findings?

A. Amyloid deposition in cerebral arteries (2%)

B. Cerebral embolization of heart valve vegetations (37%)

✓ C. Generalized reduction of cerebral perfusion (45%)

D. Hypertension-induced microaneurysm formation (10%)

E. Localized weakness and rupture of arterial walls (3%)

Omitted
Correct answer
C

45%
Answered correctly

01 sec
Time Spent

03/24/2020
Last Updated

Explanation

Cerebral watershed zones

Block Time Remaining: 00:00:05
TUTOR

4 | Feedback | Suspend | End Block

1 2 3 4 5 6 7 8 9 10 11 12 13 14 15 16 17 18 19 20 21 22 23 24 25 26 27 28 29 30

Cerebral watershed zones

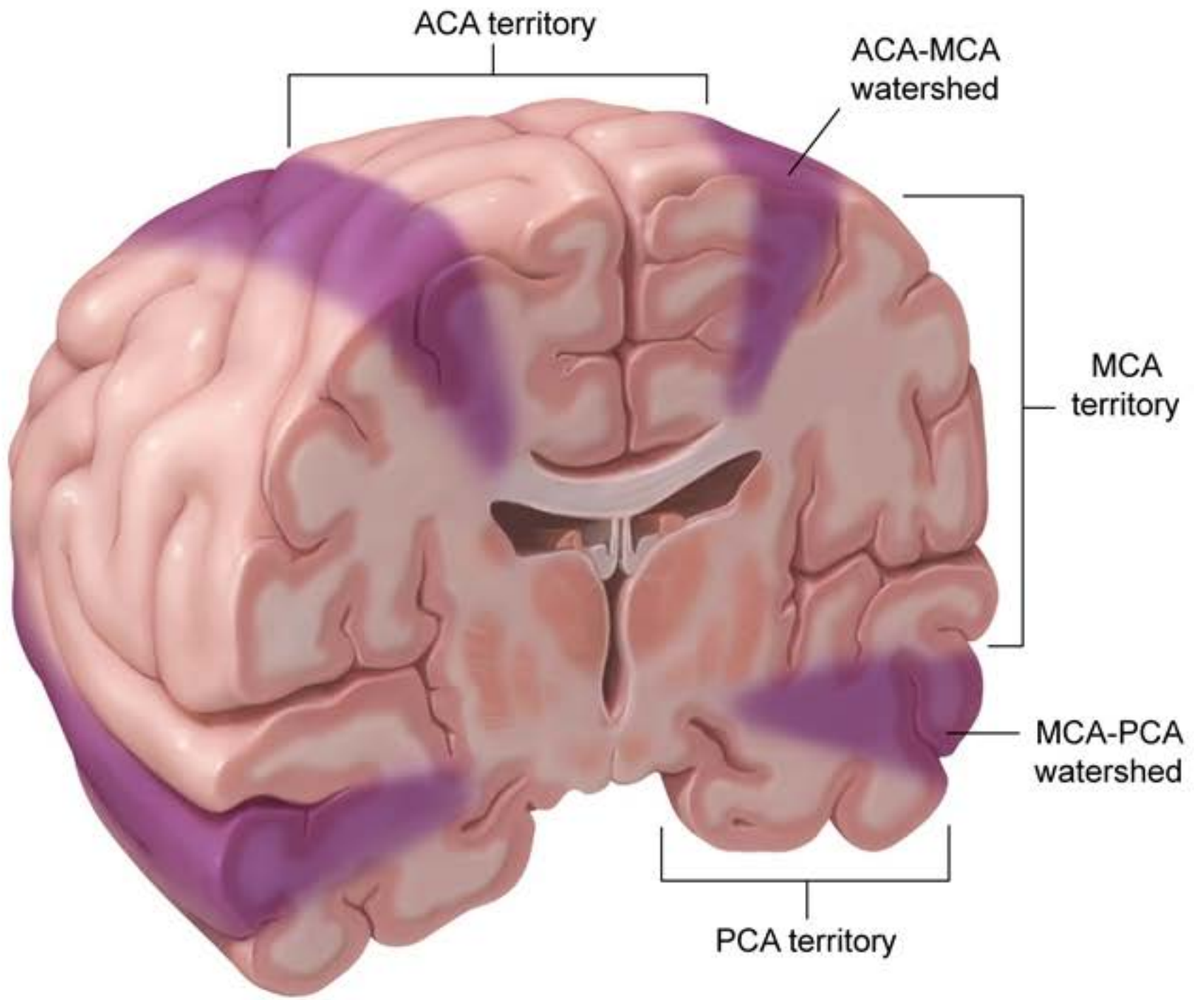

ACA = anterior cerebral artery; **MCA** = middle cerebral artery; **PCA** = posterior cerebral artery.

©UWorld

This patient with a history of drug use developed fever and new-onset aortic regurgitation, which are suggestive of endocarditis. His pulmonary edema (crackles) and hypotension are due to subsequent **cardiogenic shock**. On autopsy, the symmetric, bilateral wedge-shaped strips of necrosis over the cerebral convexity are characteristic of **global cerebral ischemia**.

Profound **systemic hypotension** (eg, cardiogenic shock, cardiopulmonary arrest) diminishes blood supply to the entire brain, resulting in **neuron cell death** in areas that are vulnerable to hypoxia. This includes brain regions with high metabolic demand (eg, hippocampus, cerebellar Purkinje cells) and areas supplied by the distal-most branches of cerebral arteries (**watershed zones**). These border zones are located between areas supplied by the anterior, middle, and posterior cerebral arteries and are vulnerable because of low baseline perfusion pressure. The resulting necrosis occurs in bilateral, **wedge-shaped** strips that can extend from the frontal to occipital lobe and are located parallel and a few centimeters lateral to the interhemispheric fissure.

(Choice A) Cerebral amyloid angiopathy typically affects patients over the age of 70 and results in lobar hemorrhages (eg, occipital, parietal) rather than ischemia. Amyloidosis can also cause cardiomyopathy, although patients typically develop right-sided heart failure (eg, edema, ascites) rather than valvular insufficiency.

(Choice B) Although infectious endocarditis frequently causes embolization of bacterial vegetations, cardiac embolism would likely cause multiple scattered infarcts in an **asymmetric** pattern within different major vascular territories (eg, middle and anterior cerebral artery). This patient's symmetric, bilateral infarcts correspond to the cortical watershed regions and are more suggestive of global cerebral ischemia.

(Choice D) Charcot-Bouchard aneurysms form as a result of chronic hypertension, and a rupture causes intracerebral hemorrhage typically involving deep brain structures (eg, basal ganglia, cerebellar nuclei, thalamus, pons).

(Choice E) Saccular aneurysms, which occur at areas of weakness in cerebral arteries, typically cause subarachnoid hemorrhage after a rupture rather than cerebral ischemia. Patients usually have sudden-onset severe (thunderclap) headache and meningismus.

Educational objective:
Sustained cerebral hypoperfusion (eg, hypotension, shock) may cause global cerebral ischemia and watershed infarction. These watershed zones are located at the borders between areas perfused by the anterior, middle, and posterior cerebral arteries and typically appear as symmetric, bilateral wedge-shaped strips of necrosis over the cerebral convexity, parallel and adjacent to the interhemispheric fissure.

necrosis occurs in bilateral, **wedge-shaped** strips that can extend from the frontal to occipital lobe and are located parallel and a few centimeters lateral to the interhemispheric fissure.

(Choice A) Cerebral amyloid angiopathy typically affects patients over the age of 70 and results in lobar hemorrhages (eg, occipital, parietal) rather than ischemia. Amyloidosis can also cause cardiomyopathy, although patients typically develop right-sided heart failure (eg, edema, ascites) rather than valvular insufficiency.

(Choice B) Although infectious endocarditis frequently causes embolization of bacterial vegetations, cardiac embolism would likely cause multiple scattered infarcts in an **asymmetric** pattern within different major vascular territories (eg, middle and anterior cerebral artery). This patient's symmetric, bilateral infarcts correspond to the cortical watershed regions and are more suggestive of global cerebral ischemia.

(Choice D) Charcot-Bouchard aneurysms form as a result of chronic hypertension, and a rupture causes intracerebral hemorrhage typically involving deep brain structures (eg, basal ganglia, cerebellar nuclei, thalamus, pons).

(Choice E) Saccular aneurysms, which occur at areas of weakness in cerebral arteries, typically cause subarachnoid hemorrhage after a rupture rather than cerebral ischemia. Patients usually have sudden-onset severe (thunderclap) headache and meningismus.

Educational objective:
Sustained cerebral hypoperfusion (eg, hypotension, shock) may cause global cerebral ischemia and watershed infarction. These watershed zones are located at the borders between areas perfused by the anterior, middle, and posterior cerebral arteries and typically appear as symmetric, bilateral wedge-shaped strips of necrosis over the cerebral convexity, parallel and adjacent to the interhemispheric fissure.

References

- Border zone infarcts: pathophysiologic and imaging characteristics

Pathology	Nervous System	Ischemic stroke
Subject	System	Topic

Copyright © UWorld. All rights reserved.

Settings

Item 3 of 40
Question Id: 23

Mark | Previous | Next | Full Screen | Tutorial | Lab Values | Notes | Calculator | Reverse Color | Text Zoom | Settings

necrosis occurs in bilateral **wedge-shaped** strips that can extend from the frontal to occipital lobe and are located parallel and a few centimeters

Exhibit Display

Cortical embolic infarcts

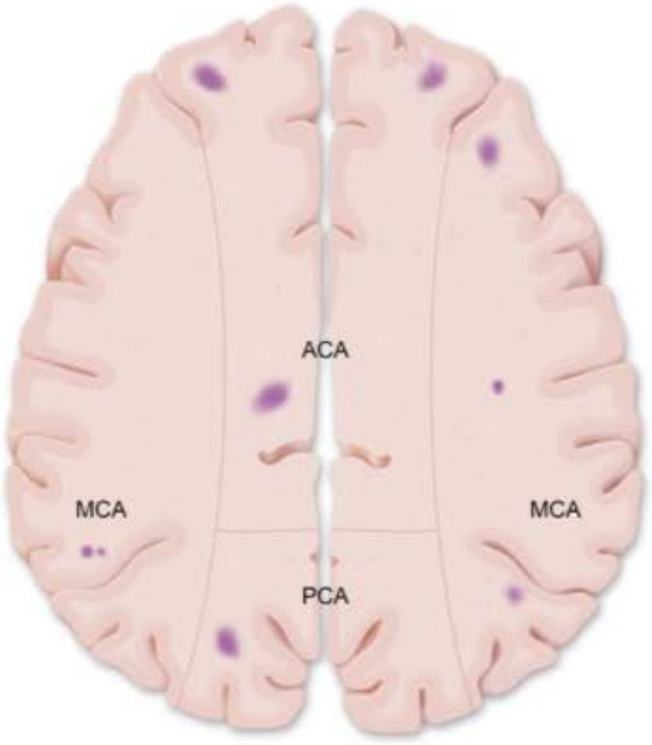

ACA = anterior cerebral artery; **MCA** = middle cerebral artery; **PCA** = posterior cerebral artery.

©UWorld

Zoom In | Zoom Out | Reset | Add To New Card | Existing Card

Block Time Remaining: 00:00:05
TUTOR

4 | Feedback | Suspend | End Block

Settings

Item 3 of 40
Question Id: 23

Mark | Previous | Next | Full Screen | Tutorial | Lab Values | Notes | Calculator | Reverse Color | Text Zoom | Settings

necrosis occurs in bilateral **wedge-shaped** strips that can extend from the frontal to occipital lobe and are located parallel and a few centimeters

Exhibit Display

Cortical watershed infarcts

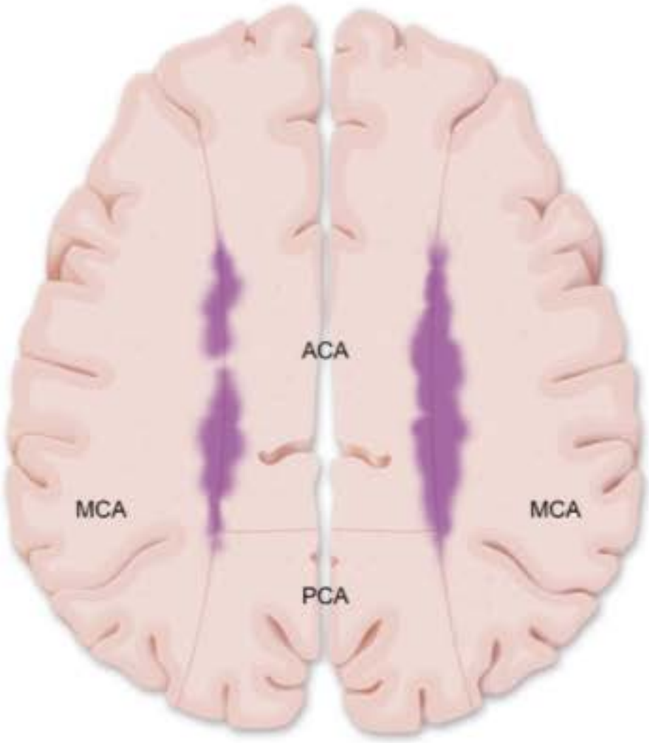

ACA = anterior cerebral artery; **MCA** = middle cerebral artery; **PCA** = posterior cerebral artery.

©UWorld

Zoom In | Zoom Out | Reset | Add To New Card | Existing Card

Block Time Remaining: 00:00:05
TUTOR

4 | Feedback | Suspend | End Block

A 61-year-old man is evaluated in the clinic due to trouble seeing for the past 6 months. The patient's eyes "get tired easily," especially in the late afternoon and evening. He has smoked a pack of cigarettes daily for the past 35 years but does not use alcohol or illicit drugs. On physical examination, there is weakness of the extraocular muscles. Pupillary reflex, deep tendon reflexes, and sensation are normal. A contrast-enhanced CT scan of the chest is shown in the image.

Which of the following is the most likely mechanism of this patient's condition?

Settings

1 2 3 4 5 6 7 8 9 10 11 12 13 14 15 16 17 18 19 20 21 22 23 24 25 26 27 28 29 30

Item 4 of 40
Question Id: 749

Mark | Previous | Next | Full Screen | Tutorial | Lab Values | Notes | Calculator | Reverse Color | Text Zoom | Settings

Which of the following is the most likely mechanism of this patient's condition?

A. Antibodies against a neurotransmitter receptor

B. Antibodies against the presynaptic calcium channel

C. $CD8^+$ lymphocyte–mediated nerve fiber demyelination

D. $CD8^+$ lymphocyte–mediated skeletal muscle damage

E. Vascular deposition of circulating immune complexes

Submit

Block Time Remaining: 00:00:08
TUTOR

4 | Feedback | Suspend | End Block

Settings

1 2 3 4 5 6 7 8 9 10 11 12 13 14 15 16 17 18 19 20 21 22 23 24 25 26 27 28 29 30

Item 4 of 40
Question Id: 749

Mark | Previous | Next | Full Screen | Tutorial | Lab Values | Notes | Calculator | Reverse Color | Text Zoom | Settings

Which of the following is the most likely mechanism of this patient's condition?

- ✓ A. Antibodies against a neurotransmitter receptor (64%)
- B. Antibodies against the presynaptic calcium channel (25%)
- C. $CD8^+$ lymphocyte–mediated nerve fiber demyelination (4%)
- D. $CD8^+$ lymphocyte–mediated skeletal muscle damage (1%)
- E. Vascular deposition of circulating immune complexes (4%)

Omitted
Correct answer

64%
Answered correctly

06 secs
Time Spent

02/21/2020
Last Updated

Block Time Remaining: 00:00:11
TUTOR

4 | Feedback | Suspend | End Block

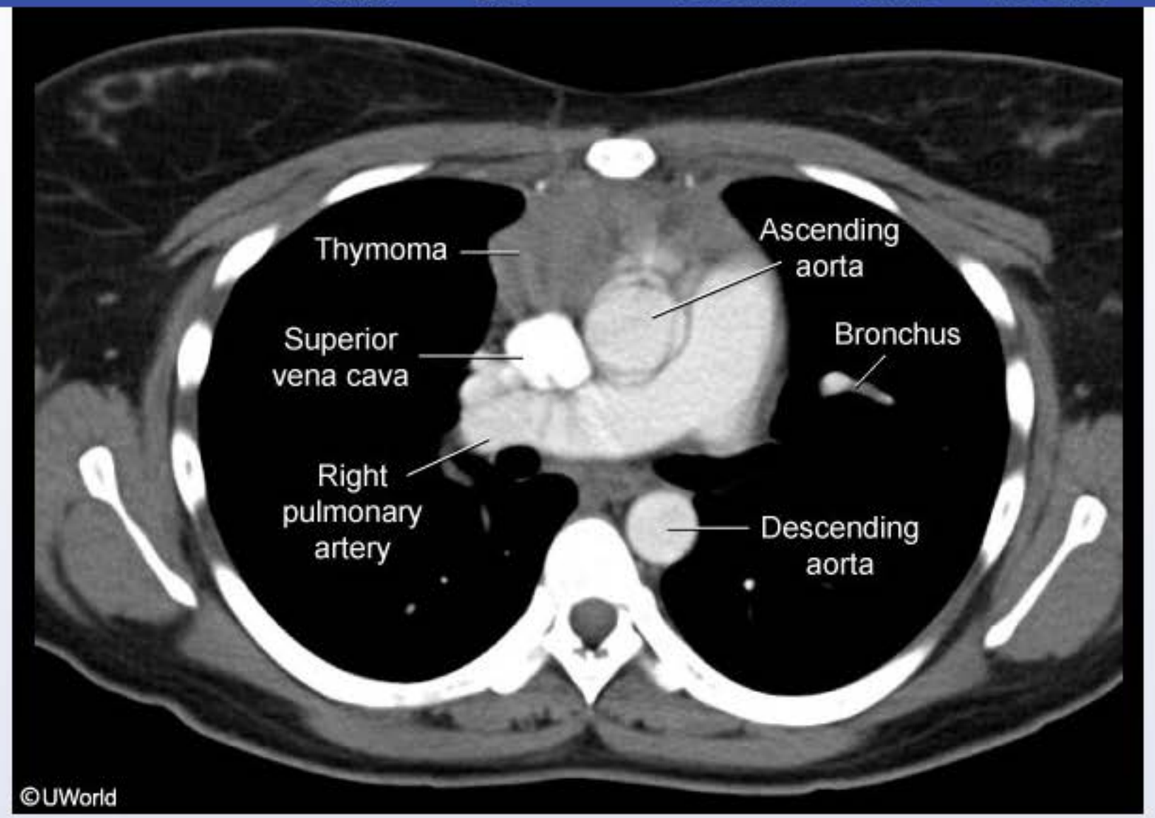

This patient's presentation is consistent with **myasthenia gravis** (MG), an autoimmune disease caused by **autoantibodies** directed against **nicotinic acetylcholine receptors** on the postsynaptic membrane of the neuromuscular junction. Acetylcholine binding normally causes opening of these ligand-gated sodium channels, and the subsequent influx of sodium ions generates a rise in end plate potential. To produce a self-propagating muscle action potential, there must be a sufficient number of activated acetylcholine receptors to allow the end plate potential to reach threshold. In MG, antibody binding leads to receptor degradation and complement-mediated damage of the postsynaptic membrane, preventing action potentials from being triggered.

Patients commonly have **fluctuating weakness** that worsens over the course of the day and most often involves the **extraocular** (eg, ptosis,

This patient's presentation is consistent with **myasthenia gravis** (MG), an autoimmune disease caused by **autoantibodies** directed against **nicotinic acetylcholine receptors** on the postsynaptic membrane of the neuromuscular junction. Acetylcholine binding normally causes opening of these ligand-gated sodium channels, and the subsequent influx of sodium ions generates a rise in end plate potential. To produce a self-propagating muscle action potential, there must be a sufficient number of activated acetylcholine receptors to allow the end plate potential to reach threshold. In MG, antibody binding leads to receptor degradation and complement-mediated damage of the postsynaptic membrane, preventing action potentials from being triggered.

Patients commonly have **fluctuating weakness** that worsens over the course of the day and most often involves the **extraocular** (eg, ptosis, diplopia) and bulbar (eg, fatigable chewing, dysphagia) muscles. Ptosis can increase when the patient is instructed to sustain an upward gaze, and electrophysiologic studies may demonstrate decreasing force of muscle contraction with repetitive stimulation. Most patients also have thymic abnormalities (eg, **thymoma**, thymic hyperplasia) that may appear as an anterior mediastinal mass on chest imaging.

(Choice B) Lambert-Eaton syndrome is due to autoantibodies directed against the presynaptic calcium channel, which causes reduced acetylcholine release. Patients usually have proximal extremity weakness that improves with muscle use, as opposed to the fatigable weakness of the extraocular and bulbar muscles common in MG. Lambert-Eaton syndrome commonly occurs in patients with small cell lung cancer.

(Choice C) Guillain-Barré syndrome is caused by segmental demyelination of peripheral nerves by both infiltrating T lymphocytes ($CD8^+$) and autoantibody formation. Patients with this acute inflammatory polyneuropathy usually have symmetric ascending muscle weakness that is often preceded by *Campylobacter* infection.

(Choice D) Polymyositis is an autoimmune disease that occurs due to $CD8^+$ lymphocyte–mediated skeletal muscle damage and usually presents with symmetric proximal muscle weakness.

(Choice E) Vascular deposition of circulating immune complexes occurs in systemic lupus erythematosus, rheumatoid arthritis, and other connective tissue disorders. Immune complex deposition leads to inflammation of blood vessel walls (vasculitis) in various tissues and organs.

Educational objective:
Myasthenia gravis is caused by circulating antibodies directed against acetylcholine receptors of the neuromuscular junction. Autoantibody binding leads to receptor degradation, producing fluctuating weakness that worsens over the course of the day and most commonly affects the extraocular muscles (eg, ptosis, diplopia). Most patients also have thymic abnormalities (eg, thymoma).

This patient's presentation is consistent with **myasthenia gravis** (MG), an autoimmune disease caused by **autoantibodies** directed against

Exhibit Display

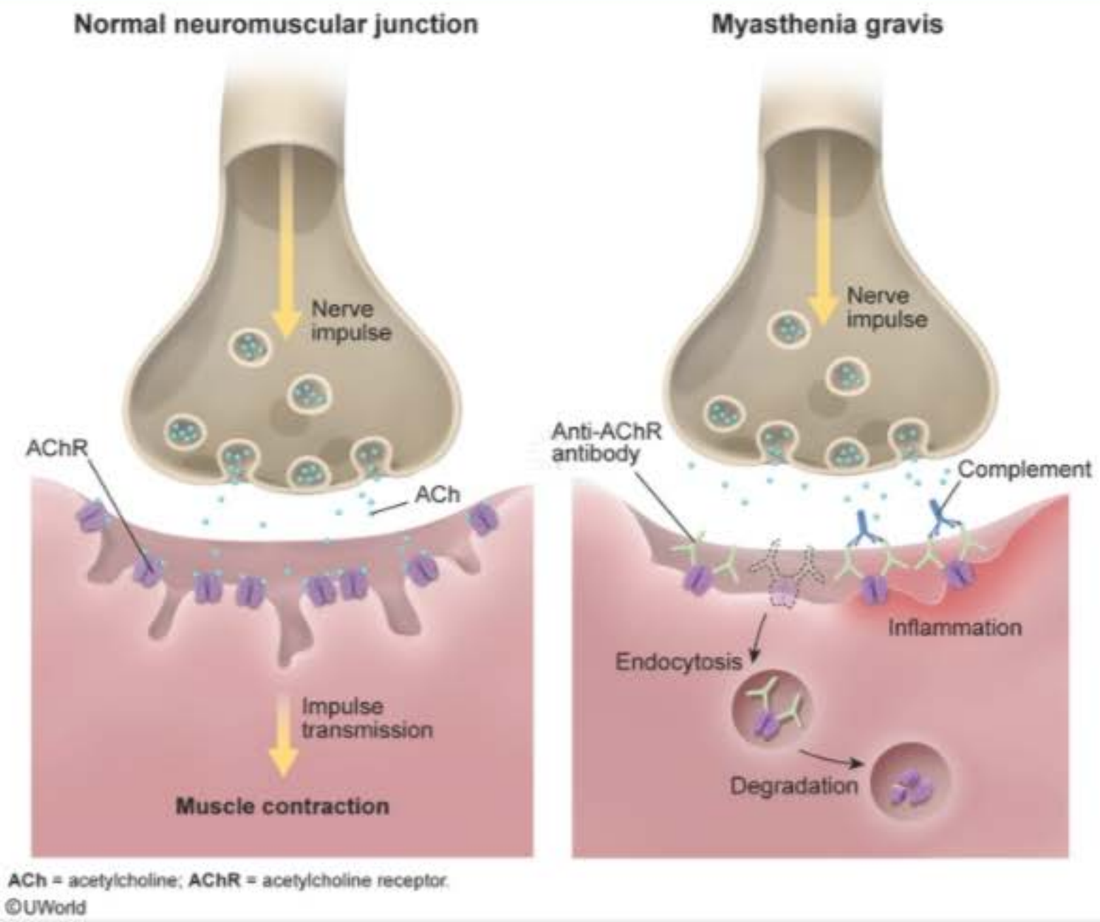

ACh = acetylcholine; AChR = acetylcholine receptor.
©UWorld

Zoom In | Zoom Out | Reset | Add To New Card | Existing Card

extraocular muscles (eg, ptosis, diplopia). Most patients also have thymic abnormalities (eg, thymoma).

and electrophysiologic studies may demonstrate decreasing force of muscle contraction with repetitive stimulation. Most patients also have thymic abnormalities (eg, **thymoma**, thymic hyperplasia) that may appear as an anterior mediastinal mass on chest imaging.

(Choice B) Lambert-Eaton syndrome is due to autoantibodies directed against the presynaptic calcium channel, which causes reduced acetylcholine release. Patients usually have proximal extremity weakness that improves with muscle use, as opposed to the fatigable weakness of the extraocular and bulbar muscles common in MG. Lambert-Eaton syndrome commonly occurs in patients with small cell lung cancer.

(Choice C) Guillain-Barré syndrome is caused by segmental demyelination of peripheral nerves by both infiltrating T lymphocytes ($CD8^+$) and autoantibody formation. Patients with this acute inflammatory polyneuropathy usually have symmetric ascending muscle weakness that is often preceded by *Campylobacter* infection.

(Choice D) Polymyositis is an autoimmune disease that occurs due to $CD8^+$ lymphocyte–mediated skeletal muscle damage and usually presents with symmetric proximal muscle weakness.

(Choice E) Vascular deposition of circulating immune complexes occurs in systemic lupus erythematosus, rheumatoid arthritis, and other connective tissue disorders. Immune complex deposition leads to inflammation of blood vessel walls (vasculitis) in various tissues and organs.

Educational objective:
Myasthenia gravis is caused by circulating antibodies directed against acetylcholine receptors of the neuromuscular junction. Autoantibody binding leads to receptor degradation, producing fluctuating weakness that worsens over the course of the day and most commonly affects the extraocular muscles (eg, ptosis, diplopia). Most patients also have thymic abnormalities (eg, thymoma).

References

- Myasthenia gravis: a review.

Pathology	Nervous System	Myasthenia gravis
Subject	System	Topic

Copyright © UWorld. All rights reserved.

Settings

1 2 3 4 5 6 7 8 9 10 11 12 13 14 15 16 17 18 19 20 21 22 23 24 25 26 27 28 29 30

Item 5 of 40
Question Id: 11576

Mark | Previous | Next | Full Screen | Tutorial | Lab Values | Notes | Calculator | Reverse Color | Text Zoom | Settings

A 65-year-old man comes to the emergency department with right upper and lower extremity weakness and slurred speech. The patient went to bed in his usual state of health and woke up with these symptoms. His medical problems include type 2 diabetes mellitus, hypertension, and hyperlipidemia. He takes atorvastatin, metformin, lisinopril, and low-dose aspirin. The patient has smoked a pack of cigarettes daily for the past 40 years. His temperature is 36.7 C (98 F), blood pressure is 160/90 mm Hg, and pulse is 118/min. He is mildly dysarthric with a right lower facial droop and right-sided hemiparesis. A noncontrast head CT is normal. Brain MRI reveals an acute subcortical infarct in the left internal capsule. Six months later, which of the following findings is most likely to be observed in the affected pyramidal tracts of this patient?

- A. Calcification
- B. Cytotoxic edema
- C. Eosinophilic neurons
- D. Hemorrhagic transformation
- E. Neutrophilic infiltration
- F. Persistent myelin debris
- G. Vasogenic edema

Submit

Block Time Remaining: 00:00:11
TUTOR

3 | Feedback | Suspend | End Block

A 65-year-old man comes to the emergency department with right upper and lower extremity weakness and slurred speech. The patient went to bed in his usual state of health and woke up with these symptoms. His medical problems include type 2 diabetes mellitus, hypertension, and hyperlipidemia. He takes atorvastatin, metformin, lisinopril, and low-dose aspirin. The patient has smoked a pack of cigarettes daily for the past 40 years. His temperature is 36.7 C (98 F), blood pressure is 160/90 mm Hg, and pulse is 118/min. He is mildly dysarthric with a right lower facial droop and right-sided hemiparesis. A noncontrast head CT is normal. Brain MRI reveals an acute subcortical infarct in the left internal capsule. Six months later, which of the following findings is most likely to be observed in the affected pyramidal tracts of this patient?

- A. Calcification (33%)
- B. Cytotoxic edema (4%)
- C. Eosinophilic neurons (10%)
- D. Hemorrhagic transformation (7%)
- E. Neutrophilic infiltration (1%)
- ✓ F. Persistent myelin debris (34%)
- G. Vasogenic edema (7%)

Omitted
Correct answer
F

34%
Answered correctly

02 secs
Time Spent

06/30/2020
Last Updated

Explanation

Wallerian degeneration in CNS

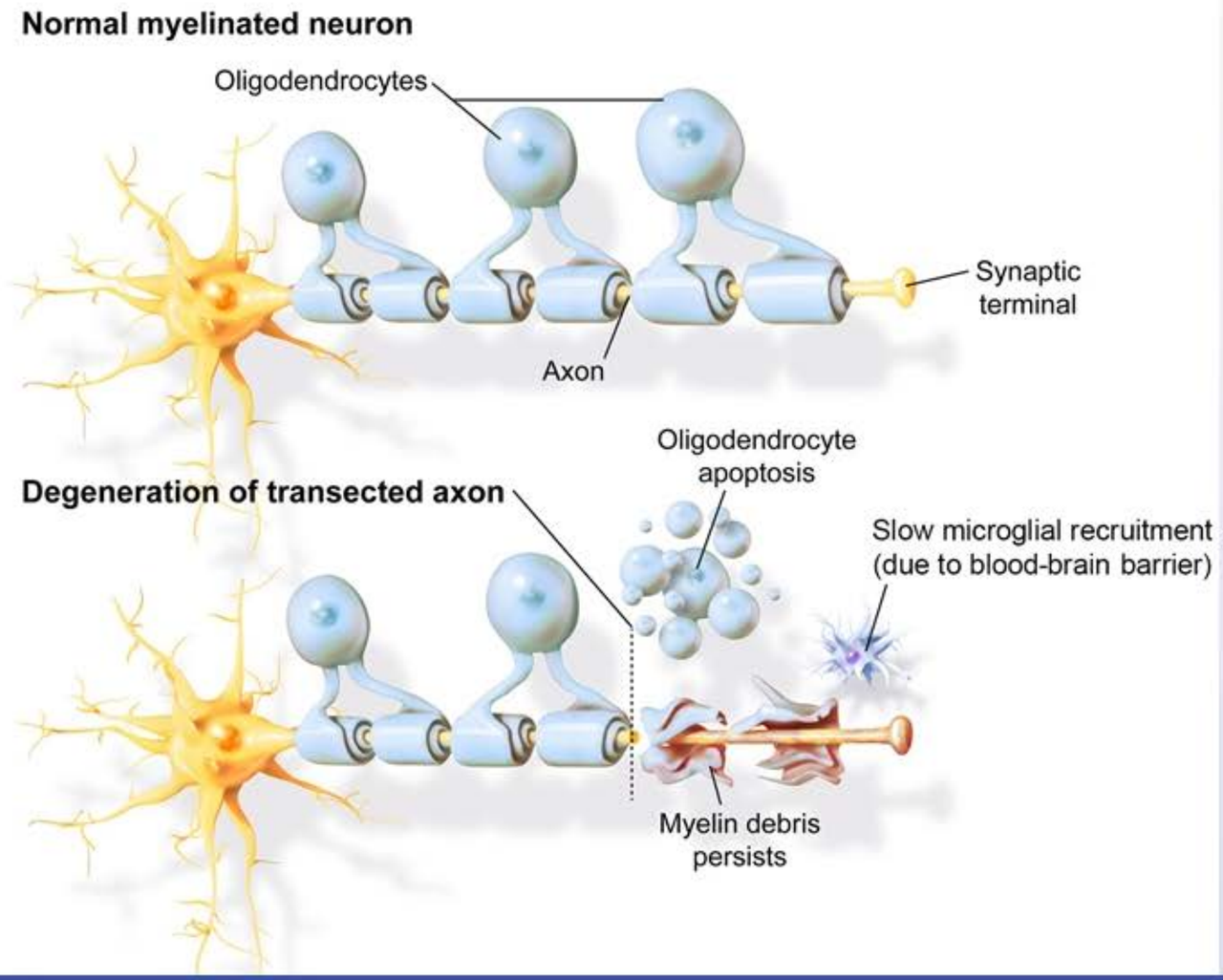

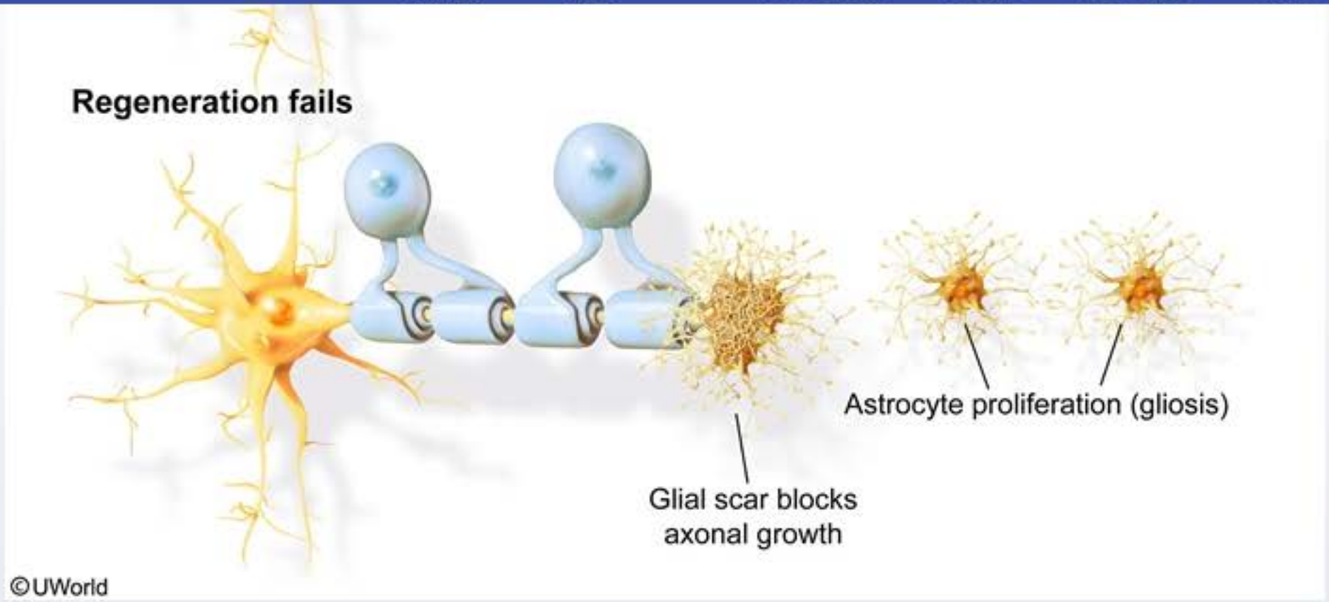

Wallerian degeneration refers to the process that occurs when an axon is damaged, resulting in axonal degeneration and breakdown of the myelin sheath **distal to the site of injury**. Degeneration of the axon usually begins within a few days after lesion onset.

In the peripheral nervous system, Schwann cells sense the axonal degeneration and begin to degrade their myelin and secrete cytokines and chemokines that recruit macrophages. This allows effective clearance of myelin debris which, along with trophic factor secretion by Schwann cells, stimulates formation of a growth cone from the stump of the proximal axon and facilitates nerve regeneration.

In the **central nervous system**, phagocytic macrophages/microglia are recruited more slowly because of the blood-brain barrier. Myelin-producing oligodendrocytes also become inactive or undergo apoptosis and do not assist with phagocytosis. This slows removal of the **myelin debris**, which can **persist for years** in the degenerating tracts and **suppress axonal growth** via myelin-associated inhibitory factors. Astrocytes also release inhibitory molecules and proliferate in the weeks to months following injury, forming a **glial scar** that acts as a **barrier** to axon regeneration.

(Choice A) Calcification of an ischemic infarction may occur months to years after the event; however, this is a rare occurrence. Brain

Wallerian degeneration refers to the process that occurs when an axon is damaged, resulting in axonal degeneration and breakdown of the myelin sheath **distal to the site of injury**. Degeneration of the axon usually begins within a few days after lesion onset.

In the peripheral nervous system, Schwann cells sense the axonal degeneration and begin to degrade their myelin and secrete cytokines and chemokines that recruit macrophages. This allows effective clearance of myelin debris which, along with trophic factor secretion by Schwann cells, stimulates formation of a growth cone from the stump of the proximal axon and facilitates nerve regeneration.

In the **central nervous system**, phagocytic macrophages/microglia are recruited more slowly because of the blood-brain barrier. Myelin-producing oligodendrocytes also become inactive or undergo apoptosis and do not assist with phagocytosis. This slows removal of the **myelin debris**, which can **persist for years** in the degenerating tracts and **suppress axonal growth** via myelin-associated inhibitory factors. Astrocytes also release inhibitory molecules and proliferate in the weeks to months following injury, forming a **glial scar** that acts as a **barrier** to axon regeneration.

(Choice A) Calcification of an ischemic infarction may occur months to years after the event; however, this is a rare occurrence. Brain calcification is most commonly seen with certain neoplasms (eg, oligodendroglioma), infections (eg, neurocysticercosis), and vascular malformations.

(Choices B and G) Cytotoxic and vasogenic edema typically occur in the acute setting after ischemic neuronal injury. Cytotoxic edema is a type of intracellular edema caused by impaired function of ATP-dependent sodium/potassium pumps on neuronal cell membranes. In contrast, vasogenic edema is a type of extracellular edema caused by increased vascular permeability due to the effects of pro-inflammatory cytokines.

(Choice C) In the first 12-24 hours after ischemic stroke, affected neurons classically shrink and develop intense cytoplasmic eosinophilia (red neurons) with pyknosis of the nucleus.

(Choice D) Embolic ischemic strokes have a high risk of undergoing acute hemorrhagic transformation within the first 7 days following the ischemic event.

(Choice E) Neutrophilic infiltration progressively increases up to 48 hours after ischemic stroke and then diminishes.

Educational objective:

Wallerian degeneration refers to the process of axonal degeneration and breakdown of the myelin sheath that occurs distal to a site of injury.

malformations.

(Choices B and G) Cytotoxic and vasogenic edema typically occur in the acute setting after ischemic neuronal injury. Cytotoxic edema is a type of intracellular edema caused by impaired function of ATP-dependent sodium/potassium pumps on neuronal cell membranes. In contrast, vasogenic edema is a type of extracellular edema caused by increased vascular permeability due to the effects of pro-inflammatory cytokines.

(Choice C) In the first 12-24 hours after ischemic stroke, affected neurons classically shrink and develop intense cytoplasmic eosinophilia (red neurons) with pyknosis of the nucleus.

(Choice D) Embolic ischemic strokes have a high risk of undergoing acute hemorrhagic transformation within the first 7 days following the ischemic event.

(Choice E) Neutrophilic infiltration progressively increases up to 48 hours after ischemic stroke and then diminishes.

Educational objective:
Wallerian degeneration refers to the process of axonal degeneration and breakdown of the myelin sheath that occurs distal to a site of injury. Axonal regeneration does not occur in the central nervous system due to the persistence of myelin debris, secretion of neuronal inhibitory factors, and development of dense glial scarring.

References

- Histopathological changes in acute ischemic stroke.
- Wallerian degeneration: gaining perspective on inflammatory events after peripheral nerve injury.
- Wallerian degeneration of the corticospinal tracts: postmortem MR-pathologic correlations.

Pathology	Nervous System	Ischemic stroke
Subject	System	Topic

Copyright © UWorld. All rights reserved.

A 31-year-old woman is brought to the hospital due to respiratory difficulty. She has had trouble performing her daily activities for the past few weeks due to fatigue. In particular, her arms seem to "just drop" when she combs her hair. The patient's symptoms are generally better in the morning and worsen throughout the day. She does not use tobacco, alcohol, or illicit drugs. Examination shows diplopia. Chest auscultation shows normal heart and breath sounds. Deep tendon reflexes are normal. Babinski sign is absent. The results of arterial blood gas analysis are as follows:

pH	7.32
pCO_2	60 mm Hg
pO_2	60 mm Hg

Which of the following is most likely abnormal in this patient?

A. Acetylcholine release from presynaptic neurons

B. Acetylcholinesterase activity

C. Calcium entry into presynaptic neurons

D. Number of acetylcholine receptors

E. Reuptake of acetylcholine

Submit

1 2 3 4 5 6 7 8 9 10 11 12 13 14 15 16 17 18 19 20 21 22 23 24 25 26 27 28 29 30

A 31-year-old woman is brought to the hospital due to respiratory difficulty. She has had trouble performing her daily activities for the past few weeks due to fatigue. In particular, her arms seem to "just drop" when she combs her hair. The patient's symptoms are generally better in the morning and worsen throughout the day. She does not use tobacco, alcohol, or illicit drugs. Examination shows diplopia. Chest auscultation shows normal heart and breath sounds. Deep tendon reflexes are normal. Babinski sign is absent. The results of arterial blood gas analysis are as follows:

pH	7.32
pCO_2	60 mm Hg
pO_2	60 mm Hg

Which of the following is most likely abnormal in this patient?

A. Acetylcholine release from presynaptic neurons (10%)

B. Acetylcholinesterase activity (4%)

C. Calcium entry into presynaptic neurons (6%)

✓ D. Number of acetylcholine receptors (76%)

E. Reuptake of acetylcholine (2%)

Omitted
Correct answer
D

76%
Answered correctly

01 sec
Time Spent

01/28/2020
Last Updated

1 2 3 4 5 6 7 8 9 10 11 12 13 14 15 16 17 18 19 20 21 22 23 24 25 26 27 28 29 30

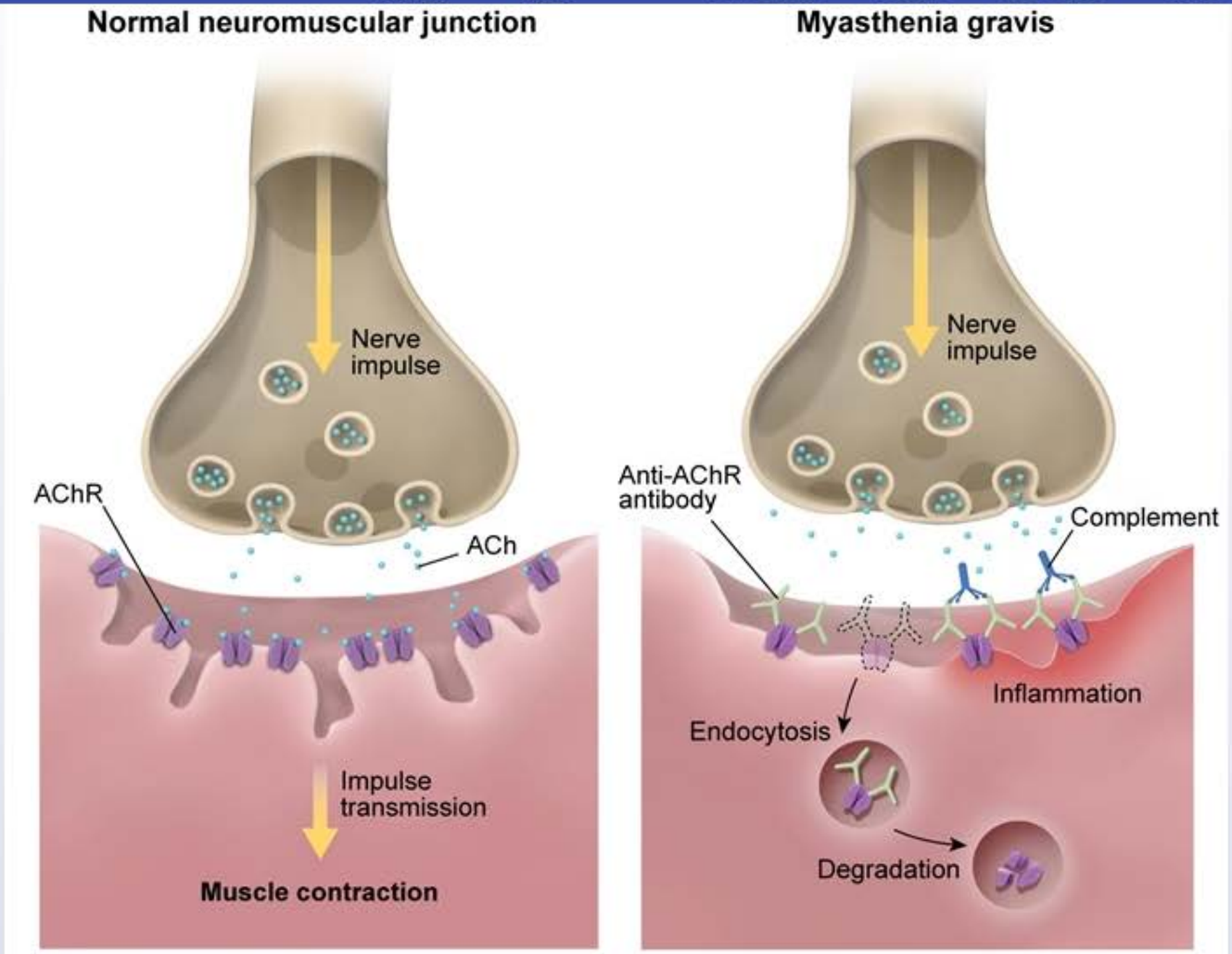

ACh = acetylcholine; **AChR** = acetylcholine receptor.
©UWorld

Myasthenia gravis (MG) is an acquired autoimmune disorder characterized by fatigable, fluctuating weakness of the skeletal muscles. The most

©UWorld

Myasthenia gravis (MG) is an acquired autoimmune disorder characterized by fatigable, fluctuating weakness of the skeletal muscles. The most commonly affected muscles include **ocular** (diplopia, ptosis), bulbar (dysarthria, fatigable chewing), facial (loss of smile), and proximal (**neck/shoulder weakness**) muscles. However as the disease progresses, **respiratory failure** (↓ pH, ↑ pCO_2, ↓ O_2) can occur due to diaphragmatic weakness and patients may require intubation.

MG is caused by an autoantibody-mediated, T cell–dependent attack on the **acetylcholine receptors** (AChRs) of the **postsynaptic** neuromuscular junction. Antibody-mediated blockade of the active site of AChRs prevents acetylcholine from binding and triggers endocytosis of AChRs (receptor internalization) and complement-mediated postsynaptic membrane damage. Over time, these changes result in **reduced numbers of AChRs** and impaired neuromuscular transmission.

(Choice A) Botulinum toxin irreversibly blocks acetylcholine release from presynaptic membranes of neuromuscular junctions. After exposure to the toxin, patients may develop cranial nerve abnormalities (including ptosis and facial weakness), symmetric descending weakness, and respiratory failure. However, autonomic abnormalities are common, and symptoms are rapidly progressive (hours rather than weeks) and do not worsen with repetition.

(Choices B and E) The action of acetylcholine at the postsynaptic membrane is terminated by acetylcholinesterase, not by acetylcholine reuptake. Organophosphates (eg, pesticides, sarin gas) irreversibly inactivate acetylcholinesterase, causing cholinergic toxicity (eg, increased glandular secretions, widespread smooth muscle activation). Muscle weakness, including respiratory failure, can occur due to depolarizing blockade at the neuromuscular junction; however, other symptoms (eg, diarrhea, urination, miosis, bradycardia, emesis, salivation) would be expected.

(Choice C) Lambert-Eaton myasthenic syndrome is due to autoantibodies directed against the voltage-gated calcium channels on presynaptic nerve terminals, leading to reduced calcium entry and impaired acetylcholine release. This syndrome commonly occurs in association with malignancy, particularly small cell lung cancer (which would be atypical in this young female), and generally causes proximal extremity weakness that is worse in the mornings and **improves** with repetition. Autonomic findings (eg, dry mouth, erectile dysfunction in males) are frequently seen and can be an important clue to diagnosis.

Educational objective:

Settings

1
2
3
4
5
6
7
8
9
10
11
12
13
14
15
16
17
18
19
20
21
22
23
24
25
26
27
28
29
30

Item 6 of 40
Question Id: 6554

Mark | Previous | Next | Full Screen | Tutorial | Lab Values | Notes | Calculator | Reverse Color | Text Zoom | Settings

©UWorld

Exhibit Display

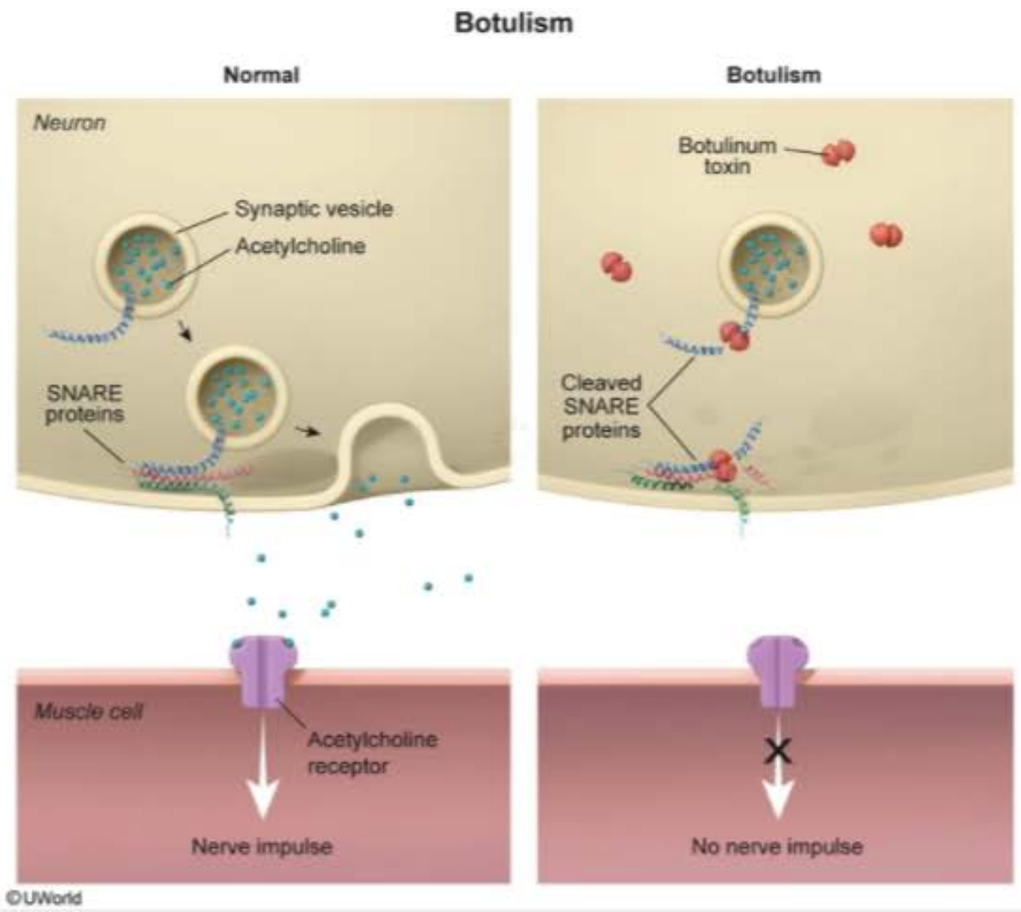

Zoom In | Zoom Out | Reset | Add To New Card | Existing Card

Educational objective:

Block Time Remaining: 00:00:14
TUTOR

3 | Feedback | Suspend | End Block

numbers of AChRs and impaired neuromuscular transmission.

(Choice A) Botulinum toxin irreversibly blocks acetylcholine release from presynaptic membranes of neuromuscular junctions. After exposure to the toxin, patients may develop cranial nerve abnormalities (including ptosis and facial weakness), symmetric descending weakness, and respiratory failure. However, autonomic abnormalities are common, and symptoms are rapidly progressive (hours rather than weeks) and do not worsen with repetition.

(Choices B and E) The action of acetylcholine at the postsynaptic membrane is terminated by acetylcholinesterase, not by acetylcholine reuptake. Organophosphates (eg, pesticides, sarin gas) irreversibly inactivate acetylcholinesterase, causing cholinergic toxicity (eg, increased glandular secretions, widespread smooth muscle activation). Muscle weakness, including respiratory failure, can occur due to depolarizing blockade at the neuromuscular junction; however, other symptoms (eg, diarrhea, urination, miosis, bradycardia, emesis, salivation) would be expected.

(Choice C) Lambert-Eaton myasthenic syndrome is due to autoantibodies directed against the voltage-gated calcium channels on presynaptic nerve terminals, leading to reduced calcium entry and impaired acetylcholine release. This syndrome commonly occurs in association with malignancy, particularly small cell lung cancer (which would be atypical in this young female), and generally causes proximal extremity weakness that is worse in the mornings and **improves** with repetition. Autonomic findings (eg, dry mouth, erectile dysfunction in males) are frequently seen and can be an important clue to diagnosis.

Educational objective:
Myasthenia gravis is an autoimmune disorder caused by an autoantibody-mediated attack on the acetylcholine receptors of the postsynaptic neuromuscular junction, leading to a reduced number of acetylcholine receptors. It is characterized by fatigable weakness of the skeletal muscles; respiratory failure can occur due to diaphragmatic weakness.

Pathology	Nervous System	Myasthenia gravis
Subject	System	Topic

Copyright © UWorld. All rights reserved.

Settings

1 2 3 4 5 6 7 8 9 10 11 12 13 14 15 16 17 18 19 20 21 22 23 24 25 26 27 28 29 30

Item 7 of 40
Question Id: 595

Mark | Previous | Next | Full Screen | Tutorial | Lab Values | Notes | Calculator | Reverse Color | Text Zoom | Settings

A 66-year-old man comes to the emergency department due to dizziness, dysarthria, and bilateral limb ataxia. His symptoms have been steadily worsening over the last 2 weeks. He has no other medical problems and takes no medications. He has a 50-pack-year smoking history and does not use alcohol or illicit drugs. Chest x-ray shows a mass in his right lung. He is admitted to the hospital for evaluation, but his neurologic symptoms continue to progress. He dies several months later despite receiving appropriate treatment. Autopsy shows extensive cerebellar Purkinje cell degeneration. Which of the following best describes the etiology of this patient's neurologic condition?

- A. Autoimmune
- B. Endocrine
- C. Infectious
- D. Metastatic
- E. Toxic
- F. Vascular

Submit

Block Time Remaining: 00:00:14
TUTOR

3 | Feedback | Suspend | End Block

A 66-year-old man comes to the emergency department due to dizziness, dysarthria, and bilateral limb ataxia. His symptoms have been steadily worsening over the last 2 weeks. He has no other medical problems and takes no medications. He has a 50-pack-year smoking history and does not use alcohol or illicit drugs. Chest x-ray shows a mass in his right lung. He is admitted to the hospital for evaluation, but his neurologic symptoms continue to progress. He dies several months later despite receiving appropriate treatment. Autopsy shows extensive cerebellar Purkinje cell degeneration. Which of the following best describes the etiology of this patient's neurologic condition?

- ✓ A. Autoimmune (20%)
- B. Endocrine (7%)
- C. Infectious (6%)
- D. Metastatic (39%)
- E. Toxic (3%)
- F. Vascular (22%)

Omitted
Correct answer
A

20%
Answered correctly

01 sec
Time Spent

07/05/2020
Last Updated

Explanation

Features of common paraneoplastic syndromes

Features of common paraneoplastic syndromes		
Clinical presentation	**Frequently associated neoplasms**	**Etiology**
Cushing syndrome	• Small cell lung cancer • Pancreatic cancer	Ectopic production of adrenocorticotropic hormone/ corticotropin-releasing hormone
Syndrome of inappropriate antidiuretic hormone secretion	• Small cell lung cancer	Ectopic vasopressin production
Subacute cerebellar degeneration	• Small cell lung cancer • Breast, ovarian & uterine cancer	Anti-Yo, anti-P/Q & anti-Hu antibodies
Lambert–Eaton myasthenic syndrome	• Small cell lung cancer	Voltage-gated calcium channel antibodies
Myasthenia gravis	• Thymoma	Acetylcholine receptor antibodies
Hypercalcemia	• Squamous cell lung cancer	Ectopic production of parathyroid hormone-related

	• Pancreatic cancer	corticotropin-releasing hormone
Syndrome of inappropriate antidiuretic hormone secretion	• Small cell lung cancer	Ectopic vasopressin production
Subacute cerebellar degeneration	• Small cell lung cancer • Breast, ovarian & uterine cancer	Anti-Yo, anti-P/Q & anti-Hu antibodies
Lambert–Eaton myasthenic syndrome	• Small cell lung cancer	Voltage-gated calcium channel antibodies
Myasthenia gravis	• Thymoma	Acetylcholine receptor antibodies
Hypercalcemia	• Squamous cell lung cancer	Ectopic production of parathyroid hormone-related protein
Dermatomyositis /polymyositis	• Variable	Autoimmune
Erythrocytosis	• Renal cell cancer	Ectopic erythropoietin production

©USMLEWorld, LLC

This patient's lung mass, cerebellar symptoms, and autopsy findings are consistent with **paraneoplastic cerebellar degeneration**. This paraneoplastic syndrome is most commonly associated with small cell lung cancer as well as breast, ovarian, and uterine malignancies. Patients exhibit **progressively worsening dizziness, limb and truncal ataxia, dysarthria, and visual disturbances** (eg, diplopia, oscillopsia). Paraneoplastic cerebellar degeneration is due to an immune response against tumor cells that **cross-reacts with Purkinje neuron antigens**, leading to acute-onset rapid degeneration of the cerebellum. **Anti-Yo, anti-P/Q, and anti-Hu** are the most common antibodies detected in the serum. Antibodies are not always detectable; thus, paraneoplastic cerebellar degeneration is diagnosed clinically after excluding other conditions.

(Choice B) Some paraneoplastic syndromes occur due to the production of hormone-like substances from tumor cells, but these would not cause the neurological findings described in this case.

(Choice C) Acute cerebellitis (post-viral cerebellar ataxia) occurs most often in children 2-3 weeks following varicella, measles, or Epstein-Barr virus infection. It presents with cerebellar symptoms (eg, ataxia, nystagmus, dysarthria) that usually resolve completely within 3 weeks.

(Choice D) Cerebellar metastasis can cause progressively worsening subacute cerebellar symptoms. Additional findings such as headaches or decreased consciousness are often present due to significant mass effect from the tumor. However, autopsy would show metastatic cancer cells with surrounding inflammation as opposed to Purkinje cell degeneration.

(Choice E) Adverse effects from systemic chemotherapy can include a wide range of neurologic complications. However, this patient's symptoms began before the lung mass was identified and his autopsy findings are more specific for subacute cerebellar degeneration.

(Choice F) Cerebellar infarction presents with vertigo, nystagmus, ipsilateral limb ataxia, and truncal lateropulsion (falling toward the lesion). Although repeated vascular events could result in a stepwise progressive loss in neurologic function, this process would most likely occur over several years and affect multiple vascular territories throughout the brain (causing a wide range of neurologic deficits). Autopsy would show areas of liquefactive necrosis (acute infarcts) and glial scarring (chronic infarcts).

Educational objective:
Paraneoplastic syndromes can occur due to the production of hormone-like substances from tumor cells. They can also result from immune reactions against tumor cells that cross-react with normal cells, causing dysfunction and/or damage to healthy organs and tissues. Neurologic

the neurological findings described in this case.

(Choice C) Acute cerebellitis (post-viral cerebellar ataxia) occurs most often in children 2-3 weeks following varicella, measles, or Epstein-Barr virus infection. It presents with cerebellar symptoms (eg, ataxia, nystagmus, dysarthria) that usually resolve completely within 3 weeks.

(Choice D) Cerebellar metastasis can cause progressively worsening subacute cerebellar symptoms. Additional findings such as headaches or decreased consciousness are often present due to significant mass effect from the tumor. However, autopsy would show metastatic cancer cells with surrounding inflammation as opposed to Purkinje cell degeneration.

(Choice E) Adverse effects from systemic chemotherapy can include a wide range of neurologic complications. However, this patient's symptoms began before the lung mass was identified and his autopsy findings are more specific for subacute cerebellar degeneration.

(Choice F) Cerebellar infarction presents with vertigo, nystagmus, ipsilateral limb ataxia, and truncal lateropulsion (falling toward the lesion). Although repeated vascular events could result in a stepwise progressive loss in neurologic function, this process would most likely occur over several years and affect multiple vascular territories throughout the brain (causing a wide range of neurologic deficits). Autopsy would show areas of liquefactive necrosis (acute infarcts) and glial scarring (chronic infarcts).

Educational objective:
Paraneoplastic syndromes can occur due to the production of hormone-like substances from tumor cells. They can also result from immune reactions against tumor cells that cross-react with normal cells, causing dysfunction and/or damage to healthy organs and tissues. Neurologic paraneoplastic syndromes (eg, paraneoplastic cerebellar degeneration) are an autoimmune phenomenon.

References

- Small-cell lung cancer, paraneoplastic cerebellar degeneration and the Lambert-Eaton myasthenic syndrome

Pathology	Nervous System	Cerebellar degeneration
Subject	System	Topic

Copyright © UWorld. All rights reserved.

Settings

1 2 3 4 5 6 7 8 9 10 11 12 13 14 15 16 17 18 19 20 21 22 23 24 25 26 27 28 29 30

Item 8 of 40
Question Id: 910

Mark | Previous | Next | Full Screen | Tutorial | Lab Values | Notes | Calculator | Reverse Color | Text Zoom | Settings

A 10-year-old boy whose family recently immigrated to the United States is brought to the physician with ataxia, myoclonus, and visual problems. His parents say that he began acting strangely and having difficulty with school work several months ago. After the appropriate workup, a brain biopsy is obtained and an RNA virus containing hemagglutinin is cultured from the tissue sample. Which of the following is the most likely diagnosis?

A. Creutzfeldt-Jakob disease
B. Guillain-Barré syndrome
C. Multiple sclerosis
D. Progressive multifocal leukoencephalopathy
E. Progressive supranuclear palsy
F. Subacute sclerosing panencephalitis

Submit

Block Time Remaining: 00:00:15
TUTOR

3 | Feedback | Suspend | End Block

A 10-year-old boy whose family recently immigrated to the United States is brought to the physician with ataxia, myoclonus, and visual problems. His parents say that he began acting strangely and having difficulty with school work several months ago. After the appropriate workup, a brain biopsy is obtained and an RNA virus containing hemagglutinin is cultured from the tissue sample. Which of the following is the most likely diagnosis?

A. Creutzfeldt-Jakob disease (6%)

B. Guillain-Barré syndrome (4%)

C. Multiple sclerosis (1%)

D. Progressive multifocal leukoencephalopathy (21%)

E. Progressive supranuclear palsy (3%)

✓ F. Subacute sclerosing panencephalitis (63%)

Omitted
Correct answer
F

63%
Answered correctly

01 sec
Time Spent

04/04/2020
Last Updated

Explanation

Measles virus (rubeola)	

1 2 3 4 5 6 7 8 9 10 11 12 13 14 15 16 17 18 19 20 21 22 23 24 25 26 27 28 29 30

Measles virus (rubeola)	
Clinical presentation	• Prodrome (eg, cough, coryza, conjunctivitis, fever, Koplik spots) • Maculopapular exanthem ○ Cephalocaudal & centrifugal spread ○ Spares palms/soles
Complications	• Primary measles pneumonia • Secondary bacterial infections (pneumonia & otitis media) • Neurologic ○ Encephalitis (within days) ○ Acute disseminated encephalomyelitis (within weeks) ○ Subacute sclerosing panencephalitis (within years)
Prevention	• Live attenuated measles vaccine

©UWorld

Measles virus is an enveloped, single-stranded RNA virus that is a member of the paramyxovirus family. Its genome codes for several viral structural proteins, including membrane-bound **hemagglutinin** (mediates cell surface adhesion) and **matrix protein** (important for viral assembly).

Subacute sclerosing panencephalitis (SSPE) is a rare complication of measles that occurs in children or young adults several years after the initial infection. It is thought to be caused by a form of measles virus with a mutated or **absent matrix protein** that prevents mature (enveloped) virion particles from forming. However, the virus continues to replicate intracellularly, leading to a persistent, nonproductive infection that evades eradication by the immune system. **Accumulation of viral nucleocapsids** within neurons and oligodendrocytes results in the formation of intranuclear inclusions and eventually leads to inflammation, demyelination, and gliosis in many cerebral areas.

Patients with SSPE have high titers of **measles antibodies** in the serum and cerebrospinal fluid (detectable as oligoclonal bands). The disease

Measles virus is an enveloped, single-stranded RNA virus that is a member of the paramyxovirus family. Its genome codes for several viral structural proteins, including membrane-bound **hemagglutinin** (mediates cell surface adhesion) and **matrix protein** (important for viral assembly).

Subacute sclerosing panencephalitis (SSPE) is a rare complication of measles that occurs in children or young adults several years after the initial infection. It is thought to be caused by a form of measles virus with a mutated or **absent matrix protein** that prevents mature (enveloped) virion particles from forming. However, the virus continues to replicate intracellularly, leading to a persistent, nonproductive infection that evades eradication by the immune system. **Accumulation of viral nucleocapsids** within neurons and oligodendrocytes results in the formation of intranuclear inclusions and eventually leads to inflammation, demyelination, and gliosis in many cerebral areas.

Patients with SSPE have high titers of **measles antibodies** in the serum and cerebrospinal fluid (detectable as oligoclonal bands). The disease causes various neurologic deficits and dementia, and is relentlessly progressive and fatal.

(Choice A) Creutzfeldt-Jakob disease is a rare form of rapidly progressive dementia that is caused by prions (abnormally folded proteins). It usually occurs in older patients (sporadic form), although younger patients can be affected after consuming prion-infected meat products (acquired or variant form). Brain biopsy will show spongiform transformation of the cerebral cortex.

(Choice B) Guillain-Barré syndrome is a postinfectious autoimmune demyelinating disorder of the peripheral nervous system. It most commonly presents as a symmetrical ascending weakness with absent reflexes following an infectious respiratory or diarrheal illness.

(Choice C) Multiple sclerosis usually manifests in patients 20-30 years old. It is characterized by a variety of visual (eg, optic neuritis, internuclear ophthalmoplegia) and sensory deficits occurring in a relapsing/remitting pattern. Brain biopsy will show focal demyelinated plaques with relative axonal sparing.

(Choice D) Progressive multifocal leukoencephalopathy is an infectious demyelinating disorder caused by JC virus, a double-stranded DNA virus in the polyomavirus family. JC virus manifests with progressive neurologic deficits in immunocompromised individuals (eg, lymphoma, leukemia, or HIV infection).

(Choice E) Progressive supranuclear palsy is a form of parkinsonism resulting from neurodegeneration of the midbrain and frontal subcortical white matter. It presents with rapidly progressive gait dysfunction and falls, executive function loss, and vertical gaze palsy. Brain biopsy usually shows deposits of abnormally phosphorylated tau proteins.

intranuclear inclusions and eventually leads to inflammation, demyelination, and gliosis in many cerebral areas.

Patients with SSPE have high titers of **measles antibodies** in the serum and cerebrospinal fluid (detectable as oligoclonal bands). The disease causes various neurologic deficits and dementia, and is relentlessly progressive and fatal.

(Choice A) Creutzfeldt-Jakob disease is a rare form of rapidly progressive dementia that is caused by prions (abnormally folded proteins). It usually occurs in older patients (sporadic form), although younger patients can be affected after consuming prion-infected meat products (acquired or variant form). Brain biopsy will show spongiform transformation of the cerebral cortex.

(Choice B) Guillain-Barré syndrome is a postinfectious autoimmune demyelinating disorder of the peripheral nervous system. It most commonly presents as a symmetrical ascending weakness with absent reflexes following an infectious respiratory or diarrheal illness.

(Choice C) Multiple sclerosis usually manifests in patients 20-30 years old. It is characterized by a variety of visual (eg, optic neuritis, internuclear ophthalmoplegia) and sensory deficits occurring in a relapsing/remitting pattern. Brain biopsy will show focal demyelinated plaques with relative axonal sparing.

(Choice D) Progressive multifocal leukoencephalopathy is an infectious demyelinating disorder caused by JC virus, a double-stranded DNA virus in the polyomavirus family. JC virus manifests with progressive neurologic deficits in immunocompromised individuals (eg, lymphoma, leukemia, or HIV infection).

(Choice E) Progressive supranuclear palsy is a form of parkinsonism resulting from neurodegeneration of the midbrain and frontal subcortical white matter. It presents with rapidly progressive gait dysfunction and falls, executive function loss, and vertical gaze palsy. Brain biopsy usually shows deposits of abnormally phosphorylated tau proteins.

Educational objective:
Subacute sclerosing panencephalitis is a rare complication of measles infection that occurs several years after apparent recovery from initial infection. Oligoclonal bands of measles virus antibodies are found in the cerebrospinal fluid of these patients.

References

- Subacute sclerosing panencephalitis: clinical and demographic characteristics.
- Evidence that the hypermutated M protein of a subacute sclerosing panencephalitis measles virus actively contributes to the chronic

Settings

1 2 3 4 5 6 7 8 9 10 11 12 13 14 15 16 17 18 19 20 21 22 23 24 25 26 27 28 29 30

Item 9 of 40
Question Id: 880

Mark | Previous | Next | Full Screen | Tutorial | Lab Values | Notes | Calculator | Reverse Color | Text Zoom | Settings

A 31-year-old female with new-onset generalized tonic-clonic seizures has an intracranial mass detected on head CT scan. Biopsy of the mass reveals neoplastic cells that stain positive for synaptophysin and negative for glial fibrillary acidic protein. These neoplastic cells most likely originate from the same precursor tissue as which of the following?

A. Astrocytes
B. Oligodendroglia
C. Ependymal cells
D. Meningothelial cells
E. Neurons

Submit

Block Time Remaining: 00:00:16
TUTOR

2 | Feedback | Suspend | End Block

1 2 3 4 5 6 7 8 9 10 11 12 13 14 15 16 17 18 19 20 21 22 23 24 25 26 27 28 29 30

A 31-year-old female with new-onset generalized tonic-clonic seizures has an intracranial mass detected on head CT scan. Biopsy of the mass reveals neoplastic cells that stain positive for synaptophysin and negative for glial fibrillary acidic protein. These neoplastic cells most likely originate from the same precursor tissue as which of the following?

A. Astrocytes (12%)

B. Oligodendroglia (17%)

C. Ependymal cells (11%)

D. Meningothelial cells (16%)

✓ E. Neurons (42%)

Omitted
Correct answer
E

42%
Answered correctly

01 sec
Time Spent

02/03/2020
Last Updated

Explanation

Synaptophysin is a transmembrane glycoprotein found in the presynaptic vesicles of neurons, neuroectodermal and neuroendocrine cells. Immunoreactivity of a CNS tumor for synaptophysin indicates a neuronal origin (Choice E). Such neoplasms are rare and compose less than 1% of CNS tumors. The majority of primary CNS tumors in adults are of glial origin, meningiomas and pituitary adenomas are the next most common. Primary tumors in adults tend to be supratentorial while those in children tend to lie below the tentorium. Metastatic disease to the CNS occurs more commonly than primary CNS tumors.

Explanation

Synaptophysin is a transmembrane glycoprotein found in the presynaptic vesicles of neurons, neuroectodermal and neuroendocrine cells. Immunoreactivity of a CNS tumor for synaptophysin indicates a neuronal origin (Choice E). Such neoplasms are rare and compose less than 1% of CNS tumors. The majority of primary CNS tumors in adults are of glial origin, meningiomas and pituitary adenomas are the next most common. Primary tumors in adults tend to be supratentorial while those in children tend to lie below the tentorium. Metastatic disease to the CNS occurs more commonly than primary CNS tumors.

Unlike tumors of neuronal origin, gliomas stain positively for glial fibrillary acidic protein (GFAP). Immunoreactivity for GFAP is characteristic for astrocytomas including glioblastoma multiforme, oligodendrogliomas, ependymomas and peripheral neural sheath tumors.

(Choices A, B and C) Astrocytes, oligodendrocytes, and ependymal cells give rise to tumors collectively referred to as gliomas (astrocytomas, oligodendrogliomas and ependymomas, respectively). Cells from tumors of glial origin stain positively for glial fibrillary acidic protein (GFAP).

(Choice D) Cells of the arachnoid villi give rise to meningiomas, most of which are benign. These tumors are diagnosed by imaging; they do not stain for GFAP or synaptophysin.

Educational Objective:
Synaptophysin is a protein found in the presynaptic vesicles of neurons, neuroendocrine and neuroectodermal cells. CNS tumors of neuronal origin frequently stain positively for synaptophysin on immunohistology. Neoplasms of glial origin (astrocytomas, ependymomas, and oligodendrogliomas) stain for GFAP.

Pathology	Nervous System	Brain tumors
Subject	System	Topic

Copyright © UWorld. All rights reserved.

Settings

1 2 3 4 5 6 7 8 9 10 11 12 13 14 15 16 17 18 19 20 21 22 23 24 25 26 27 28 29 30

Item 10 of 40
Question Id: 1153

Mark | Previous | Next | Full Screen | Tutorial | Lab Values | Notes | Calculator | Reverse Color | Text Zoom | Settings

A 14-year-old boy presents with nausea, vomiting, generalized headache, ataxia, and visual complaints. The headaches have awoken him nightly for the past six weeks. MRI reveals a cystic tumor in the cerebellum. Biopsy of the tumor reveals a well-differentiated neoplasm comprised of spindle cells that have hair-like glial processes and are associated with microcysts. These cells are mixed with Rosenthal fibers and granular eosinophilic bodies. Based on these findings, the most likely diagnosis is which of the following?

A. Pilocytic Astrocytoma

B. Glioblastoma multiforme

C. Medulloblastoma

D. Ependymoma

E. Neuroblastoma

Submit

Block Time Remaining: 00:00:17
TUTOR

2 | Feedback | Suspend | End Block

A 14-year-old boy presents with nausea, vomiting, generalized headache, ataxia, and visual complaints. The headaches have awoken him nightly for the past six weeks. MRI reveals a cystic tumor in the cerebellum. Biopsy of the tumor reveals a well-differentiated neoplasm comprised of spindle cells that have hair-like glial processes and are associated with microcysts. These cells are mixed with Rosenthal fibers and granular eosinophilic bodies. Based on these findings, the most likely diagnosis is which of the following?

- ✓ A. Pilocytic Astrocytoma (71%)
- B. Glioblastoma multiforme (6%)
- C. Medulloblastoma (14%)
- D. Ependymoma (5%)
- E. Neuroblastoma (2%)

Omitted
Correct answer
A

71%
Answered correctly

01 sec
Time Spent

02/03/2020
Last Updated

Explanation

Juvenile pilocytic astrocytomas usually arise in the cerebellum, brainstem, hypothalamic region, or optic pathways. Microscopically, pilocytic astrocytomas are well-differentiated neoplasms comprised of spindle cells with hair-like glial processes that are associated with microcysts. These cells are mixed with Rosenthal fibers and granular eosinophilic bodies.

(Choice B) GBMs occur most often in the subcortical white matter of the cerebral hemispheres. When a tumor in the frontal cortex spreads

Juvenile pilocytic astrocytomas usually arise in the cerebellum, brainstem, hypothalamic region, or optic pathways. Microscopically, pilocytic astrocytomas are well-differentiated neoplasms comprised of spindle cells with hair-like glial processes that are associated with microcysts. These cells are mixed with Rosenthal fibers and granular eosinophilic bodies.

(Choice B) GBMs occur most often in the subcortical white matter of the cerebral hemispheres. When a tumor in the frontal cortex spreads across the corpus callosum into the contralateral hemisphere, it creates the appearance of a bilateral symmetrical lesion, hence the term "butterfly glioma." GBMs are composed of poorly-differentiated, often-pleomorphic astrocytic cells with marked nuclear atypia and brisk mitotic activity. Necrosis is an essential diagnostic feature, and prominent microvascular proliferation is common.

(Choice C) Medulloblastoma (primitive neuroectodermal tumor, or PNET) is the second most common posterior fossa tumor in children. On microscopic examination, cells are small and poorly differentiated, with scant cytoplasm and little stroma. A high mitotic index is common. Classic Homer-Wright rosettes can be seen in one fifth of cases.

(Choice D) Ependymomas account for 10% of posterior fossa tumors in children. Intracranial lesions usually occur infratentorially, arising from the roof of the fourth ventricle in children, while spinal ependymomas typically occur in adults. Histologically, ependymal pseudorosettes with glial fibrillary acidic protein (GFAP)–positive processes tapering toward blood vessels characterize ependymomas.

(Choice E) Neuroblastomas are the most common extracranial solid tumors occurring in children. Undifferentiated neuroblastomas are small, round, blue-cell tumors. A neuritic process, also called neuropil, is a pathognomonic feature of neuroblastoma cells. NSE, chromogranin, synaptophysin, and S-100 immunohistochemical stains are usually positive. More than 90% of patients have elevated urinary levels of homovanillic acid (HVA) and/or vanillylmandelic acid (VMA). The most important biologic marker is *MYCN (N-MYC)* of chromosome 2.

Educational Objective:
A cystic tumor in the cerebellum of a child is most likely a pilocytic astrocytoma. Biopsy will show a well-differentiated neoplasm comprised of spindle cells with hair-like glial processes that are associated with microcysts. These cells are mixed with Rosenthal fibers and granular eosinophilic bodies.

Pathology Nervous System Brain tumors

cells are mixed with Rosenthal fibers and granular eosinophilic bodies.

(Choice B) GBMs occur most often in the subcortical white matter of the cerebral hemispheres. When a tumor in the frontal cortex spreads across the corpus callosum into the contralateral hemisphere, it creates the appearance of a bilateral symmetrical lesion, hence the term "butterfly glioma." GBMs are composed of poorly-differentiated, often-pleomorphic astrocytic cells with marked nuclear atypia and brisk mitotic activity. Necrosis is an essential diagnostic feature, and prominent microvascular proliferation is common.

(Choice C) Medulloblastoma (primitive neuroectodermal tumor, or PNET) is the second most common posterior fossa tumor in children. On microscopic examination, cells are small and poorly differentiated, with scant cytoplasm and little stroma. A high mitotic index is common. Classic Homer-Wright rosettes can be seen in one fifth of cases.

(Choice D) Ependymomas account for 10% of posterior fossa tumors in children. Intracranial lesions usually occur infratentorially, arising from the roof of the fourth ventricle in children, while spinal ependymomas typically occur in adults. Histologically, ependymal pseudorosettes with glial fibrillary acidic protein (GFAP)–positive processes tapering toward blood vessels characterize ependymomas.

(Choice E) Neuroblastomas are the most common extracranial solid tumors occurring in children. Undifferentiated neuroblastomas are small, round, blue-cell tumors. A neuritic process, also called neuropil, is a pathognomonic feature of neuroblastoma cells. NSE, chromogranin, synaptophysin, and S-100 immunohistochemical stains are usually positive. More than 90% of patients have elevated urinary levels of homovanillic acid (HVA) and/or vanillylmandelic acid (VMA). The most important biologic marker is *MYCN (N-MYC)* of chromosome 2.

Educational Objective:
A cystic tumor in the cerebellum of a child is most likely a pilocytic astrocytoma. Biopsy will show a well-differentiated neoplasm comprised of spindle cells with hair-like glial processes that are associated with microcysts. These cells are mixed with Rosenthal fibers and granular eosinophilic bodies.

Pathology	Nervous System	Brain tumors
Subject	System	Topic

Copyright © UWorld. All rights reserved.

Settings

1 2 3 4 5 6 7 8 9 10 11 12 13 14 15 16 17 18 19 20 21 22 23 24 25 26 27 28 29 30

Item 11 of 40
Question Id: 15683

Mark | Previous | Next | Full Screen | Tutorial | Lab Values | Notes | Calculator | Reverse Color | Text Zoom | Settings

A 22-year-old woman comes to the emergency department due to acute vision disturbances and headache. About an hour ago the patient experienced a small area of visual loss, which she describes as a hole in the visual field. The vision disturbance gradually expanded to a C-shape in her peripheral vision and spontaneously resolved after 15-20 minutes. A progressively worsening, severe, right-sided headache of pulsating quality quickly followed. The patient has had similar headaches in the past but not of such severity. She has no other medical conditions and takes no medications. Blood pressure is 150/86 mm Hg and pulse is 92/min. On physical examination, the patient is lying still in bed with eyes closed. The pupils are equal and reactive to light. Funduscopic examination reveals no abnormalities. Bilateral upper and lower extremity muscle strength, deep tendon reflexes, and sensation are normal. Which of the following is the most likely diagnosis?

- A. Acute angle-closure glaucoma
- B. Cluster headache
- C. Migraine with aura
- D. Optic neuritis
- E. Simple partial seizure
- F. Transient ischemic attack

Submit

Block Time Remaining: 00:00:18
TUTOR

2 | Feedback | Suspend | End Block

1 2 3 4 5 6 7 8 9 10 11 12 13 14 15 16 17 18 19 20 21 22 23 24 25 26 27 28 29 30

A 22-year-old woman comes to the emergency department due to acute vision disturbances and headache. About an hour ago the patient experienced a small area of visual loss, which she describes as a hole in the visual field. The vision disturbance gradually expanded to a C-shape in her peripheral vision and spontaneously resolved after 15-20 minutes. A progressively worsening, severe, right-sided headache of pulsating quality quickly followed. The patient has had similar headaches in the past but not of such severity. She has no other medical conditions and takes no medications. Blood pressure is 150/86 mm Hg and pulse is 92/min. On physical examination, the patient is lying still in bed with eyes closed. The pupils are equal and reactive to light. Funduscopic examination reveals no abnormalities. Bilateral upper and lower extremity muscle strength, deep tendon reflexes, and sensation are normal. Which of the following is the most likely diagnosis?

- A. Acute angle-closure glaucoma (3%)
- B. Cluster headache (6%)
- ✓ C. Migraine with aura (73%)
- D. Optic neuritis (6%)
- E. Simple partial seizure (0%)
- F. Transient ischemic attack (9%)

Omitted
Correct answer
C

73%
Answered correctly

02 secs
Time Spent

03/11/2020
Last Updated

Explanation

This young woman with a pulsating, unilateral headache preceded by visual field loss has **migraine with aura**. Migraines are an episodic neurological disorder that results in severe, **unilateral**, **throbbing headaches** often associated with photophobia, phonophobia, and nausea/vomiting. Migraines typically last 4-72 hours and have a strong genetic predisposition; **women** are affected more frequently than men.

Migraines are thought to be triggered by a self-propagating wave of depolarization spreading across neurons in the cerebral cortex, resulting in activation and sensitization of trigeminal nerve nociceptors. Up to 25% of patients also develop **focal**, **reversible neurologic symptoms** that precede or accompany the headache, known as an **aura**. Auras may be due to the spread of depolarization into other areas of the brain, where they are interpreted as "positive" (eg, bright spots, noises, paresthesia, movements) or "negative" (eg, vision/hearing/sensation loss) symptoms. Auras typically develop progressively over a period of minutes.

(Choice A) Acute angle-closure glaucoma causes headache and decreased vision associated with elevated intraocular pressures. However, patients are typically older (age >60), and severe eye pain and conjunctival erythema are common. Vision would not be expected to improve without intervention.

(Choice B) Cluster headache causes severe unilateral headaches; however, ipsilateral autonomic symptoms (eg, lacrimation, rhinorrhea, flushing, diaphoresis) are expected. The disease is also more common in men and is not associated with aura.

(Choice D) Optic neuritis is a demyelinating disorder that causes vision loss, but it is typically unilateral and progresses over a period of weeks. Patients have eye pain that is worse with movement, color vision is often affected, and an afferent pupillary defect is present.

(Choice E) Simple partial seizure may be preceded by an aura, but seizures typically cause positive symptoms (eg, lip smacking, arm movement, seeing bright lights) rather than the negative symptoms seen in this patient, and typically last <2 minutes. Unilateral headache is more suggestive of migraine with aura.

(Choice F) Transient ischemic attacks (TIAs) also cause focal neurologic deficits; however, these typically have an acute onset, with maximal symptoms at onset rather than the progressive visual field deficit seen in this patient. In addition, TIAs typically occur in older patients with vascular risk factors (eg, smoking, hyperlipidemia) and would be very uncommon in an otherwise healthy young woman.

Educational objective:
Migraines are an episodic neurological disorder that results in severe, unilateral, throbbing headaches often associated with photophobia,

Auras typically develop progressively over a period of minutes.

(Choice A) Acute angle-closure glaucoma causes headache and decreased vision associated with elevated intraocular pressures. However, patients are typically older (age >60), and severe eye pain and conjunctival erythema are common. Vision would not be expected to improve without intervention.

(Choice B) Cluster headache causes severe unilateral headaches; however, ipsilateral autonomic symptoms (eg, lacrimation, rhinorrhea, flushing, diaphoresis) are expected. The disease is also more common in men and is not associated with aura.

(Choice D) Optic neuritis is a demyelinating disorder that causes vision loss, but it is typically unilateral and progresses over a period of weeks. Patients have eye pain that is worse with movement, color vision is often affected, and an afferent pupillary defect is present.

(Choice E) Simple partial seizure may be preceded by an aura, but seizures typically cause positive symptoms (eg, lip smacking, arm movement, seeing bright lights) rather than the negative symptoms seen in this patient, and typically last <2 minutes. Unilateral headache is more suggestive of migraine with aura.

(Choice F) Transient ischemic attacks (TIAs) also cause focal neurologic deficits; however, these typically have an acute onset, with maximal symptoms at onset rather than the progressive visual field deficit seen in this patient. In addition, TIAs typically occur in older patients with vascular risk factors (eg, smoking, hyperlipidemia) and would be very uncommon in an otherwise healthy young woman.

Educational objective:
Migraines are an episodic neurological disorder that results in severe, unilateral, throbbing headaches often associated with photophobia, phonophobia, and nausea/vomiting. Migraines typically last 4-72 hours, and up to 25% of patients also develop an aura (focal, reversible neurologic symptoms that precede or accompany the headache).

Pathology	Nervous System	Migraine
Subject	System	Topic

Copyright © UWorld. All rights reserved.

Settings

1 2 3 4 5 6 7 8 9 10 11 12 13 14 15 16 17 18 19 20 21 22 23 24 25 26 27 28 29 30

Item 12 of 40
Question Id: 14

Mark | Previous | Next | Full Screen | Tutorial | Lab Values | Notes | Calculator | Reverse Color | Text Zoom | Settings

A 43-year-old man with a history of HIV infection who is noncompliant with highly active antiretroviral therapy comes to the office due to progressive memory loss and cognitive decline over the last several years. The patient has problems with attention, concentration, and speech. In the past few months, he has become more apathetic and increasingly lethargic. More recently, he has had difficulty with balance and has fallen on multiple occasions. The patient has had no headache, tremor, change in vision, fever, nausea/vomiting, or urinary incontinence. His brother has a history of severe intellectual disability and epilepsy. Mini-Mental State Examination score is 18/30, and the patient appears emotionally blunted. He also has postural instability and difficulty performing fine motor tasks. Noncontrast head CT scan reveals diffuse cortical atrophy with some enlargement of the ventricles, as shown in the exhibits. This patient's condition can be best described as which of the following?

A. Communicating hydrocephalus
B. Hydrocephalus ex-vacuo
C. Lissencephaly
D. Noncommunicating hydrocephalus
E. Pseudotumor cerebri
F. Transtentorial (uncal) herniation

Submit

Block Time Remaining: 00:00:20
TUTOR

4 | Feedback | Suspend | End Block

Settings

1
2
3
4
5
6
7
8
9
10
11
12
13
14
15
16
17
18
19
20
21
22
23
24
25
26
27
28
29
30

Item 12 of 40
Question Id: 14

Mark | Previous | Next | Full Screen | Tutorial | Lab Values | Notes | Calculator | Reverse Color | Text Zoom | Settings

Exhibit Display

Exhibit 1 Exhibit 2

Zoom In | Zoom Out | Reset | Add To New Card | Existing Card

Block Time Remaining: 00:00:23
TUTOR

4 | Feedback | Suspend | End Block

Settings

1
2
3
4
5
6
7
8
9
10
11
12
13
14
15
16
17
18
19
20
21
22
23
24
25
26
27
28
29
30

Item 12 of 40
Question Id: 14

Mark | Previous | Next | Full Screen | Tutorial | Lab Values | Notes | Calculator | Reverse Color | Text Zoom | Settings

Exhibit Display

Exhibit 1 Exhibit 2

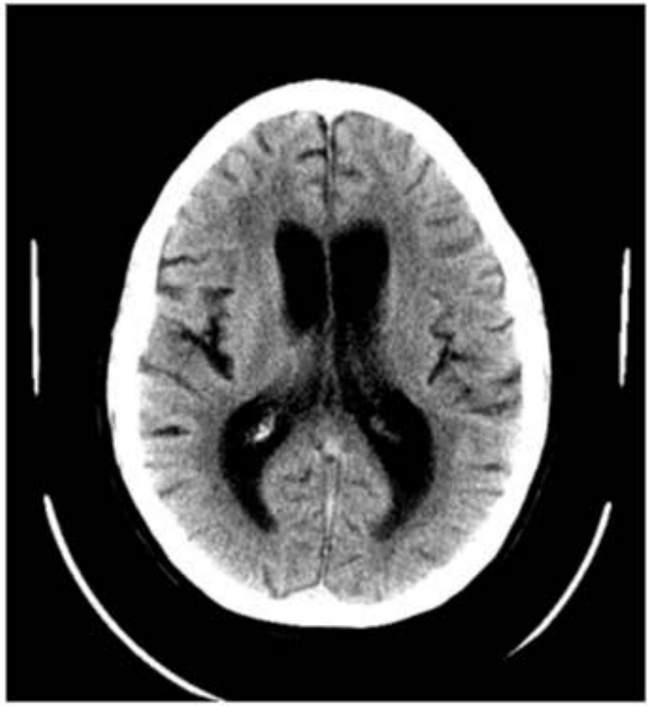

Zoom In | Zoom Out | Reset | Add To New Card | Existing Card

Block Time Remaining: 00:00:26
TUTOR

4 | Feedback | Suspend | End Block

1 2 3 4 5 6 7 8 9 10 11 12 13 14 15 16 17 18 19 20 21 22 23 24 25 26 27 28 29 30

A 43-year-old man with a history of HIV infection who is noncompliant with highly active antiretroviral therapy comes to the office due to progressive memory loss and cognitive decline over the last several years. The patient has problems with attention, concentration, and speech. In the past few months, he has become more apathetic and increasingly lethargic. More recently, he has had difficulty with balance and has fallen on multiple occasions. The patient has had no headache, tremor, change in vision, fever, nausea/vomiting, or urinary incontinence. His brother has a history of severe intellectual disability and epilepsy. Mini-Mental State Examination score is 18/30, and the patient appears emotionally blunted. He also has postural instability and difficulty performing fine motor tasks. Noncontrast head CT scan reveals diffuse cortical atrophy with some enlargement of the ventricles, as shown in the exhibits. This patient's condition can be best described as which of the following?

A. Communicating hydrocephalus (10%)
✓ B. Hydrocephalus ex-vacuo (75%)
C. Lissencephaly (3%)
D. Noncommunicating hydrocephalus (6%)
E. Pseudotumor cerebri (3%)
F. Transtentorial (uncal) herniation (1%)

Omitted
Correct answer
B

75%
Answered correctly

09 secs
Time Spent

04/02/2020
Last Updated

Explanation

Cerebrospinal fluid (CSF) circulates in the ventricular system and subarachnoid space and is constantly secreted by the choroid plexus and absorbed by granulations of the arachnoid mater. Hydrocephalus is defined as enlargement of the ventricles (with or without elevated pressure) caused by either central neuronal volume loss (eg, **hydrocephalus ex-vacuo**) or excessive CSF accumulation. Patients with neurodegenerative diseases (eg, **AIDS dementia**) can develop hydrocephalus ex-vacuo due to significant **cortical atrophy**, which allows the ventricles to expand while maintaining **normal CSF pressure**.

Ventricular enlargement caused by excessive CSF accumulation typically occurs due to obstructed CSF circulation (noncommunicating hydrocephalus) or absorption (communicating hydrocephalus). In communicating hydrocephalus, CSF flows freely between the ventricles and subarachnoid space, but there is decreased CSF reabsorption at the arachnoid granulations **(Choice A)**. There are 2 major types of communicating hydrocephalus:

- Normal-pressure hydrocephalus (NPH) is caused by a chronic reduction in CSF absorption at the arachnoid villi, resulting in enlargement of the ventricles out of proportion to the overlying cortical atrophy. Because the impaired CSF absorption is chronic, the ventricles enlarge slowly, allowing the CSF pressure to normalize. Patients with NPH typically present with early ataxia followed by frontal lobe dementia and urinary incontinence.
- High-pressure hydrocephalus results from more acute impairment in CSF absorption (eg, cerebral venous sinus thrombosis, meningitis, acute subarachnoid hemorrhage) and typically presents with a change in mental status, seizure, headache, and focal neurologic deficits.

(Choice C) Lissencephaly (agyria) is a congenital absence of gyri. This condition is typically accompanied by severe mental retardation and seizures. On gross examination and imaging, the brain surface has a smooth appearance.

(Choice D) Obstruction of CSF flow within or between the ventricles and subarachnoid space is termed noncommunicating hydrocephalus. Congenital abnormalities (eg, aqueductal stenosis, Arnold-Chiari malformation) and tumors can lead to this type of hydrocephalus, resulting in symptoms of elevated intracranial pressure. In noncommunicating hydrocephalus, only the ventricles that are proximal to the obstruction are dilated.

(Choice E) Pseudotumor cerebri (idiopathic intracranial hypertension) refers to elevated intracranial pressure in the absence of ventricular enlargement on imaging. This disorder classically presents in young, obese women with headache, papilledema, and possible visual loss due to optic neuropathy.

Ventricular enlargement caused by excessive CSF accumulation typically occurs due to obstructed CSF circulation (noncommunicating hydrocephalus) or absorption (communicating hydrocephalus). In communicating hydrocephalus, CSF flows freely between the ventricles and subarachnoid space, but there is decreased CSF reabsorption at the arachnoid granulations **(Choice A)**. There are 2 major types of communicating hydrocephalus:

- Normal-pressure hydrocephalus (NPH) is caused by a chronic reduction in CSF absorption at the arachnoid villi, resulting in enlargement of the ventricles out of proportion to the overlying cortical atrophy. Because the impaired CSF absorption is chronic, the ventricles enlarge slowly, allowing the CSF pressure to normalize. Patients with NPH typically present with early ataxia followed by frontal lobe dementia and urinary incontinence.
- High-pressure hydrocephalus results from more acute impairment in CSF absorption (eg, cerebral venous sinus thrombosis, meningitis, acute subarachnoid hemorrhage) and typically presents with a change in mental status, seizure, headache, and focal neurologic deficits.

(Choice C) Lissencephaly (agyria) is a congenital absence of gyri. This condition is typically accompanied by severe mental retardation and seizures. On gross examination and imaging, the brain surface has a smooth appearance.

(Choice D) Obstruction of CSF flow within or between the ventricles and subarachnoid space is termed noncommunicating hydrocephalus. Congenital abnormalities (eg, aqueductal stenosis, Arnold-Chiari malformation) and tumors can lead to this type of hydrocephalus, resulting in symptoms of elevated intracranial pressure. In noncommunicating hydrocephalus, only the ventricles that are proximal to the obstruction are dilated.

(Choice E) Pseudotumor cerebri (idiopathic intracranial hypertension) refers to elevated intracranial pressure in the absence of ventricular enlargement on imaging. This disorder classically presents in young, obese women with headache, papilledema, and possible visual loss due to optic neuropathy.

(Choice F) Transtentorial (uncal) herniation can occur due to an intracranial mass (eg, tumor, hemorrhage) or cerebral edema. This may lead to compression of the ipsilateral oculomotor nerve and posterior cerebral artery. A fixed, dilated pupil on the same side as the lesion is often the first sign of uncal herniation.

Educational objective:

Settings

1 2 3 4 5 6 7 8 9 10 11 12 13 14 15 16 17 18 19 20 21 22 23 24 25 26 27 28 29 30

Item 12 of 40
Question Id: 14

Mark | Previous | Next | Full Screen | Tutorial | Lab Values | Notes | Calculator | Reverse Color | Text Zoom | Settings

Ventricular enlargement caused by excessive CSF accumulation typically occurs due to obstructed CSF circulation (noncommunicating

Exhibit Display

Zoom In | Zoom Out | Reset | Add To New Card | Existing Card

Educational objective:

Block Time Remaining: 00:00:29
TUTOR

4 | Feedback | Suspend | End Block

Settings

1
2
3
4
5
6
7
8
9
10
11
12
13
14
15
16
17
18
19
20
21
22
23
24
25
26
27
28
29
30

Item 12 of 40
Question Id: 14

Mark | Previous | Next | Full Screen | Tutorial | Lab Values | Notes | Calculator | Reverse Color | Text Zoom | Settings

Ventricular enlargement caused by excessive CSF accumulation typically occurs due to obstructed CSF circulation (noncommunicating

Exhibit Display

Zoom In | Zoom Out | Reset | Add To New Card | Existing Card

Educational objective:

Block Time Remaining: 00:00:29
TUTOR

4 | Feedback | Suspend | End Block

1 2 3 4 5 6 7 8 9 10 11 12 13 14 15 16 17 18 19 20 21 22 23 24 25 26 27 28 29 30

- High-pressure hydrocephalus results from more acute impairment in CSF absorption (eg, cerebral venous sinus thrombosis, meningitis, acute subarachnoid hemorrhage) and typically presents with a change in mental status, seizure, headache, and focal neurologic deficits.

(Choice C) Lissencephaly (agyria) is a congenital absence of gyri. This condition is typically accompanied by severe mental retardation and seizures. On gross examination and imaging, the brain surface has a smooth appearance.

(Choice D) Obstruction of CSF flow within or between the ventricles and subarachnoid space is termed noncommunicating hydrocephalus. Congenital abnormalities (eg, aqueductal stenosis, Arnold-Chiari malformation) and tumors can lead to this type of hydrocephalus, resulting in symptoms of elevated intracranial pressure. In noncommunicating hydrocephalus, only the ventricles that are proximal to the obstruction are dilated.

(Choice E) Pseudotumor cerebri (idiopathic intracranial hypertension) refers to elevated intracranial pressure in the absence of ventricular enlargement on imaging. This disorder classically presents in young, obese women with headache, papilledema, and possible visual loss due to optic neuropathy.

(Choice F) Transtentorial (uncal) herniation can occur due to an intracranial mass (eg, tumor, hemorrhage) or cerebral edema. This may lead to compression of the ipsilateral oculomotor nerve and posterior cerebral artery. A fixed, dilated pupil on the same side as the lesion is often the first sign of uncal herniation.

Educational objective:
Hydrocephalus is an enlargement of the ventricles (with or without elevated pressure) caused by either neuronal volume loss (eg, hydrocephalus ex-vacuo) or excessive cerebrospinal fluid accumulation (due to flow obstruction or impaired absorption). Neurodegenerative diseases (eg, AIDS dementia) can be associated with hydrocephalus ex-vacuo due to significant cortical atrophy, which allows the ventricles to expand while maintaining normal pressure.

Pathology	Nervous System	Hydrocephalus
Subject	System	Topic

Copyright © UWorld. All rights reserved.

1
2
3
4
5
6
7
8
9
10
11
12
13
14
15
16
17
18
19
20
21
22
23
24
25
26
27
28
29
30

- High-pressure hydrocephalus results from more acute impairment in CSF absorption (eg, cerebral venous sinus thrombosis, meningitis,

Exhibit Display

Major herniations of the brain

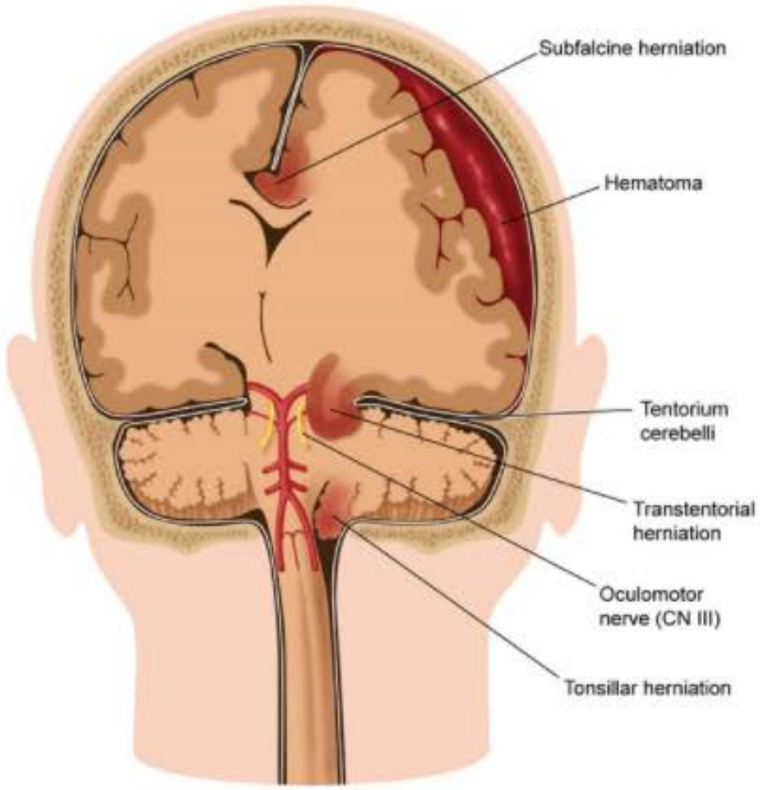

©UWorld

Zoom In | Zoom Out | Reset | Add To New Card | Existing Card

Settings

1 2 3 4 5 6 7 8 9 10 11 12 13 14 15 16 17 18 19 20 21 22 23 24 25 26 27 28 29 30

Item 13 of 40
Question Id: 16

Mark | Previous | Next | Full Screen | Tutorial | Lab Values | Notes | Calculator | Reverse Color | Text Zoom | Settings

A 64-year-old woman is evaluated for progressive gait disturbance over the last 2 years. The patient feels her feet are "stuck on the floor" and that she is unsteady while walking. She also recently began experiencing urinary urgency and has wet herself several times due to difficulty getting to the bathroom on time. The patient stopped working 6 months ago because of difficulty concentrating, and she has also lost interest in her hobbies and social activities. She has had no tremor, visual changes, headaches, nausea, or vomiting. The patient has a remote history of closed traumatic brain injury. Vital signs are within normal limits. On physical examination, lower extremity tone and deep tendon reflexes are increased. Sensation to light touch, pain, and vibration are normal. The patient's gait is slow with small steps and a wide base. CT scan of the head is shown below.

Block Time Remaining: 00:00:29
TUTOR

2 | Feedback | Suspend | End Block

Settings

1 2 3 4 5 6 7 8 9 10 11 12 13 14 15 16 17 18 19 20 21 22 23 24 25 26 27 28 29 30

Item 13 of 40
Question Id: 16

Mark | Previous | Next | Full Screen | Tutorial | Lab Values | Notes | Calculator | Reverse Color | Text Zoom | Settings

below.

Which of the following is the most likely diagnosis?

A. Alzheimer disease

Block Time Remaining: 00:00:32
TUTOR

2 | Feedback | Suspend | End Block

Settings

1 2 3 4 5 6 7 8 9 10 11 12 13 14 15 16 17 18 19 20 21 22 23 24 25 26 27 28 29 30

Item 13 of 40
Question Id: 16

Mark | Previous | Next | Full Screen | Tutorial | Lab Values | Notes | Calculator | Reverse Color | Text Zoom | Settings

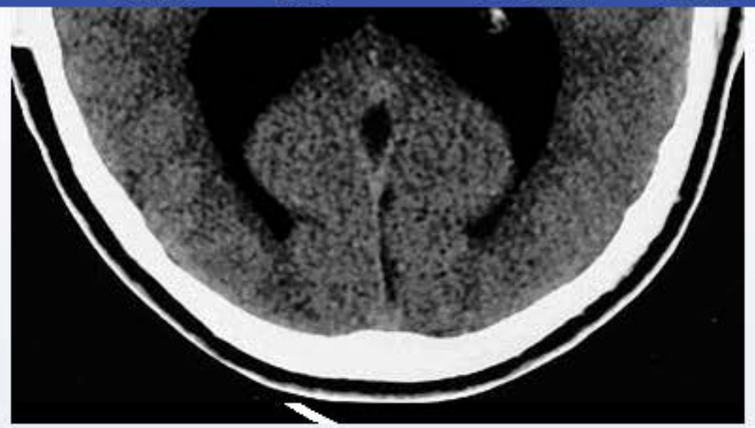

Which of the following is the most likely diagnosis?

- A. Alzheimer disease
- B. Frontotemporal dementia
- C. Idiopathic Parkinson disease
- D. Major depressive disorder
- E. Normal pressure hydrocephalus
- F. Obstructive hydrocephalus
- G. Vitamin B_{12} deficiency

Submit

Block Time Remaining: 00:00:33
TUTOR

2 | Feedback | Suspend | End Block

Settings

1 2 3 4 5 6 7 8 9 10 11 12 13 14 15 16 17 18 19 20 21 22 23 24 25 26 27 28 29 30

Item 13 of 40
Question Id: 16

Mark | Previous | Next | Full Screen | Tutorial | Lab Values | Notes | Calculator | Reverse Color | Text Zoom | Settings

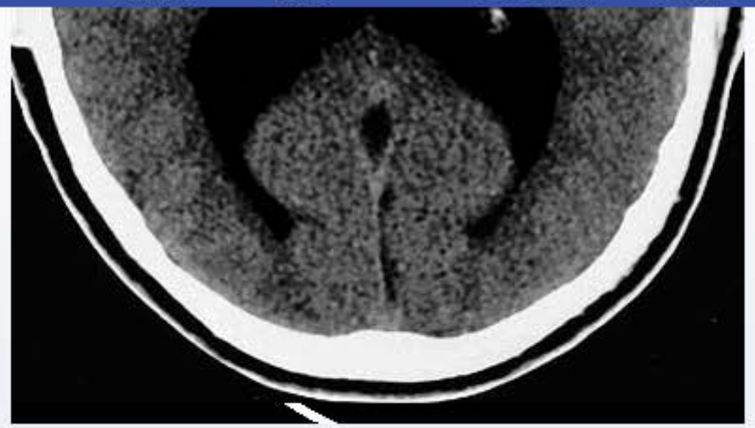

Which of the following is the most likely diagnosis?

- A. Alzheimer disease (1%)
- B. Frontotemporal dementia (0%)
- C. Idiopathic Parkinson disease (2%)
- D. Major depressive disorder (0%)
- ✓ E. Normal pressure hydrocephalus (85%)
- F. Obstructive hydrocephalus (10%)
- G. Vitamin B_{12} deficiency (0%)

Omitted
Correct answer

85%
Answered correctly

06 secs
Time Spent

03/30/2020
Last Updated

Block Time Remaining: 00:00:35
TUTOR

2 | Feedback | Suspend | End Block

This patient's CT scan demonstrates **ventriculomegaly** out of proportion to sulci enlargement, consistent with **normal pressure hydrocephalus** (NPH). NPH is a form of communicating hydrocephalus associated with decreased cerebrospinal fluid (CSF) resorption by the arachnoid granulations. It may be idiopathic or occur secondary to prior brain trauma (as in this patient), infection, or subarachnoid hemorrhage, resulting in scarring of the arachnoid granulations. As CSF accumulates, the ventricles progressively expand to accommodate the increasing volume, thereby maintaining normal intracranial pressure.

Symptoms of NPH are progressive and occur due to the disruption of periventricular white matter tracts by the expanding ventricles. Characteristic features include the following:

- **Gait difficulties** appear early in the disease course and are characterized by slow, short steps with decreased height. The feet may appear as though stuck to the ground (magnetic gait). Upper motor neuron signs (eg, spasticity, hyperreflexia) may also be evident.
- **Cognitive disturbances**, such as difficulty concentrating and apathy, usually become more apparent as the disease advances.
- **Urinary incontinence** is typically from urinary urgency. As the disease progresses, patients may develop apathy toward incontinence.

Symptoms often improve in response to large-volume CSF removal, and long-term treatment frequently involves placement of a ventriculoperitoneal shunt.

(Choice A) Alzheimer disease typically presents with memory deficits out of proportion to other cognitive domains. Although ventricular enlargement may be seen on imaging as the disease progresses, it occurs in proportion to sulci enlargement and is the result of generalized brain atrophy (hydrocephalus ex-vacuo).

(Choice B) Frontotemporal dementia causes memory deficits but primarily causes personality changes and aphasia. Neuroimaging demonstrates atrophy of the frontal and temporal lobes.

(Choice C) Parkinson disease causes gait abnormalities but is also typically associated with resting tremor and cogwheel rigidity. Cognitive deficits occur later in the disease course.

(Choice D) Major depressive disorder can be associated with impaired concentration and loss of interest in activities (anhedonia). However,

ventriculoperitoneal shunt.

(Choice A) Alzheimer disease typically presents with memory deficits out of proportion to other cognitive domains. Although ventricular enlargement may be seen on imaging as the disease progresses, it occurs in proportion to sulci enlargement and is the result of generalized brain atrophy (hydrocephalus ex-vacuo).

(Choice B) Frontotemporal dementia causes memory deficits but primarily causes personality changes and aphasia. Neuroimaging demonstrates atrophy of the frontal and temporal lobes.

(Choice C) Parkinson disease causes gait abnormalities but is also typically associated with resting tremor and cogwheel rigidity. Cognitive deficits occur later in the disease course.

(Choice D) Major depressive disorder can be associated with impaired concentration and loss of interest in activities (anhedonia). However, other features (eg, depressed mood, sleep disturbance) are not evident in this patient. In addition, neuroimaging and neurologic examination are typically normal.

(Choice F) Noncommunicating (obstructive) hydrocephalus is typically associated with congenital abnormalities (eg, aqueductal stenosis) and tumors. It causes ventriculomegaly but is associated with elevated intracranial pressure (eg, headache, nausea/vomiting).

(Choice G) Vitamin B_{12} deficiency can cause dementia but is typically associated with peripheral neuropathy (eg, abnormal position, vibration sense) and glossitis. Although MRI of the spinal cord can show degeneration of the posterior columns, CT scan of the head would be expected to be normal.

Educational objective:
Normal pressure hydrocephalus presents with progressive gait difficulties, cognitive disturbances, and urinary incontinence. It is a form of communicating hydrocephalus characterized by ventriculomegaly without persistent elevations in intercranial pressure. Brain imaging reveals ventricular enlargement out of proportion to sulci enlargement.

References

- A review of cognitive impairment and differential diagnosis in idiopathic normal pressure hydrocephalus.

Settings

1
2
3
4
5
6
7
8
9
10
11
12
13
14
15
16
17
18
19
20
21
22
23
24
25
26
27
28
29
30

Item 13 of 40
Question Id: 16

Mark | Previous | Next | Full Screen | Tutorial | Lab Values | Notes | Calculator | Reverse Color | Text Zoom | Settings

ventriculoperitoneal shunt.

Exhibit Display

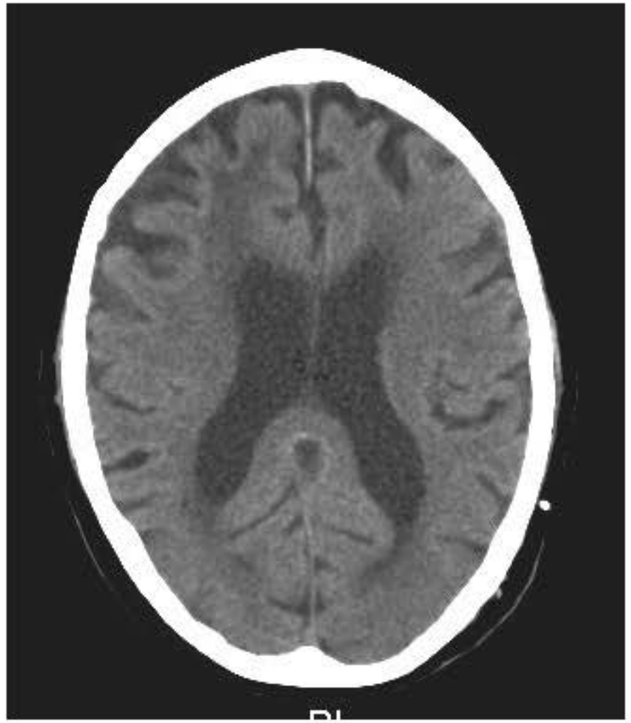

Zoom In | Zoom Out | Reset | Add To New Card | Existing Card

Block Time Remaining: 00:00:35
TUTOR

2 | Feedback | Suspend | End Block

Settings

1
2
3
4
5
6
7
8
9
10
11
12
13
14
15
16
17
18
19
20
21
22
23
24
25
26
27
28
29
30

Item 13 of 40
Question Id: 16

Mark | Previous | Next | Full Screen | Tutorial | Lab Values | Notes | Calculator | Reverse Color | Text Zoom | Settings

ventriculoperitoneal shunt.

Exhibit Display

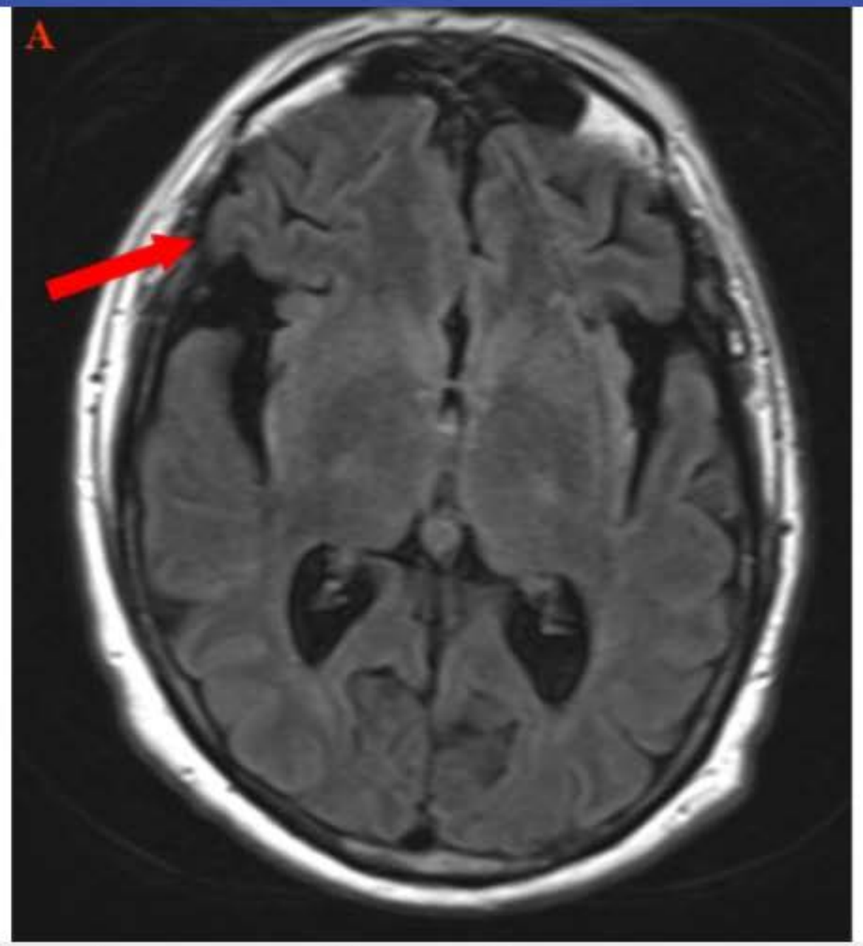

Zoom In | Zoom Out | Reset | Add To New Card | Existing Card

Block Time Remaining: 00:00:35
TUTOR

2 | Feedback | Suspend | End Block

Settings

1
2
3
4
5
6
7
8
9
10
11
12
13
14
15
16
17
18
19
20
21
22
23
24
25
26
27
28
29
30

Item 13 of 40
Question Id: 16

Mark | Previous | Next | Full Screen | Tutorial | Lab Values | Notes | Calculator | Reverse Color | Text Zoom | Settings

ventriculoperitoneal shunt.

Exhibit Display

Zoom In | Zoom Out | Reset | Add To New Card | Existing Card

Block Time Remaining: 00:00:35
TUTOR

2 | Feedback | Suspend | End Block

(Choice B) Frontotemporal dementia causes memory deficits but primarily causes personality changes and aphasia. Neuroimaging demonstrates atrophy of the frontal and temporal lobes.

(Choice C) Parkinson disease causes gait abnormalities but is also typically associated with resting tremor and cogwheel rigidity. Cognitive deficits occur later in the disease course.

(Choice D) Major depressive disorder can be associated with impaired concentration and loss of interest in activities (anhedonia). However, other features (eg, depressed mood, sleep disturbance) are not evident in this patient. In addition, neuroimaging and neurologic examination are typically normal.

(Choice F) Noncommunicating (obstructive) hydrocephalus is typically associated with congenital abnormalities (eg, aqueductal stenosis) and tumors. It causes ventriculomegaly but is associated with elevated intracranial pressure (eg, headache, nausea/vomiting).

(Choice G) Vitamin B_{12} deficiency can cause dementia but is typically associated with peripheral neuropathy (eg, abnormal position, vibration sense) and glossitis. Although MRI of the spinal cord can show degeneration of the posterior columns, CT scan of the head would be expected to be normal.

Educational objective:
Normal pressure hydrocephalus presents with progressive gait difficulties, cognitive disturbances, and urinary incontinence. It is a form of communicating hydrocephalus characterized by ventriculomegaly without persistent elevations in intercranial pressure. Brain imaging reveals ventricular enlargement out of proportion to sulci enlargement.

References

- A review of cognitive impairment and differential diagnosis in idiopathic normal pressure hydrocephalus.

Pathology	Nervous System	Normal pressure hydrocephalus
Subject	System	Topic

Copyright © UWorld. All rights reserved.

Settings

1 2 3 4 5 6 7 8 9 10 11 12 13 14 15 16 17 18 19 20 21 22 23 24 25 26 27 28 29 30

Item 14 of 40
Question Id: 12283

Mark | Previous | Next | Full Screen | Tutorial | Lab Values | Notes | Calculator | Reverse Color | Text Zoom | Settings

A 30-year-old man with a history of epilepsy comes to the office for follow-up. He has a history of recurrent seizures that start as jerky, rhythmic movements of his left leg and gradually spread to involve the entire left side of his body. The patient frequently loses consciousness and has been witnessed to have a generalized tonic-clonic seizure. Neuroimaging has revealed a focal lesion in the right motor area without any mass effect. He has been treated with several antiepilepsy drugs, but his seizures have remained poorly controlled. Surgery is performed to remove the lesion, and the excised brain tissue shows a 1.5-cm mass composed of engorged purplish clusters. Microscopy shows numerous dilated capillaries with an endothelial lining separated by a thin layer of fibrous connective tissue. Which of the following is the most likely diagnosis?

- A. Cavernous hemangioma
- B. Ependymoma
- C. Glioblastoma
- D. Kaposi sarcoma
- E. Saccular aneurysm

Submit

Block Time Remaining: 00:00:35
TUTOR

6 | Feedback | Suspend | End Block

Settings

1 2 3 4 5 6 7 8 9 10 11 12 13 14 15 16 17 18 19 20 21 22 23 24 25 26 27 28 29 30

Item 14 of 40
Question Id: 12283

Mark | Previous | Next | Full Screen | Tutorial | Lab Values | Notes | Calculator | Reverse Color | Text Zoom | Settings

A 30-year-old man with a history of epilepsy comes to the office for follow-up. He has a history of recurrent seizures that start as jerky, rhythmic movements of his left leg and gradually spread to involve the entire left side of his body. The patient frequently loses consciousness and has been witnessed to have a generalized tonic-clonic seizure. Neuroimaging has revealed a focal lesion in the right motor area without any mass effect. He has been treated with several antiepilepsy drugs, but his seizures have remained poorly controlled. Surgery is performed to remove the lesion, and the excised brain tissue shows a 1.5-cm mass composed of engorged purplish clusters. Microscopy shows numerous dilated capillaries with an endothelial lining separated by a thin layer of fibrous connective tissue. Which of the following is the most likely diagnosis?

- ✓ A. Cavernous hemangioma (69%)
- B. Ependymoma (7%)
- C. Glioblastoma (10%)
- D. Kaposi sarcoma (8%)
- E. Saccular aneurysm (4%)

Omitted
Correct answer
A

69%
Answered correctly

02 secs
Time Spent

03/26/2020
Last Updated

Explanation

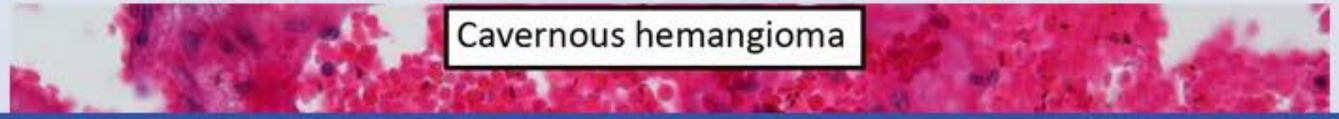

Block Time Remaining: 00:00:37
TUTOR

6 | Feedback | Suspend | End Block

1 2 3 4 5 6 7 8 9 10 11 12 13 14 15 16 17 18 19 20 21 22 23 24 25 26 27 28 29 30

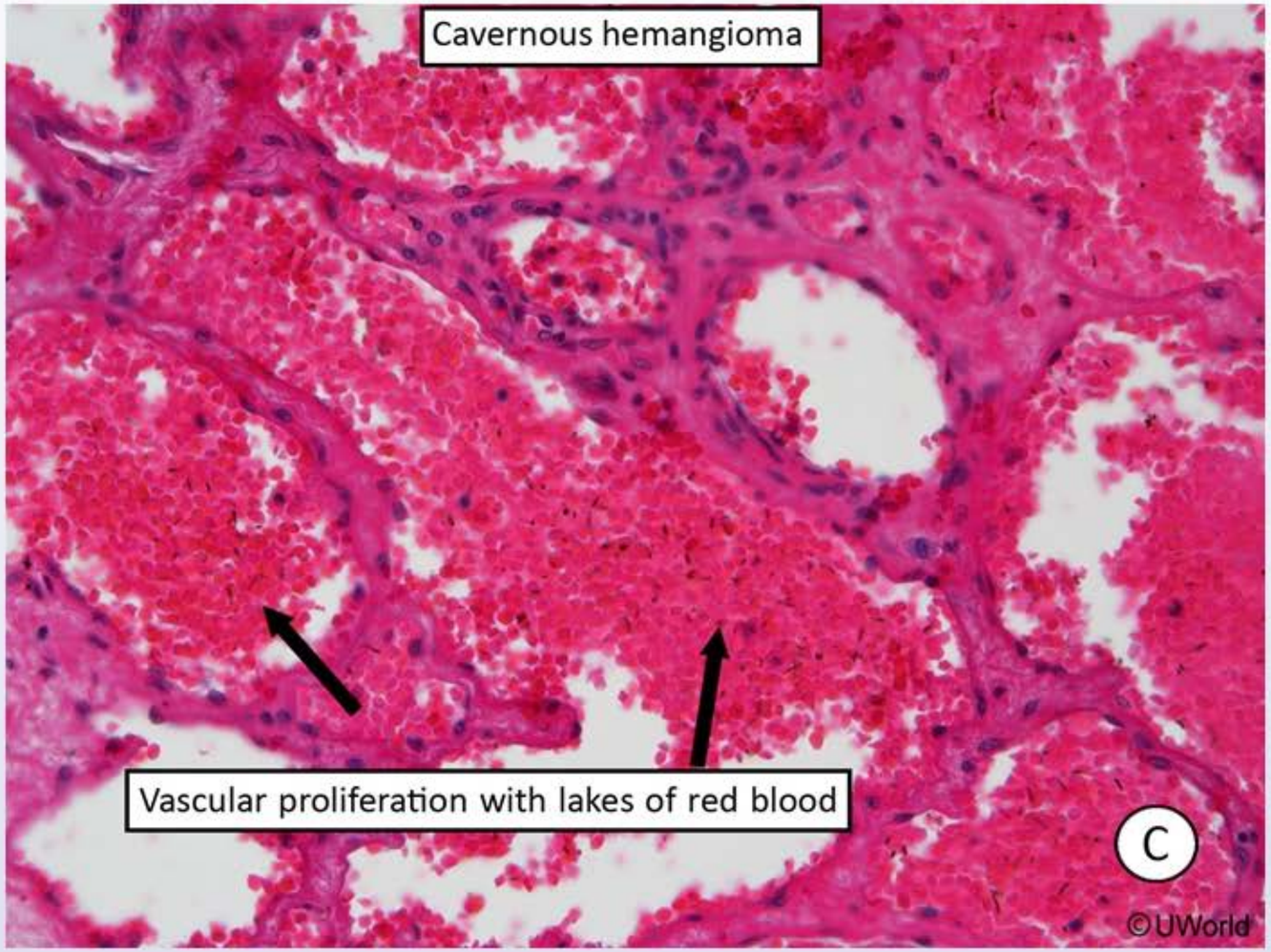

Cavernous hemangiomas are vascular malformations that frequently involve the deeper tissues of the body, such as the liver and brain. Gross examination of hemangiomas reveals a "mulberry-like" appearance due to their purple vascular clusters. Histologically, they are composed of

Cavernous hemangiomas are vascular malformations that frequently involve the deeper tissues of the body, such as the liver and brain. Gross examination of hemangiomas reveals a "mulberry-like" appearance due to their purple vascular clusters. Histologically, they are composed of abnormal, **dilated blood vessels** with a thin adventitia lacking elastic fibers and smooth muscle. The reduced structural support gives them a tendency to leak, causing **recurrent hemorrhage**.

Most patients with cavernous hemangiomas are asymptomatic, although hemangiomas in the brain may cause **neurologic deficits** and **seizures** due to compression of the surrounding tissue and irritation from recurrent bleeding. Surgical resection is indicated for lesions causing intractable epilepsy or progressive neurologic deficits.

(Choice B) Ependymoma is a rare central nervous system tumor typically found intracranially in children and in the spinal cord in adults. The tumor cells may arrange themselves around blood vessels and form intervening processes, a histological appearance called perivascular pseudorosettes.

(Choice C) Glioblastoma is a common and aggressive brain tumor characterized histologically by areas of necrosis surrounded by anaplastic cells (pseudopalisading necrosis).

(Choice D) Kaposi sarcoma is a tumor that results from infection with human herpesvirus 8. It typically manifests as skin nodules but can also affect the gastrointestinal and respiratory tracts. Microscopic evaluation reveals highly vascular tissue containing elongated spindle cells.

(Choice E) Saccular (berry) aneurysms are vascular outpouchings composed of a thickened intima due to myointimal hyperplasia with a stretched adventitial layer. They occur as a result of congenital blood vessel weakness and are found most commonly in the circle of Willis. Intracranial aneurysms are typically asymptomatic unless they rupture.

Educational objective:
Cavernous hemangiomas are vascular malformations composed of abnormally dilated capillaries separated by thin connective tissue septa. The lack of structural support gives them a tendency to bleed, and those that occur in the brain can present with neurologic deficits and seizures.

Pathology	Nervous System	Hemangioma
Subject	System	Topic

Settings

1 2 3 4 5 6 7 8 9 10 11 12 13 14 15 16 17 18 19 20 21 22 23 24 25 26 27 28 29 30

Item 14 of 40
Question Id: 12283

Mark | Previous | Next | Full Screen | Tutorial | Lab Values | Notes | Calculator | Reverse Color | Text Zoom | Settings

Cavernous hemangiomas are vascular malformations that frequently involve the deeper tissues of the body, such as the liver and brain. Gross

Exhibit Display

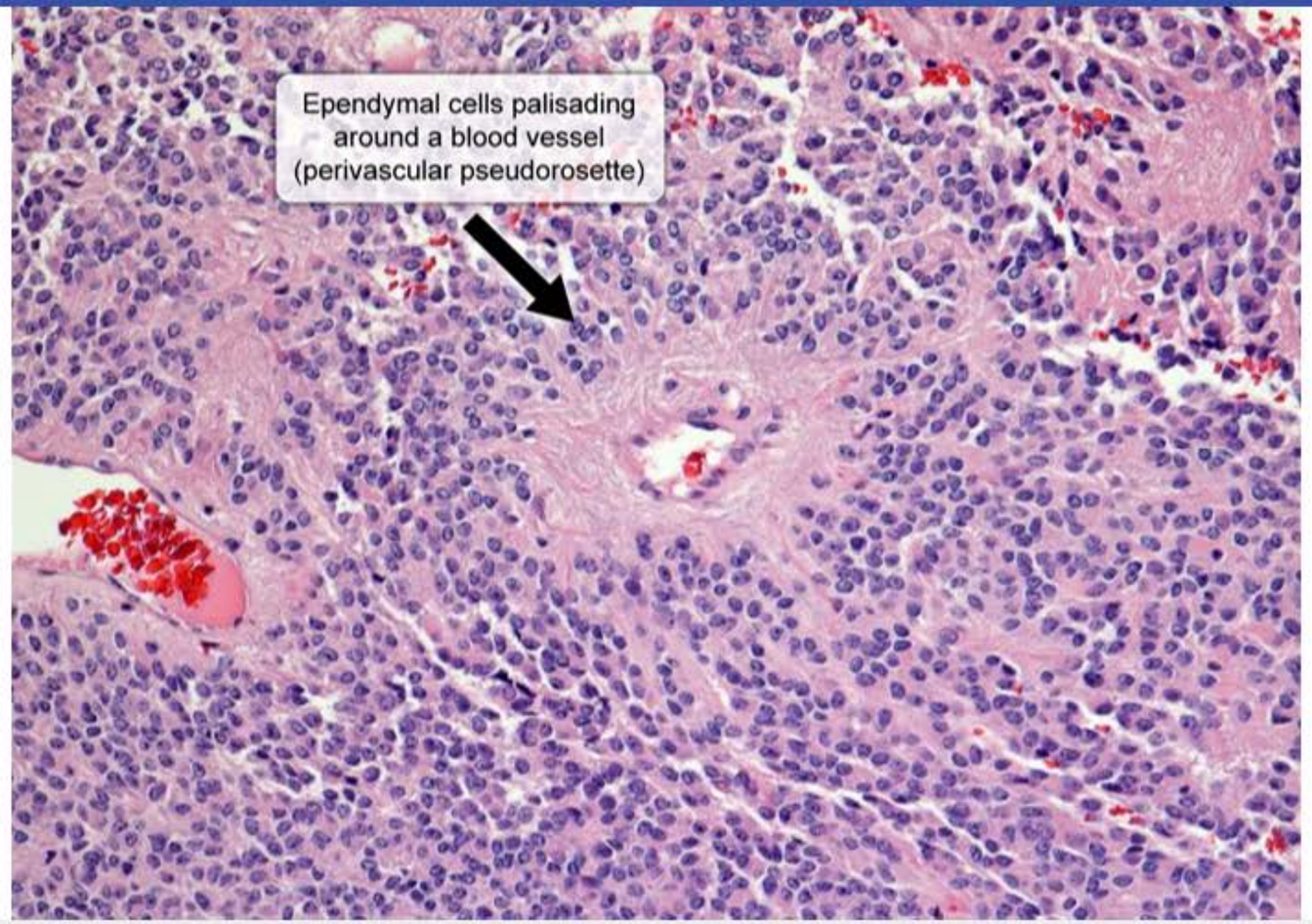

Zoom In | Zoom Out | Reset | Add To New Card | Existing Card

Block Time Remaining: 00:00:37
TUTOR

6 | Feedback | Suspend | End Block

Settings

1 2 3 4 5 6 7 8 9 10 11 12 13 14 15 16 17 18 19 20 21 22 23 24 25 26 27 28 29 30

Item 14 of 40
Question Id: 12283

Mark | Previous | Next | Full Screen | Tutorial | Lab Values | Notes | Calculator | Reverse Color | Text Zoom | Settings

Cavernous hemangiomas are vascular malformations that frequently involve the deeper tissues of the body, such as the liver and brain. Gross

Exhibit Display

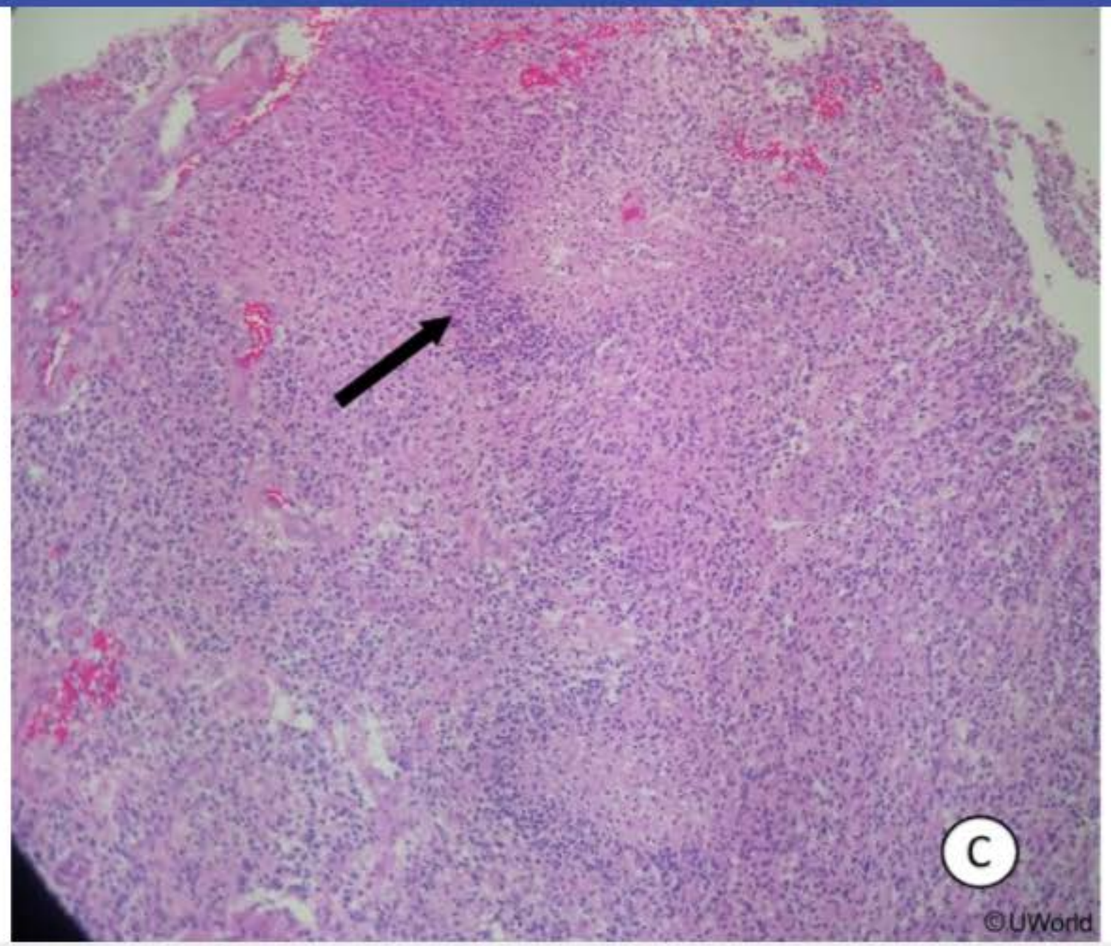

Zoom In | Zoom Out | Reset | Add To New Card | Existing Card

Block Time Remaining: 00:00:37
TUTOR

6 | Feedback | Suspend | End Block

Settings

1
2
3
4
5
6
7
8
9
10
11
12
13
14
15
16
17
18
19
20
21
22
23
24
25
26
27
28
29
30

Item 14 of 40
Question Id: 12283

Mark | Previous | Next | Full Screen | Tutorial | Lab Values | Notes | Calculator | Reverse Color | Text Zoom | Settings

Cavernous hemangiomas are vascular malformations that frequently involve the deeper tissues of the body, such as the liver and brain. Gross

Exhibit Display

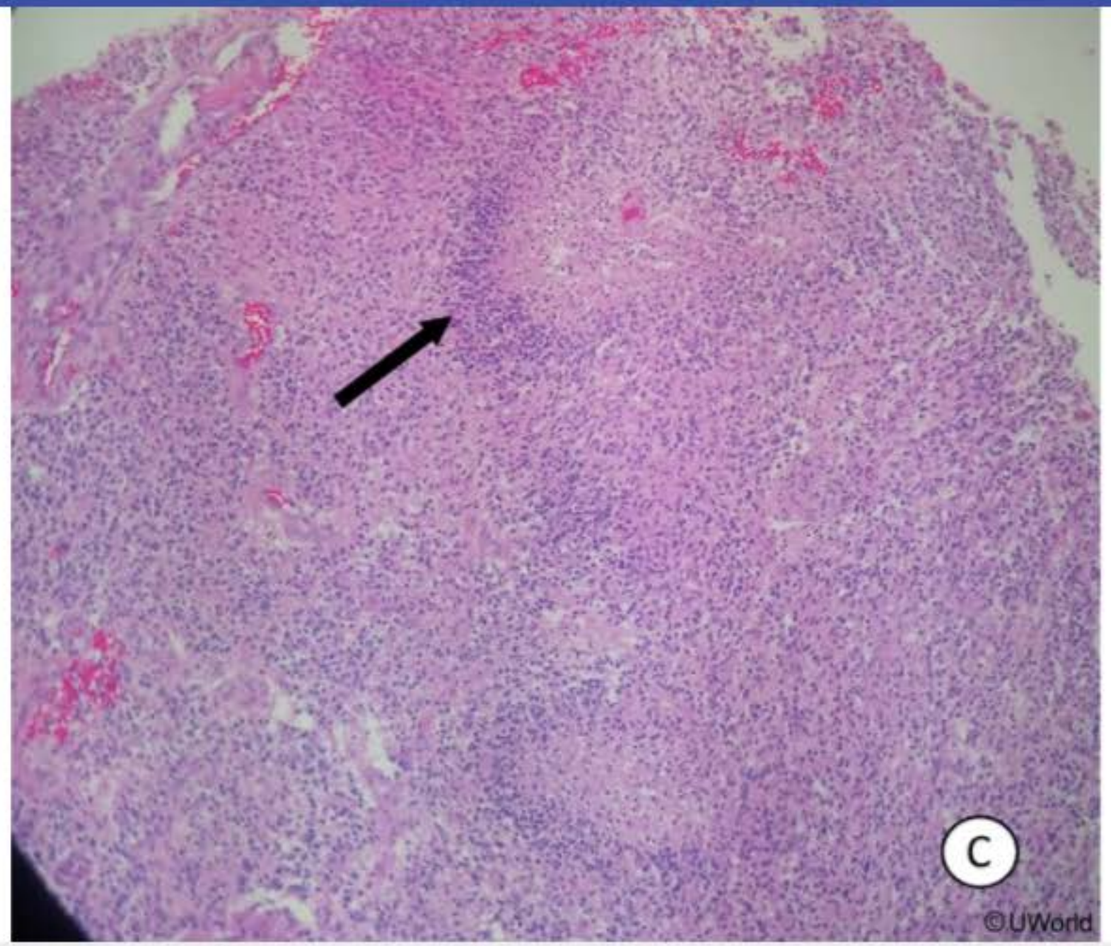

Zoom In | Zoom Out | Reset | Add To New Card | Existing Card

Block Time Remaining: 00:00:37
TUTOR

6 | Feedback | Suspend | End Block

Settings

1
2
3
4
5
6
7
8
9
10
11
12
13
14
15
16
17
18
19
20
21
22
23
24
25
26
27
28
29
30

Item 14 of 40
Question Id: 12283

Mark | Previous | Next | Full Screen | Tutorial | Lab Values | Notes | Calculator | Reverse Color | Text Zoom | Settings

Cavernous hemangiomas are vascular malformations that frequently involve the deeper tissues of the body, such as the liver and brain. Gross

Exhibit Display

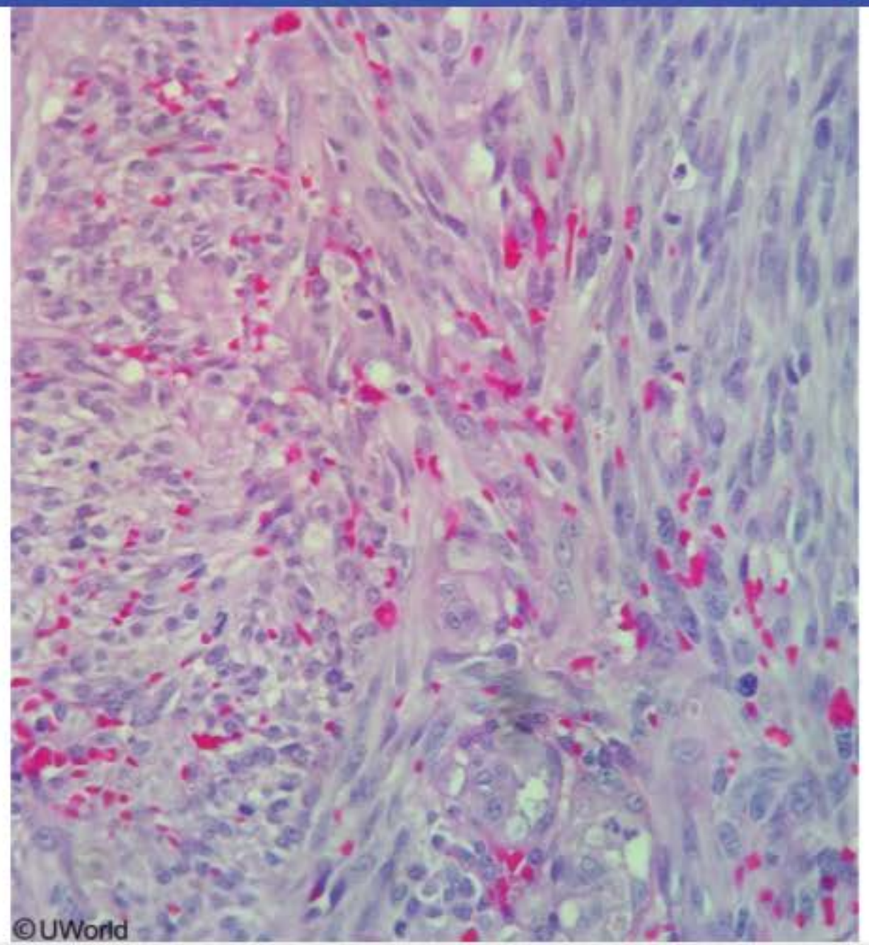

Zoom In | Zoom Out | Reset | Add To New Card | Existing Card

Block Time Remaining: 00:00:37
TUTOR

6 | Feedback | Suspend | End Block

Settings

1 2 3 4 5 6 7 8 9 10 11 12 13 14 15 16 17 18 19 20 21 22 23 24 25 26 27 28 29 30

Item 15 of 40
Question Id: 15591

Mark | Previous | Next | Full Screen | Tutorial | Lab Values | Notes | Calculator | Reverse Color | Text Zoom | Settings

An 82-year-old man is brought to the emergency department after multiple falls. He has had severe back pain over the last month, for which he has been taking over-the-counter pain medication without significant relief. Over the last week, the patient has noted weakness in his legs bilaterally, and his gait has become unstable. Medical history is significant for hypertension, hyperlipidemia, coronary artery disease, and gout. The patient has lost 6.8 kg (15 lb) in the last month due to poor appetite. Rectal examination reveals an enlarged, firm, nodular prostate. Which of the following is the most likely cause of this patient's current symptoms?

A. Aggregates of malignant cells in the intramedullary spinal cord

B. Compression fracture of the vertebral body

C. Extension of neoplastic cells into the epidural space

D. Intervertebral disc protrusion with spinal cord compression

E. Spondylosis resulting in spinal stenosis

Submit

Block Time Remaining: 00:00:37
TUTOR

5 | Feedback | Suspend | End Block

Settings

1 2 3 4 5 6 7 8 9 10 11 12 13 14 15 16 17 18 19 20 21 22 23 24 25 26 27 28 29 30

Item 15 of 40
Question Id: 15591

Mark | Previous | Next | Full Screen | Tutorial | Lab Values | Notes | Calculator | Reverse Color | Text Zoom | Settings

An 82-year-old man is brought to the emergency department after multiple falls. He has had severe back pain over the last month, for which he has been taking over-the-counter pain medication without significant relief. Over the last week, the patient has noted weakness in his legs bilaterally, and his gait has become unstable. Medical history is significant for hypertension, hyperlipidemia, coronary artery disease, and gout. The patient has lost 6.8 kg (15 lb) in the last month due to poor appetite. Rectal examination reveals an enlarged, firm, nodular prostate. Which of the following is the most likely cause of this patient's current symptoms?

A. Aggregates of malignant cells in the intramedullary spinal cord (35%)

B. Compression fracture of the vertebral body (18%)

✓ C. Extension of neoplastic cells into the epidural space (35%)

D. Intervertebral disc protrusion with spinal cord compression (6%)

E. Spondylosis resulting in spinal stenosis (4%)

Omitted
Correct answer
C

35%
Answered correctly

02 secs
Time Spent

03/23/2020
Last Updated

Explanation

Spinal cord tumors

Block Time Remaining: 00:00:39
TUTOR

5 | Feedback | Suspend | End Block

Settings

1 2 3 4 5 6 7 8 9 10 11 12 13 14 15 16 17 18 19 20 21 22 23 24 25 26 27 28 29 30

Item 15 of 40
Question Id: 15591

Mark | Previous | Next | Full Screen | Tutorial | Lab Values | Notes | Calculator | Reverse Color | Text Zoom | Settings

Spinal cord tumors

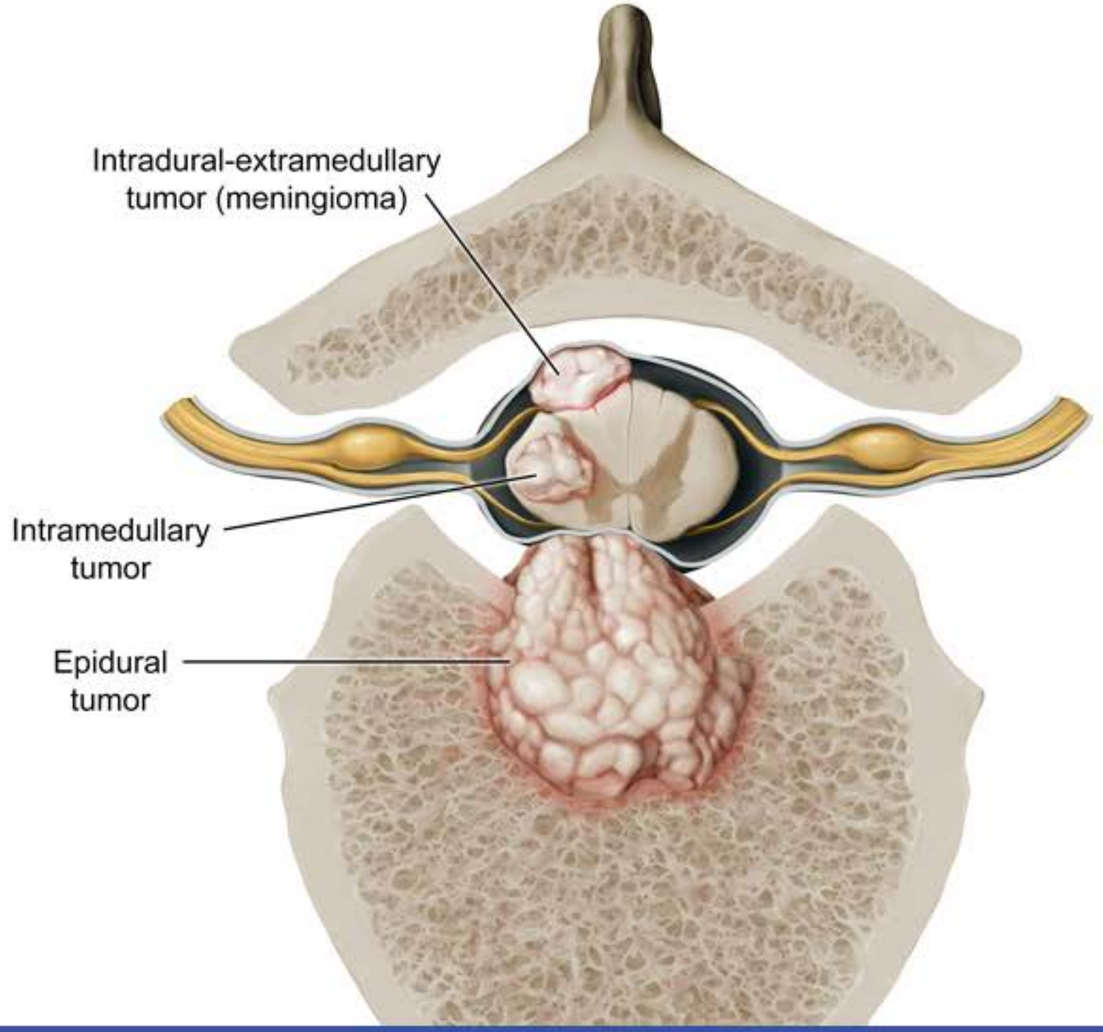

Block Time Remaining: 00:00:39
TUTOR

5 | Feedback | Suspend | End Block

Settings

1 2 3 4 5 6 7 8 9 10 11 12 13 14 15 16 17 18 19 20 21 22 23 24 25 26 27 28 29 30

Item 15 of 40
Question Id: 15591

Mark | Previous | Next | Full Screen | Tutorial | Lab Values | Notes | Calculator | Reverse Color | Text Zoom | Settings

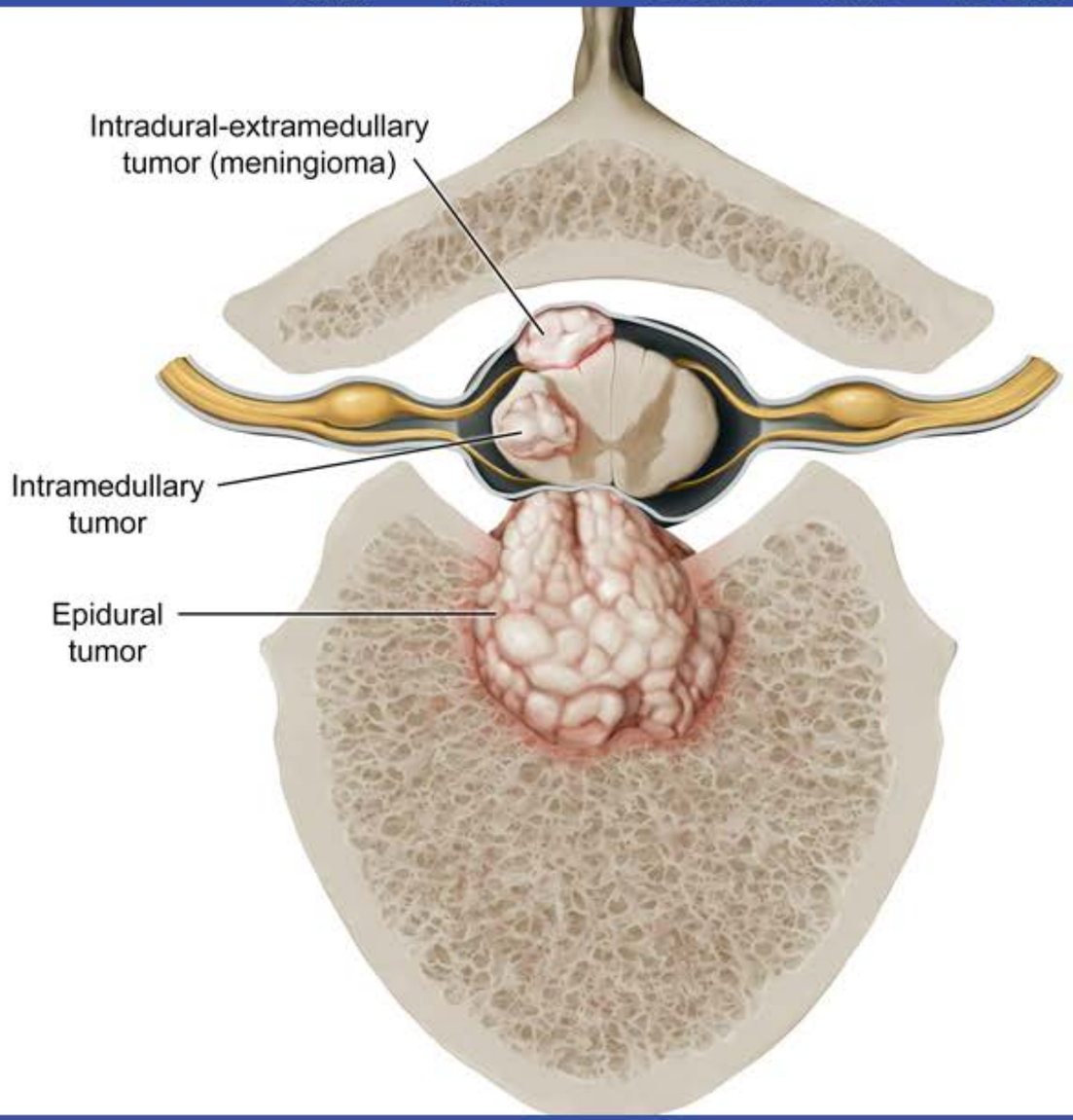

Block Time Remaining: 00:00:39
TUTOR

5 | Feedback | Suspend | End Block

©UWorld

This elderly patient with severe back pain developed lower extremity weakness and gait instability. In association with his weight loss and enlarged nodular prostate, this presentation is concerning for **neoplastic cord compression**. Spinal cord compression is a frequent complication of advanced malignancy, especially breast, lung, and prostate cancers.

Neoplastic cord compression most commonly results from **local extension of vertebral metastases** (neoplastic cells) into the **epidural space**. The tumors can encase the thecal sac and cause venous obstruction, leading to vasogenic edema, cord ischemia, and infarction. Presenting symptoms depend on the level of cord involvement but typically include **severe back pain** (often worse at night) that progresses to include **motor weakness** and/or **sensory deficits**. Urinary and fecal retention or incontinence are common late-stage findings. MRI is diagnostic.

(Choice A) Intramedullary metastases (malignant cells within the intramedullary spinal cord) are very rare and usually associated with lung cancer. Because of the tumor location within the spinal cord, as opposed to an adjacent structure, Brown-Séquard syndrome (ie, ipsilateral hemiplegia, contralateral sensory loss) is a common presentation.

(Choice B) Compression fractures are common in elderly patients, particularly those with osteoporosis, and can cause severe back pain. Although pathologic fractures can occur due to vertebral metastases, subsequent cord compression due to retropulsed bone fragments occurs only rarely and is a less common cause of cord compression than direct epidural invasion by the tumor mass.

(Choice D) Intervertebral disc herniation can cause back pain and spinal cord compression but more commonly causes focal radiculopathy due to nerve root compression (eg, sciatica). In addition, this patient's weight loss and abnormal prostate examination are more suggestive of neoplastic cord compression.

(Choice E) Spondylosis (age-related degeneration of the spinal column) can cause spinal stenosis (narrowing of the spinal canal) with cord compression, typically due to osteophyte formation or thickening of the ligamentum flavum. However, symptoms are typically slowly progressive rather than of rapid onset, as seen in this patient.

Educational objective:
Neoplastic spinal cord compression most commonly results from local extension of vertebral metastases into the epidural space. Presenting symptoms typically include severe back pain (often worse at night), motor weakness, and/or sensory deficits. Urinary and fecal retention or

Settings

1 2 3 4 5 6 7 8 9 10 11 12 13 14 15 16 17 18 19 20 21 22 23 24 25 26 27 28 29 30

Item 15 of 40
Question Id: 15591

Mark | Previous | Next | Full Screen | Tutorial | Lab Values | Notes | Calculator | Reverse Color | Text Zoom | Settings

©UWorld

Exhibit Display

Vertebral column injuries

Normal

Compression fracture

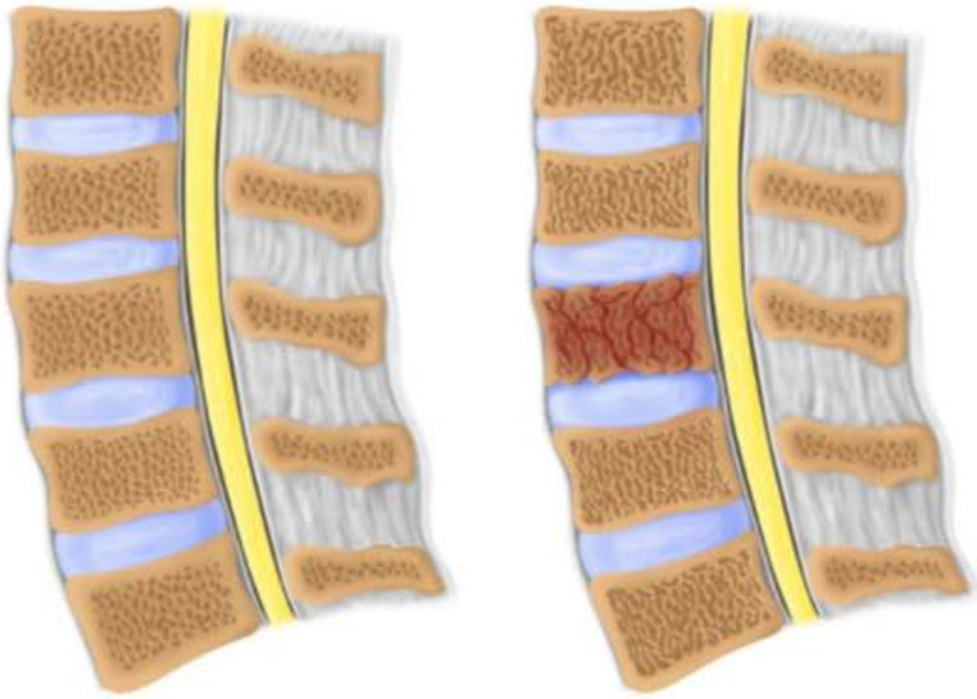

USMLEWorld, LLC © 2011

Zoom In | Zoom Out | Reset | Add To New Card | Existing Card

Block Time Remaining: 00:00:39
TUTOR

5 | Feedback | Suspend | End Block

©UWorld

Exhibit Display

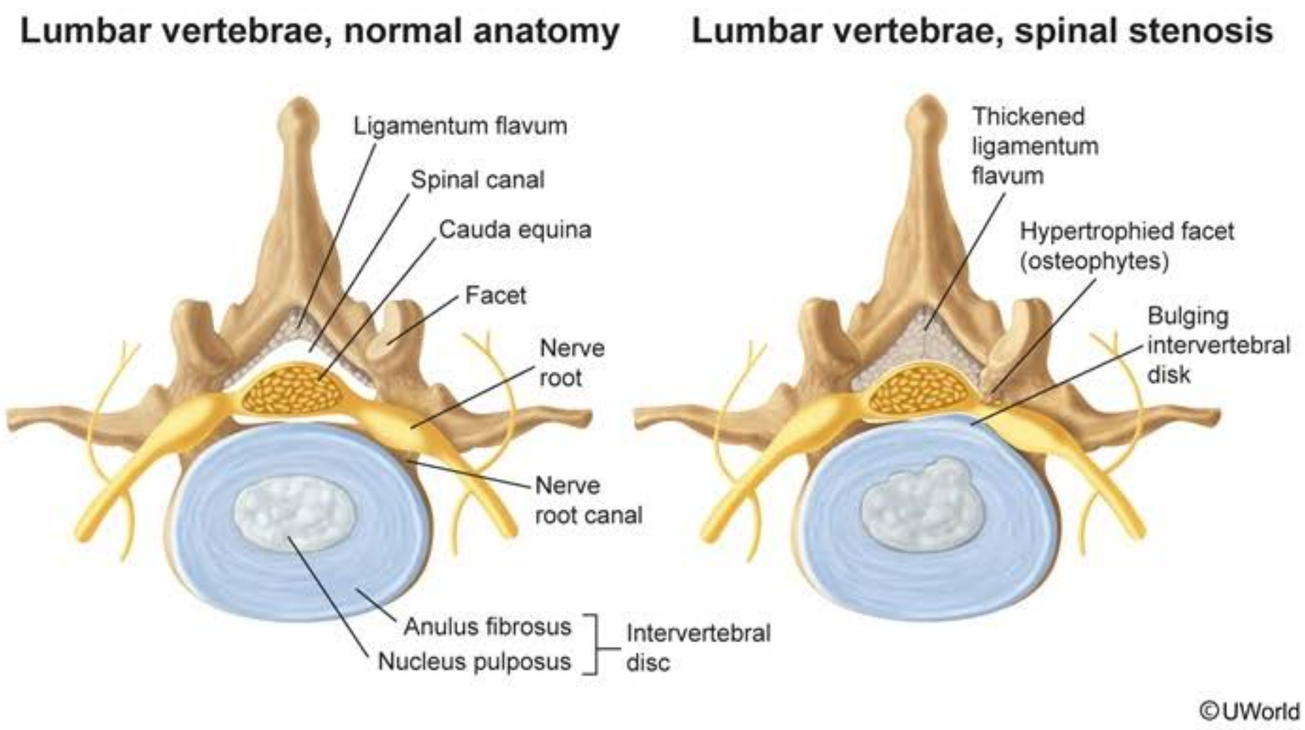

Zoom In | Zoom Out | Reset | Add To New Card | Existing Card

1 2 3 4 5 6 7 8 9 10 11 12 13 14 15 16 17 18 19 20 21 22 23 24 25 26 27 28 29 30

The tumors can encase the thecal sac and cause venous obstruction, leading to vasogenic edema, cord ischemia, and infarction. Presenting symptoms depend on the level of cord involvement but typically include **severe back pain** (often worse at night) that progresses to include **motor weakness** and/or **sensory deficits**. Urinary and fecal retention or incontinence are common late-stage findings. MRI is diagnostic.

(Choice A) Intramedullary metastases (malignant cells within the intramedullary spinal cord) are very rare and usually associated with lung cancer. Because of the tumor location within the spinal cord, as opposed to an adjacent structure, Brown-Séquard syndrome (ie, ipsilateral hemiplegia, contralateral sensory loss) is a common presentation.

(Choice B) Compression fractures are common in elderly patients, particularly those with osteoporosis, and can cause severe back pain. Although pathologic fractures can occur due to vertebral metastases, subsequent cord compression due to retropulsed bone fragments occurs only rarely and is a less common cause of cord compression than direct epidural invasion by the tumor mass.

(Choice D) Intervertebral disc herniation can cause back pain and spinal cord compression but more commonly causes focal radiculopathy due to nerve root compression (eg, sciatica). In addition, this patient's weight loss and abnormal prostate examination are more suggestive of neoplastic cord compression.

(Choice E) Spondylosis (age-related degeneration of the spinal column) can cause spinal stenosis (narrowing of the spinal canal) with cord compression, typically due to osteophyte formation or thickening of the ligamentum flavum. However, symptoms are typically slowly progressive rather than of rapid onset, as seen in this patient.

Educational objective:
Neoplastic spinal cord compression most commonly results from local extension of vertebral metastases into the epidural space. Presenting symptoms typically include severe back pain (often worse at night), motor weakness, and/or sensory deficits. Urinary and fecal retention or incontinence are common late-stage findings.

Pathology	Nervous System	Spinal cord compression
Subject	System	Topic

Copyright © UWorld. All rights reserved.

Settings

1 2 3 4 5 6 7 8 9 10 11 12 13 14 15 16 17 18 19 20 21 22 23 24 25 26 27 28 29 30

Item 16 of 40
Question Id: 12011

Mark | Previous | Next | Full Screen | Tutorial | Lab Values | Notes | Calculator | Reverse Color | Text Zoom | Settings

A 64-year-old man comes to the office for routine evaluation. Review of his family history reveals that multiple family members have the same disease. As a result, the patient is enrolled in a study to determine the genetic basis of his familial condition. An abnormal gene is located in the long arm of chromosome 21 and encodes a transmembrane protein found in various tissues and organs. A protease cleaves the protein to generate small polypeptide residues that tend to form insoluble aggregates. These polypeptide fragments predispose to which of the following conditions?

- A. Dementia
- B. Ischemic stroke
- C. Mesothelioma
- D. Multiple sclerosis
- E. Psoriasis

Submit

Block Time Remaining: 00:00:39
TUTOR

5 | Feedback | Suspend | End Block

Settings

1 2 3 4 5 6 7 8 9 10 11 12 13 14 15 16 17 18 19 20 21 22 23 24 25 26 27 28 29 30

Item 16 of 40
Question Id: 12011

Mark | Previous | Next | Full Screen | Tutorial | Lab Values | Notes | Calculator | Reverse Color | Text Zoom | Settings

A 64-year-old man comes to the office for routine evaluation. Review of his family history reveals that multiple family members have the same disease. As a result, the patient is enrolled in a study to determine the genetic basis of his familial condition. An abnormal gene is located in the long arm of chromosome 21 and encodes a transmembrane protein found in various tissues and organs. A protease cleaves the protein to generate small polypeptide residues that tend to form insoluble aggregates. These polypeptide fragments predispose to which of the following conditions?

- ✓ A. Dementia (96%)
- B. Ischemic stroke (1%)
- C. Mesothelioma (0%)
- D. Multiple sclerosis (1%)
- E. Psoriasis (0%)

Omitted
Correct answer
A

96%
Answered correctly

02 secs
Time Spent

05/13/2020
Last Updated

Explanation

Processing of amyloid precursor protein

Non-amyloidogenic | Amyloidogenic | Alzheimer dementia

Block Time Remaining: 00:00:41
TUTOR

5 | Feedback | Suspend | End Block

1 2 3 4 5 6 7 8 9 10 11 12 13 14 15 16 17 18 19 20 21 22 23 24 25 26 27 28 29 30

Processing of amyloid precursor protein

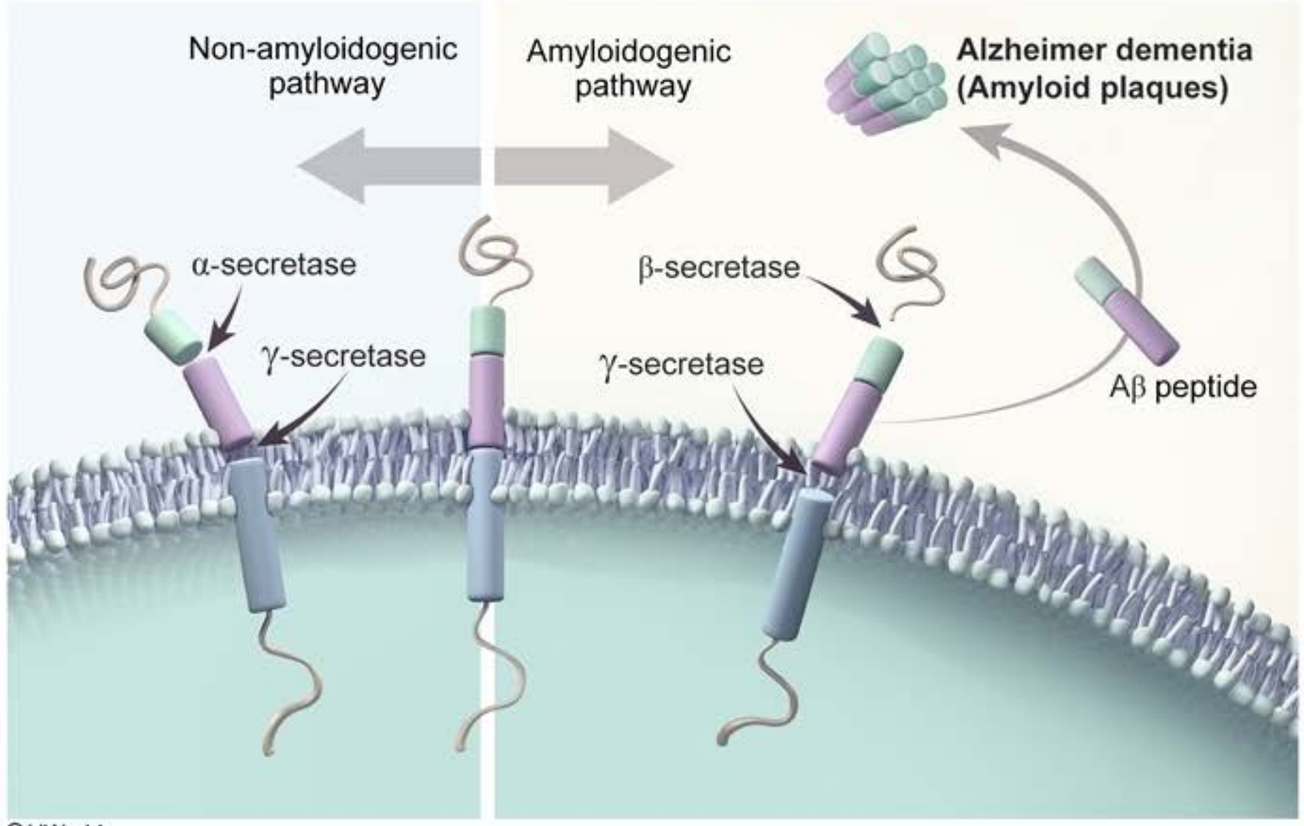

©UWorld

The **amyloid precursor protein** (APP) gene (located on chromosome 21) encodes a highly conserved transmembrane protein found throughout the body, whose inappropriate processing predisposes to **Alzheimer dementia** (AD). APP is processed in 1 of 2 pathways by a series of secretases (proteolytic enzymes): Processing via the alpha- and gamma-secretase pathway, which does not result in amyloidogenic proteins, or processing via the beta- and gamma-secretase pathway, which results in the production of **beta-amyloid**.

©UWorld

The **amyloid precursor protein** (APP) gene (located on chromosome 21) encodes a highly conserved transmembrane protein found throughout the body, whose inappropriate processing predisposes to **Alzheimer dementia** (AD). APP is processed in 1 of 2 pathways by a series of secretases (proteolytic enzymes): Processing via the alpha- and gamma-secretase pathway, which does not result in amyloidogenic proteins, or processing via the beta- and gamma-secretase pathway, which results in the production of **beta-amyloid**.

If beta-amyloid is not sufficiently cleared by cellular processes, it can form insoluble fibrils and contribute to the generation of extracellular amyloid plaques. These aggregates of beta-amyloid are neurotoxic and thought to play a key role in the pathogenesis of AD. As a result, patients who have abnormal APP processing, impaired beta-amyloid clearance, or production of higher levels of APP (eg, trisomy 21 [Down syndrome]) are at increased risk of developing AD.

(Choice B) Ischemic stroke can occur due to rupture of atherosclerotic plaques within cerebral arteries. Atherosclerosis begins with endothelial dysfunction (eg, due to hypertension, dyslipidemia, diabetes mellitus, smoking), which subsequently promotes macrophage and LDL accumulation in the intima, followed by smooth muscle cell proliferation and extracellular matrix deposition.

(Choice C) Patients exposed to asbestos are at risk of developing pleural plaques and malignant mesothelioma, although pleural plaques themselves are not premalignant. Pleural plaques are collections of calcified dense collagen fibers that develop secondary to reactive inflammation against asbestosis fibers.

(Choice D) Multiple sclerosis is an autoimmune disorder characterized by central nervous system plaques that are often ovoid-shaped and involve the periventricular white matter. These plaques are composed of demyelinated neurons and inflammatory cells.

(Choice E) Patients with psoriasis usually have symmetrically distributed cutaneous plaques with silvery scaling that involve the extensor surfaces (eg, elbows, knees). These skin plaques are caused by immune dysregulation and keratinocyte hyperproliferation.

Educational objective:
Inappropriate processing of amyloid precursor protein down the beta- and gamma-secretase pathway results in the production of beta-amyloid. Insufficient clearance of beta-amyloid can result in formation of extracellular amyloid plaques, which are neurotoxic and thought to play a key role in the pathogenesis of Alzheimer dementia.

Settings

1
2
3
4
5
6
7
8
9
10
11
12
13
14
15
16
17
18
19
20
21
22
23
24
25
26
27
28
29
30

Item 16 of 40
Question Id: 12011

Mark | Previous | Next | Full Screen | Tutorial | Lab Values | Notes | Calculator | Reverse Color | Text Zoom | Settings

©UWorld

Exhibit Display

Alzheimer's disease Alzheimer's disease Alzheimer's disease

Zoom In | Zoom Out | Reset | Add To New Card | Existing Card

Block Time Remaining: 00:00:41
TUTOR

5 | Feedback | Suspend | End Block

Settings

1
2
3
4
5
6
7
8
9
10
11
12
13
14
15
16
17
18
19
20
21
22
23
24
25
26
27
28
29
30

Item 16 of 40
Question Id: 12011

Mark | Previous | Next | Full Screen | Tutorial | Lab Values | Notes | Calculator | Reverse Color | Text Zoom | Settings

©UWorld

Exhibit Display

Alzheimer's disease Alzheimer's disease Alzheimer's disease

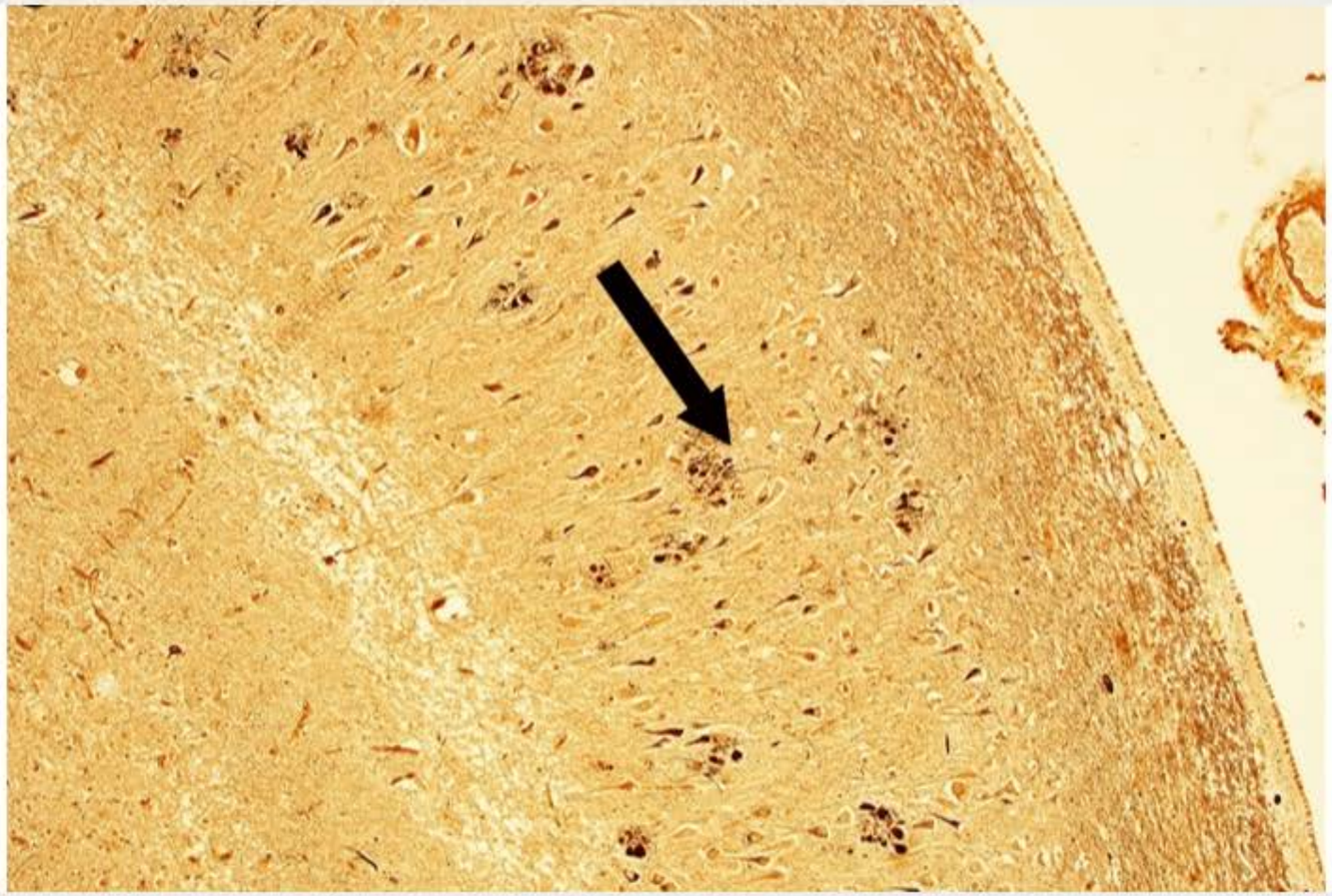

Zoom In | Zoom Out | Reset | Add To New Card | Existing Card

Block Time Remaining: 00:00:41
TUTOR

5 | Feedback | Suspend | End Block

Settings

1
2
3
4
5
6
7
8
9
10
11
12
13
14
15
16
17
18
19
20
21
22
23
24
25
26
27
28
29
30

Item 16 of 40
Question Id: 12011

Mark | Previous | Next | Full Screen | Tutorial | Lab Values | Notes | Calculator | Reverse Color | Text Zoom | Settings

©UWorld

Exhibit Display

Alzheimer's disease Alzheimer's disease Alzheimer's disease

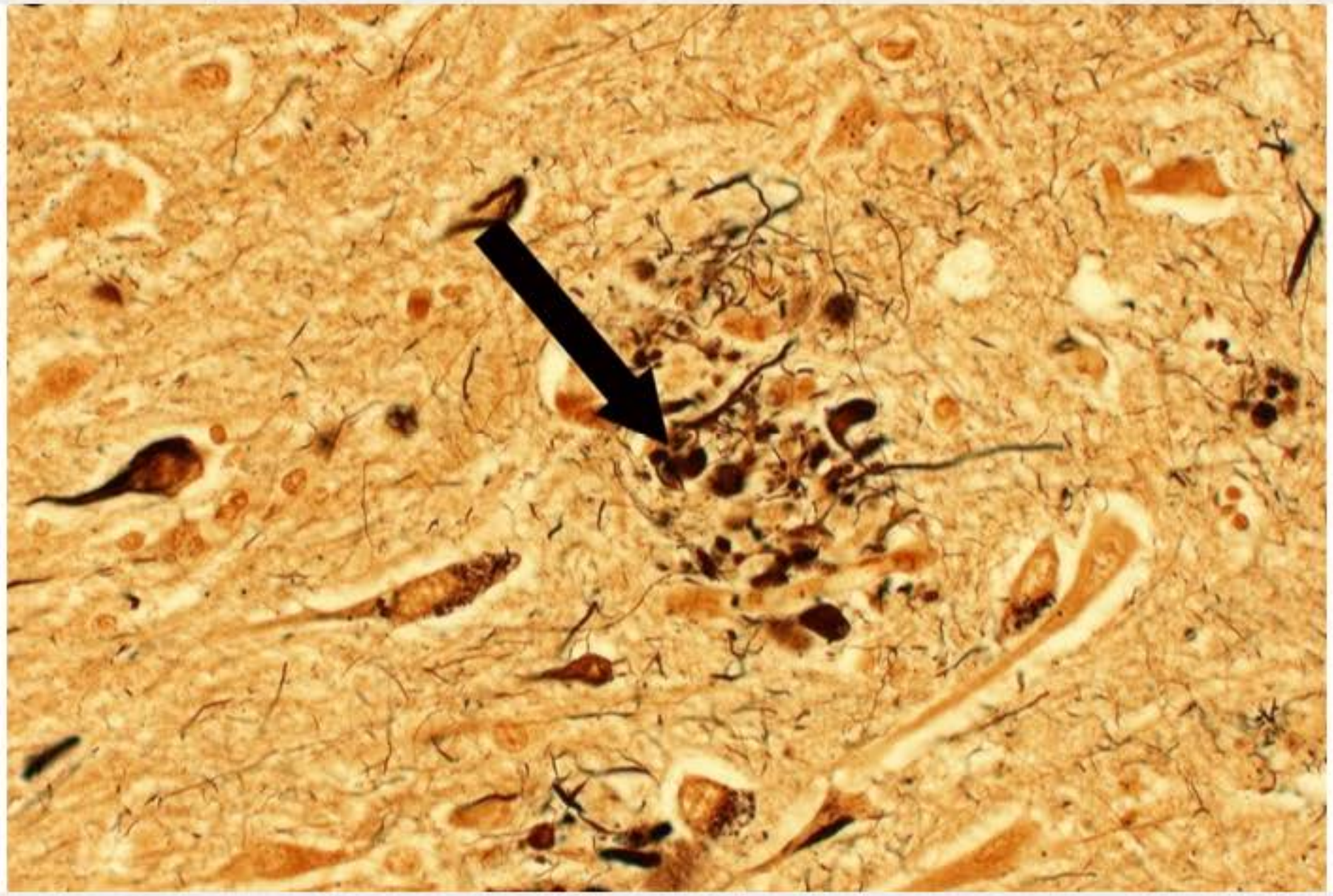

Zoom In | Zoom Out | Reset | Add To New Card | Existing Card

Block Time Remaining: 00:00:41
TUTOR

5 | Feedback | Suspend | End Block

increased risk of developing AD.

(Choice B) Ischemic stroke can occur due to rupture of atherosclerotic plaques within cerebral arteries. Atherosclerosis begins with endothelial dysfunction (eg, due to hypertension, dyslipidemia, diabetes mellitus, smoking), which subsequently promotes macrophage and LDL accumulation in the intima, followed by smooth muscle cell proliferation and extracellular matrix deposition.

(Choice C) Patients exposed to asbestos are at risk of developing pleural plaques and malignant mesothelioma, although pleural plaques themselves are not premalignant. Pleural plaques are collections of calcified dense collagen fibers that develop secondary to reactive inflammation against asbestosis fibers.

(Choice D) Multiple sclerosis is an autoimmune disorder characterized by central nervous system plaques that are often ovoid-shaped and involve the periventricular white matter. These plaques are composed of demyelinated neurons and inflammatory cells.

(Choice E) Patients with psoriasis usually have symmetrically distributed cutaneous plaques with silvery scaling that involve the extensor surfaces (eg, elbows, knees). These skin plaques are caused by immune dysregulation and keratinocyte hyperproliferation.

Educational objective:
Inappropriate processing of amyloid precursor protein down the beta- and gamma-secretase pathway results in the production of beta-amyloid. Insufficient clearance of beta-amyloid can result in formation of extracellular amyloid plaques, which are neurotoxic and thought to play a key role in the pathogenesis of Alzheimer dementia.

References

- ß-Amyloid: The key peptide in the pathogenesis of Alzheimer's disease.
- Mechanisms of amyloid-ß peptide clearance: Potential therapeutic targets for Alzheimer's disease.

Pathology	Nervous System	Alzheimer disease
Subject	System	Topic

Copyright © UWorld. All rights reserved.

Settings

1 2 3 4 5 6 7 8 9 10 11 12 13 14 15 16 17 18 19 20 21 22 23 24 25 26 27 28 29 30

Item 17 of 40
Question Id: 613

Mark | Previous | Next | Full Screen | Tutorial | Lab Values | Notes | Calculator | Reverse Color | Text Zoom | Settings

A 62-year-old man is brought to the emergency department after a new-onset, generalized tonic-clonic seizure. His wife reports that for the past several weeks he has been having episodic headaches, nausea, and progressive weakness. The headaches are particularly worse at night and occasionally awaken him from sleep. His other medical problems include well-controlled hypertension and osteoarthritis. On physical examination, the patient is postictal but follows simple commands. He is admitted to the hospital for further evaluation but dies several days later due to aspiration pneumonia and septic shock. A brain section obtained during postmortem examination is shown in the image below.

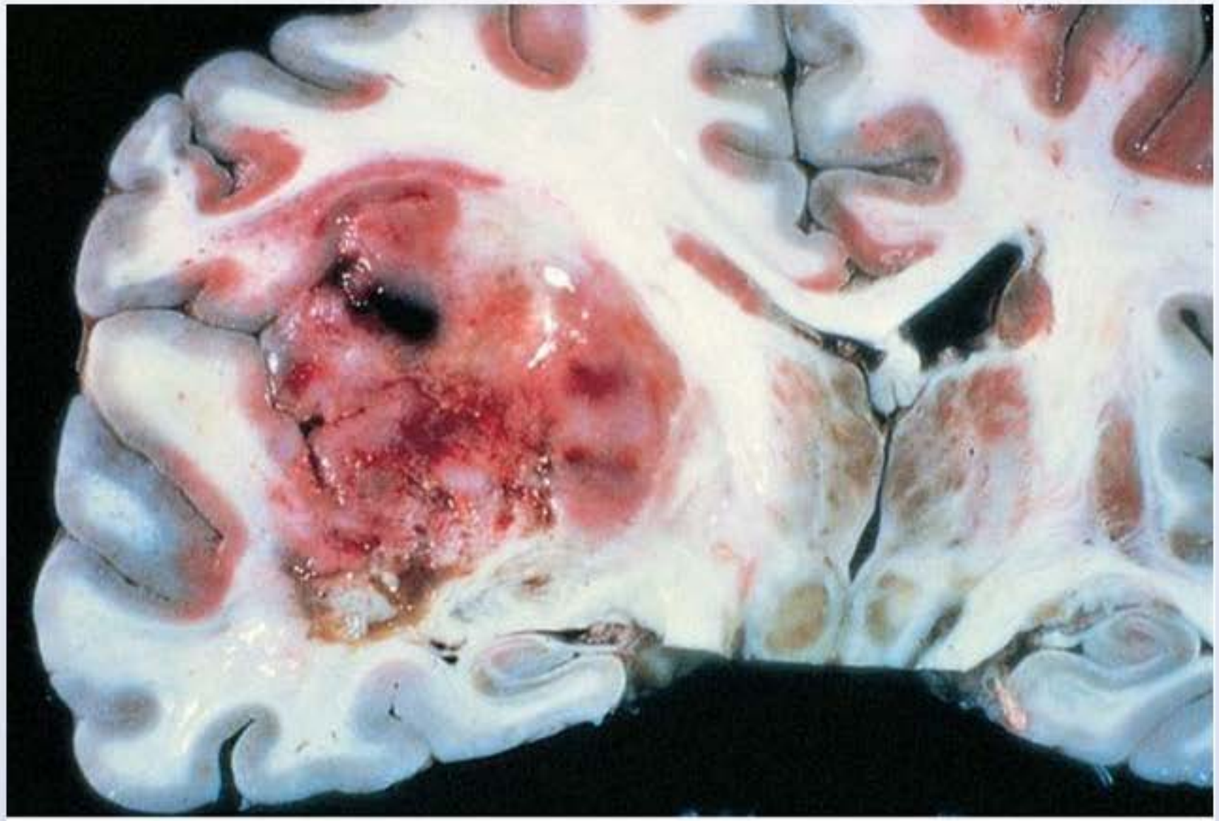

Displayed with permission from Springer Healthcare Ltd. © Copyright 2002 by Current Medicine

Block Time Remaining: 00:00:42
TUTOR

3 | Feedback | Suspend | End Block

Settings

1 2 3 4 5 6 7 8 9 10 11 12 13 14 15 16 17 18 19 20 21 22 23 24 25 26 27 28 29 30

Item 17 of 40
Question Id: 613

Mark | Previous | Next | Full Screen | Tutorial | Lab Values | Notes | Calculator | Reverse Color | Text Zoom | Settings

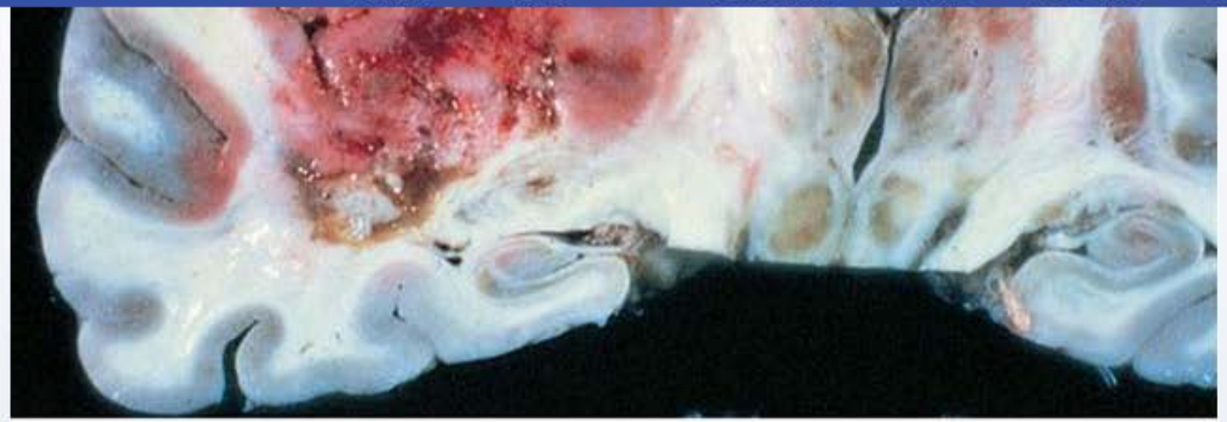

Displayed with permission from Springer Healthcare Ltd. © Copyright 2002 by Current Medicine

This patient most likely had which of the following conditions?

- A. Brain metastasis
- B. Glioblastoma
- C. Meningioma
- D. Oligodendroglioma
- E. Primary brain lymphoma
- F. Schwannoma

Submit

Block Time Remaining: 00:00:44
TUTOR

3 | Feedback | Suspend | End Block

Settings

1 2 3 4 5 6 7 8 9 10 11 12 13 14 15 16 17 18 19 20 21 22 23 24 25 26 27 28 29 30

Item 17 of 40
Question Id: 613

Mark | Previous | Next | Full Screen | Tutorial | Lab Values | Notes | Calculator | Reverse Color | Text Zoom | Settings

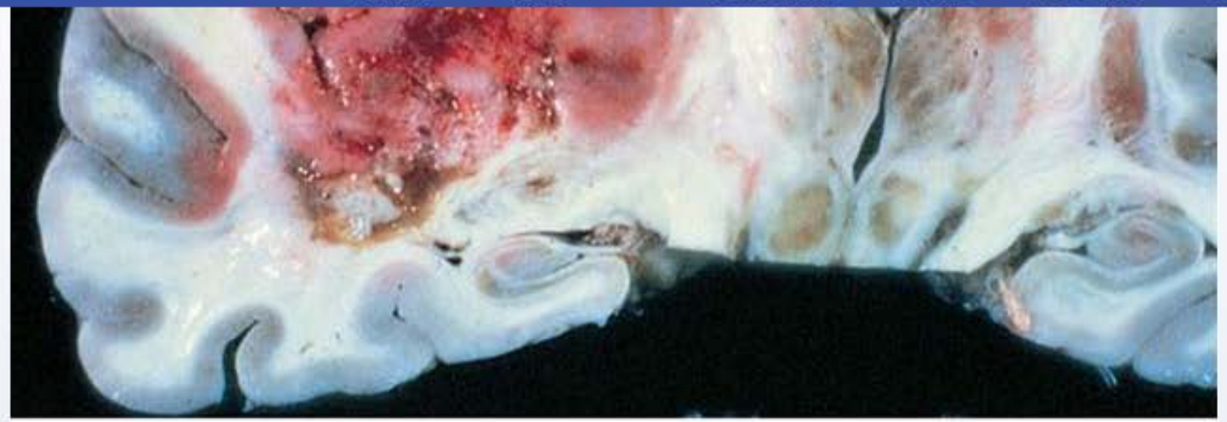

Displayed with permission from Springer Healthcare Ltd. © Copyright 2002 by Current Medicine

This patient most likely had which of the following conditions?

- A. Brain metastasis (19%)
- ✓ B. Glioblastoma (60%)
- C. Meningioma (5%)
- D. Oligodendroglioma (10%)
- E. Primary brain lymphoma (3%)
- F. Schwannoma (0%)

Omitted
Correct answer

60%
Answered correctly

04 secs
Time Spent

05/30/2020
Last Updated

Block Time Remaining: 00:00:45
TUTOR

3 | Feedback | Suspend | End Block

1 2 3 4 5 6 7 8 9 10 11 12 13 14 15 16 17 18 19 20 21 22 23 24 25 26 27 28 29 30

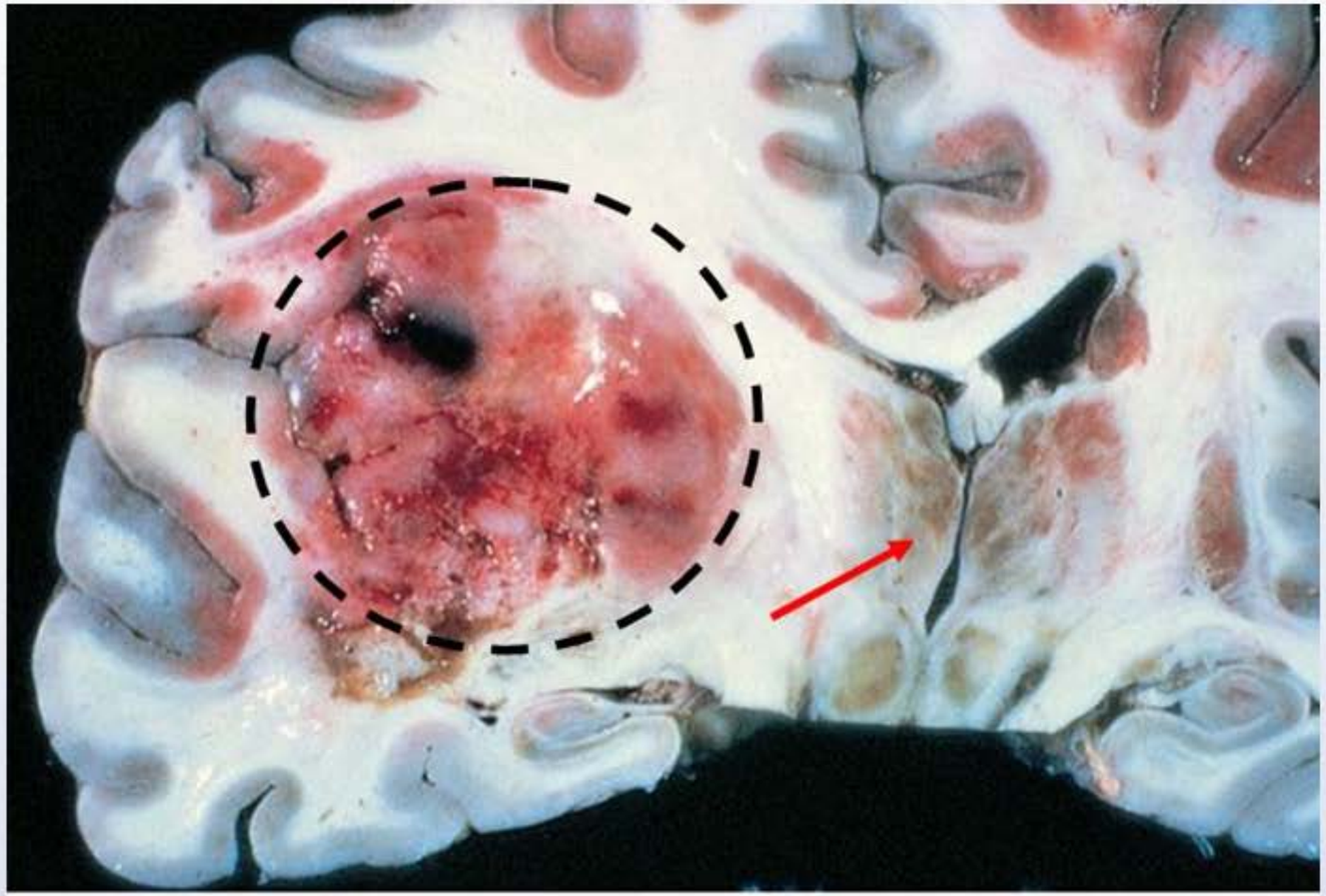

Displayed with permission from Springer Healthcare Ltd. © Copyright 2002 by Current Medicine

The solitary lesion designated by the dashed circle in the image above likely represents **glioblastoma**, the most common primary cerebral neoplasm in adults. Glioblastoma arises from astrocytes and is typically located within the **cerebral hemispheres**. Tumors can become significantly large, causing mass effect with midline shift (red arrow), and may occasionally cross the corpus callosum ("butterfly glioma"). On

Displayed with permission from Springer Healthcare Ltd. © Copyright 2002 by Current Medicine

The solitary lesion designated by the dashed circle in the image above likely represents **glioblastoma**, the most common primary cerebral neoplasm in adults. Glioblastoma arises from astrocytes and is typically located within the **cerebral hemispheres**. Tumors can become significantly large, causing mass effect with midline shift (red arrow), and may occasionally cross the corpus callosum ("butterfly glioma"). On gross examination, glioblastomas are soft and poorly defined with areas of **necrosis** and **hemorrhage**. These tumors are highly malignant with a very poor prognosis as most patients die less than a year after diagnosis.

(Choice A) Most adult brain tumors represent metastases from other cancers, especially those of the lung, breast, kidney, and skin (eg, melanoma). However, on gross examination, brain metastases typically appear as multiple, well-circumscribed masses at the junction of gray and white matter.

(Choice C) Meningiomas are benign, well-circumscribed neoplasms of adults that arise from arachnoid cells (external to the brain parenchyma). They are typically located on the brain surface at sites of dural reflection (eg, falx cerebri, tentorium cerebelli).

(Choice D) Oligodendrogliomas are slow growing tumors of adults that typically involve the white matter of the cerebral hemispheres. On gross examination, they usually appear as well-circumscribed gray masses with calcification.

(Choice E) Primary central nervous system lymphoma is most often seen in the immunocompromised (eg, patients with AIDS, transplant recipients) and appears as multiple brain lesions involving the deep gray matter, white matter, and cortex.

(Choice F) Schwannomas are mostly benign tumors that commonly arise from the vestibular branch of cranial nerve VIII at the cerebellopontine angle (vestibular schwannoma). Patients typically present with sensorineural hearing loss and tinnitus.

Educational objective:
Glioblastoma is the most common primary cerebral neoplasm of adults that is typically located within the cerebral hemispheres and may cross the midline ("butterfly glioma"). These tumors are highly malignant and grossly contain areas of necrosis and hemorrhage.

References

- Primary brain tumors in adults.

Settings

1 2 3 4 5 6 7 8 9 10 11 12 13 14 15 16 17 18 19 20 21 22 23 24 25 26 27 28 29 30

Item 18 of 40
Question Id: 1264

Mark | Previous | Next | Full Screen | Tutorial | Lab Values | Notes | Calculator | Reverse Color | Text Zoom | Settings

A 43-year-old woman says she cannot sleep due to pain and tingling affecting the first three digits of both hands. She has no problems with her legs. The patient suffers from chronic renal failure due to uncontrolled hypertension and receives hemodialysis. On examination, she has bilaterally diminished sensation over the thumb, index and middle fingers, and the radial half of her ring finger. Which of the following is the most likely mechanism of this patient's condition?

A. Endomysial inflammatory infiltration

B. Endoneural arteriole hyalinization

C. Endoneural multifocal demyelination

D. Mutations of a muscle structural protein gene

E. Nerve compression within an anatomic compartment

Submit

Block Time Remaining: 00:00:45
TUTOR

4 | Feedback | Suspend | End Block

1 2 3 4 5 6 7 8 9 10 11 12 13 14 15 16 17 18 19 20 21 22 23 24 25 26 27 28 29 30

A 43-year-old woman says she cannot sleep due to pain and tingling affecting the first three digits of both hands. She has no problems with her legs. The patient suffers from chronic renal failure due to uncontrolled hypertension and receives hemodialysis. On examination, she has bilaterally diminished sensation over the thumb, index and middle fingers, and the radial half of her ring finger. Which of the following is the most likely mechanism of this patient's condition?

A. Endomysial inflammatory infiltration (4%)

B. Endoneural arteriole hyalinization (24%)

C. Endoneural multifocal demyelination (6%)

D. Mutations of a muscle structural protein gene (0%)

✓ E. Nerve compression within an anatomic compartment (64%)

Omitted
Correct answer
E

64%
Answered correctly

01 sec
Time Spent

01/20/2020
Last Updated

Explanation

Carpal tunnel, palmar view

Settings

1 2 3 4 5 6 7 8 9 10 11 12 13 14 15 16 17 18 19 20 21 22 23 24 25 26 27 28 29 30

Item 18 of 40
Question Id: 1264

Mark | Previous | Next | Full Screen | Tutorial | Lab Values | Notes | Calculator | Reverse Color | Text Zoom | Settings

Carpal tunnel, palmar view

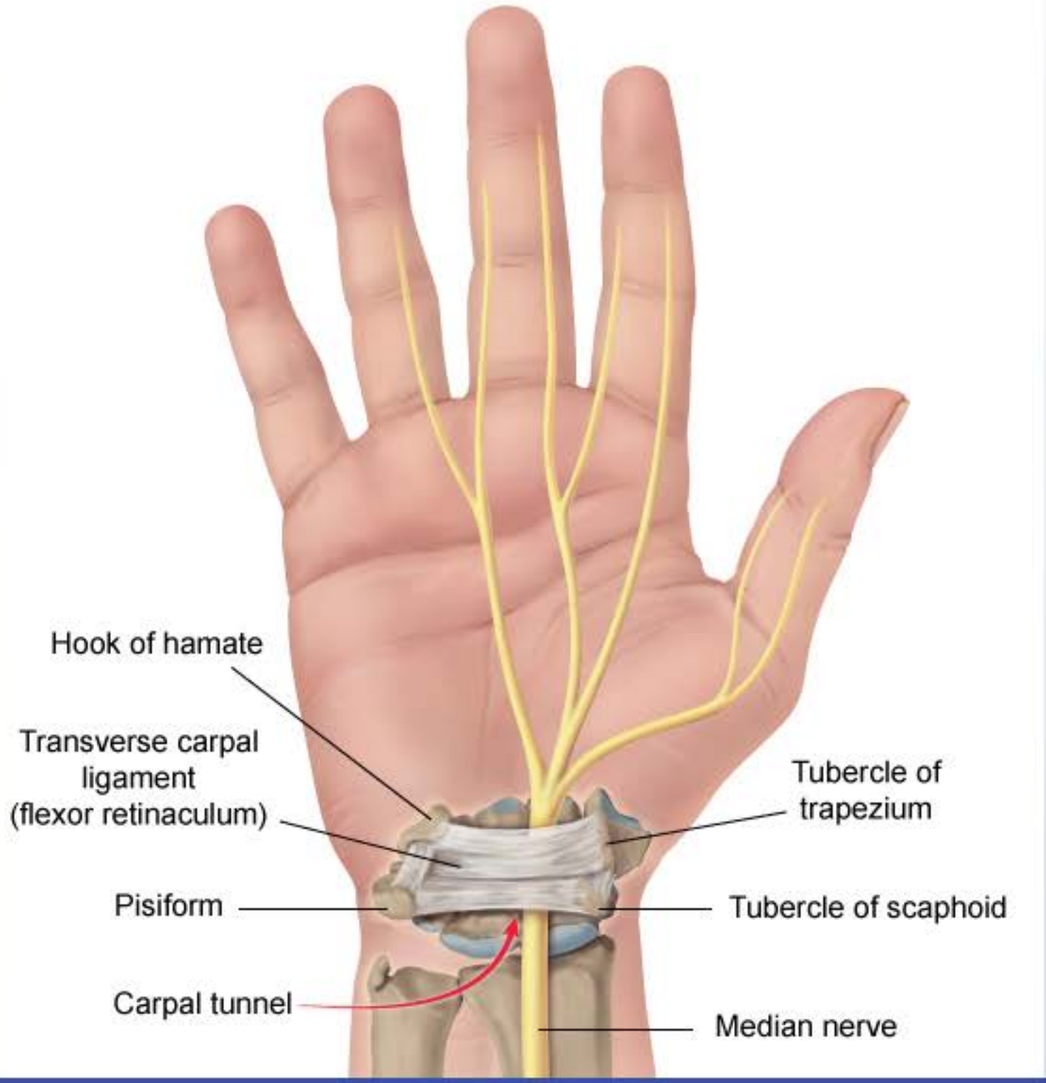

Block Time Remaining: 00:00:46
TUTOR

4 | Feedback | Suspend | End Block

1 2 3 4 5 6 7 8 9 10 11 12 13 14 15 16 17 18 19 20 21 22 23 24 25 26 27 28 29 30

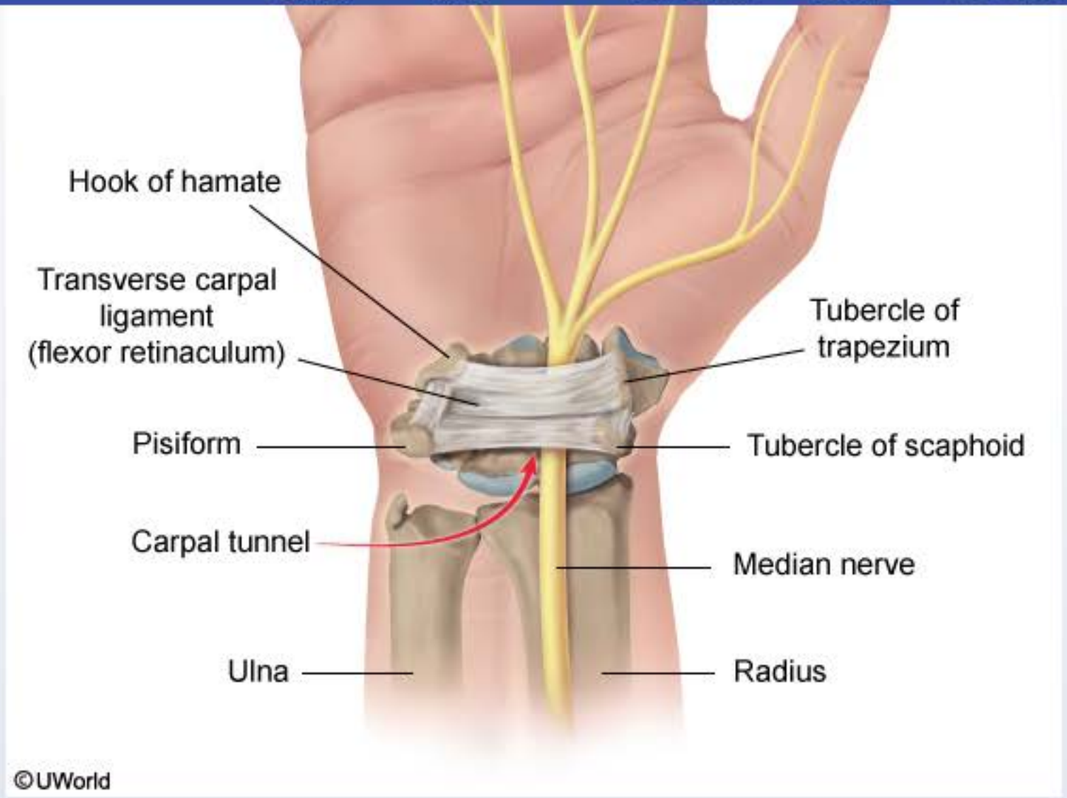

Carpal tunnel syndrome (CTS) is a peripheral mononeuropathy caused by **compression** of the median nerve in the carpal tunnel. The carpal tunnel is an area located on the palmar surface of the wrist (between the carpal bones and transverse carpal ligament) in which the median nerve and tendons of the long flexors of the digits pass through. There is little room for expansion in this anatomical compartment.

CTS is associated with conditions that **reduce carpal tunnel space**, including pregnancy (fluid accumulation), hypothyroidism (glycosaminoglycan buildup), diabetes mellitus (connective tissue thickening), and rheumatoid arthritis (tendon inflammation). Patients with a long history of hemodialysis can also develop median nerve compression through deposition of β2-microglobulin (dialysis-associated amyloidosis) in the carpal tunnel.

©UWorld

Carpal tunnel syndrome (CTS) is a peripheral mononeuropathy caused by **compression** of the median nerve in the carpal tunnel. The carpal tunnel is an area located on the palmar surface of the wrist (between the carpal bones and transverse carpal ligament) in which the median nerve and tendons of the long flexors of the digits pass through. There is little room for expansion in this anatomical compartment.

CTS is associated with conditions that **reduce carpal tunnel space**, including pregnancy (fluid accumulation), hypothyroidism (glycosaminoglycan buildup), diabetes mellitus (connective tissue thickening), and rheumatoid arthritis (tendon inflammation). Patients with a long history of hemodialysis can also develop median nerve compression through deposition of β2-microglobulin (dialysis-associated amyloidosis) in the carpal tunnel.

Symptoms and signs of CTS often occur bilaterally and include:

1. Sensory impairment, pain, and/or paresthesias in the median nerve distribution (palmar surface of the first 3 digits and radial half of the 4th digit). Symptoms are usually worse at night.
2. Motor weakness during thumb abduction/opposition and **thenar atrophy**.
3. **Tinel sign** (tapping over the flexor surface of the wrist reproduces symptoms) and **Phalen sign** (flexion of the wrist reproduces symptoms).

(Choice A) Endomysial inflammatory infiltration is found on muscle biopsy in polymyositis, a myopathy that usually presents with proximal muscle weakness, not distal sensory symptoms as seen in this patient.

(Choice B) Endoneural arteriole hyalinization can occur in diabetes mellitus (diabetic microangiopathy) and most commonly results in a distal, symmetric peripheral polyneuropathy that usually starts in the feet. However, this patient does not have diabetes and her symptoms follow a median nerve distribution, which is more likely due to compressive neuropathy.

(Choice C) Endoneural inflammatory infiltration with multifocal demyelination is seen in Guillain-Barré syndrome, a demyelinating peripheral neuropathy that typically presents with ascending motor weakness. Patients with median nerve compression under the flexor retinaculum have focal, not multifocal, demyelination.

(Choice D) Duchenne muscular dystrophy is an X-linked condition that occurs due to mutation or deletion of the dystrophin gene. It is a

Symptoms and signs of CTS often occur bilaterally and include:

1. Sensory impairment, pain, and/or paresthesias in the median nerve distribution (palmar surface of the first 3 digits and radial half of the 4th digit). Symptoms are usually worse at night.
2. Motor weakness during thumb abduction/opposition and **thenar atrophy**.
3. **Tinel sign** (tapping over the flexor surface of the wrist reproduces symptoms) and **Phalen sign** (flexion of the wrist reproduces symptoms).

(Choice A) Endomysial inflammatory infiltration is found on muscle biopsy in polymyositis, a myopathy that usually presents with proximal muscle weakness, not distal sensory symptoms as seen in this patient.

(Choice B) Endoneural arteriole hyalinization can occur in diabetes mellitus (diabetic microangiopathy) and most commonly results in a distal, symmetric peripheral polyneuropathy that usually starts in the feet. However, this patient does not have diabetes and her symptoms follow a median nerve distribution, which is more likely due to compressive neuropathy.

(Choice C) Endoneural inflammatory infiltration with multifocal demyelination is seen in Guillain-Barré syndrome, a demyelinating peripheral neuropathy that typically presents with ascending motor weakness. Patients with median nerve compression under the flexor retinaculum have focal, not multifocal, demyelination.

(Choice D) Duchenne muscular dystrophy is an X-linked condition that occurs due to mutation or deletion of the dystrophin gene. It is a myopathy that predominantly affects young boys and presents with proximal muscle weakness and pseudohypertrophy of the calves.

Educational objective:
Carpal tunnel syndrome is a peripheral neuropathy characterized by pain/paresthesias in a median nerve distribution (palmar surface of the first 3 digits and radial half of the 4th digit), weakness on thumb abduction/opposition, thenar atrophy, and a positive Tinel and/or Phalen test. It is caused by median nerve compression at the transverse carpal ligament.

References

- Carpal tunnel syndrome.

Settings

1 2 3 4 5 6 7 8 9 10 11 12 13 14 15 16 17 18 19 20 21 22 23 24 25 26 27 28 29 30

Item 18 of 40
Question Id: 1264

Mark | Previous | Next | Full Screen | Tutorial | Lab Values | Notes | Calculator | Reverse Color | Text Zoom | Settings

Exhibit Display

Median nerve

Motor function	Cutaneous innervation
Thumb flexion & opposition, flexion of digits 2 & 3, wrist flexion & abduction, forearm pronation	

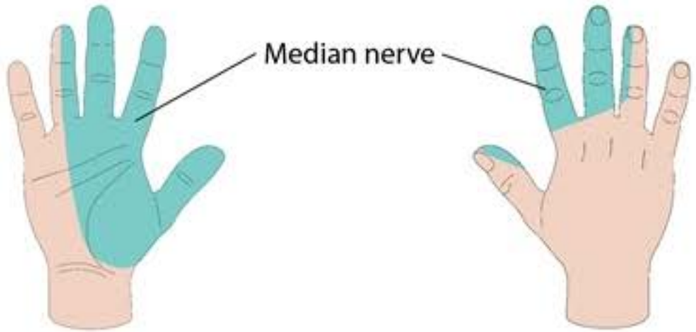

©UWorld

Zoom In | Zoom Out | Reset | Add To New Card | Existing Card

Block Time Remaining: 00:00:46
TUTOR

4 | Feedback | Suspend | End Block

2. Motor weakness during thumb abduction/opposition and **thenar atrophy**.

3. **Tinel sign** (tapping over the flexor surface of the wrist reproduces symptoms) and **Phalen sign** (flexion of the wrist reproduces symptoms).

(Choice A) Endomysial inflammatory infiltration is found on muscle biopsy in polymyositis, a myopathy that usually presents with proximal muscle weakness, not distal sensory symptoms as seen in this patient.

(Choice B) Endoneural arteriole hyalinization can occur in diabetes mellitus (diabetic microangiopathy) and most commonly results in a distal, symmetric peripheral polyneuropathy that usually starts in the feet. However, this patient does not have diabetes and her symptoms follow a median nerve distribution, which is more likely due to compressive neuropathy.

(Choice C) Endoneural inflammatory infiltration with multifocal demyelination is seen in Guillain-Barré syndrome, a demyelinating peripheral neuropathy that typically presents with ascending motor weakness. Patients with median nerve compression under the flexor retinaculum have focal, not multifocal, demyelination.

(Choice D) Duchenne muscular dystrophy is an X-linked condition that occurs due to mutation or deletion of the dystrophin gene. It is a myopathy that predominantly affects young boys and presents with proximal muscle weakness and pseudohypertrophy of the calves.

Educational objective:
Carpal tunnel syndrome is a peripheral neuropathy characterized by pain/paresthesias in a median nerve distribution (palmar surface of the first 3 digits and radial half of the 4th digit), weakness on thumb abduction/opposition, thenar atrophy, and a positive Tinel and/or Phalen test. It is caused by median nerve compression at the transverse carpal ligament.

References

- Carpal tunnel syndrome.

Pathology	Nervous System	Carpal tunnel syndrome
Subject	System	Topic

Copyright © UWorld. All rights reserved.

Settings

1 2 3 4 5 6 7 8 9 10 11 12 13 14 15 16 17 18 19 20 21 22 23 24 25 26 27 28 29 30

Item 19 of 40
Question Id: 22

Mark | Previous | Next | Full Screen | Tutorial | Lab Values | Notes | Calculator | Reverse Color | Text Zoom | Settings

A 58-year-old man comes to the emergency department due to sudden right-sided weakness. He has no sensory loss, problems speaking/swallowing, or difficulty with balance. The patient was previously told that he has elevated blood pressure, but he does not routinely follow up with his physician. He takes no medications. Examination shows intact cranial nerves and sensory function. The patient has 3/5 muscle strength on the right side. Initial CT scan without contrast reveals no abnormalities. Four weeks later, repeat brain imaging shows a 9-mm, fluid-filled cavitary lesion in the left internal capsule. This patient's condition is most likely caused by which of the following?

- A. Cardiac embolism
- B. Carotid artery atherosclerosis
- C. Hypertensive arteriolar sclerosis
- D. Hypertensive encephalopathy
- E. Hypoxic encephalopathy
- F. Saccular aneurysm

Submit

Block Time Remaining: 00:00:46
TUTOR

6 | Feedback | Suspend | End Block

1 2 3 4 5 6 7 8 9 10 11 12 13 14 15 16 17 18 19 20 21 22 23 24 25 26 27 28 29 30

A 58-year-old man comes to the emergency department due to sudden right-sided weakness. He has no sensory loss, problems speaking/swallowing, or difficulty with balance. The patient was previously told that he has elevated blood pressure, but he does not routinely follow up with his physician. He takes no medications. Examination shows intact cranial nerves and sensory function. The patient has 3/5 muscle strength on the right side. Initial CT scan without contrast reveals no abnormalities. Four weeks later, repeat brain imaging shows a 9-mm, fluid-filled cavitary lesion in the left internal capsule. This patient's condition is most likely caused by which of the following?

- A. Cardiac embolism (6%)
- B. Carotid artery atherosclerosis (6%)
- ✓ C. Hypertensive arteriolar sclerosis (54%)
- D. Hypertensive encephalopathy (13%)
- E. Hypoxic encephalopathy (3%)
- F. Saccular aneurysm (16%)

Omitted
Correct answer
C

54%
Answered correctly

01 sec
Time Spent

06/15/2020
Last Updated

Explanation

This patient has pure motor hemiparesis and a small cavitary lesion in the **internal capsule**, characteristic of a **lacunar infarct**. This type of stroke affects the **small penetrating arterioles** that supply the deep brain structures (eg, basal ganglia, pons) and subcortical white matter (eg,

1 2 3 4 5 6 7 8 9 10 11 12 13 14 15 16 17 18 19 20 21 22 23 24 25 26 27 28 29 30

This patient has pure motor hemiparesis and a small cavitary lesion in the **internal capsule**, characteristic of a **lacunar infarct**. This type of stroke affects the **small penetrating arterioles** that supply the deep brain structures (eg, basal ganglia, pons) and subcortical white matter (eg, internal capsule, corona radiata). Lacunar infarcts are primarily associated with chronic hypertension, which promotes lipohyalinosis, microatheroma formation, and hardening/thickening of the vessel wall **(hypertensive arteriolar sclerosis)**. This leads to progressive narrowing of the arteriolar lumen and predisposes to thrombotic vessel occlusion, which causes characteristic clinical syndromes, depending on the portion of the brain affected:

- Posterior limb of the internal capsule and/or basal pons - **pure motor hemiparesis** or ataxia-hemiplegia syndrome (ie, ipsilateral limb ataxia out of proportion to motor deficit)
- Genu/anterior limb of the internal capsule and/or basal pons - dysarthria-clumsy hand syndrome (ie, dysarthria and dysphagia with clumsiness of one hand)
- Ventroposterolateral or ventroposteromedial thalamus - pure sensory stroke

In the acute setting, CT imaging may not reveal the expected hypodensity of ischemic stroke due to the **small infarct size** (usually <15 mm). After several weeks, these necrotic lesions turn into cavitary spaces filled with cerebrospinal fluid and surrounded by scar tissue called lacunas.

(Choices A and B) Cardiac embolism and carotid artery atherosclerosis usually result in occlusion of medium to large cerebral vessels (eg, middle cerebral artery), causing large-territory ischemic infarctions of the cerebral cortex evident on CT scan as large areas of hypodensity.

(Choice D) Hypertensive encephalopathy is characterized by progressive headache and nausea/vomiting followed by nonlocalizing neurologic symptoms (eg, confusion). Cerebral imaging may be normal or show parietooccipital white matter edema.

(Choice E) Hypoxic encephalopathy occurs from global interruption of the cerebral blood supply (eg, due to cardiac arrest). It commonly presents with decreased consciousness (eg, coma, vegetative state) as opposed to focal neurologic deficits. Cerebral imaging may show watershed infarcts at the border of perfusion zones between the major cerebral arteries.

(Choice F) Saccular aneurysm rupture is associated with subarachnoid hemorrhage. Patients usually have abrupt onset of severe headache,

Settings

1 2 3 4 5 6 7 8 9 10 11 12 13 14 15 16 17 18 19 20 21 22 23 24 25 26 27 28 29 30

Item 19 of 40
Question Id: 22

Mark | Previous | Next | Full Screen | Tutorial | Lab Values | Notes | Calculator | Reverse Color | Text Zoom | Settings

Exhibit Display

Internal capsule

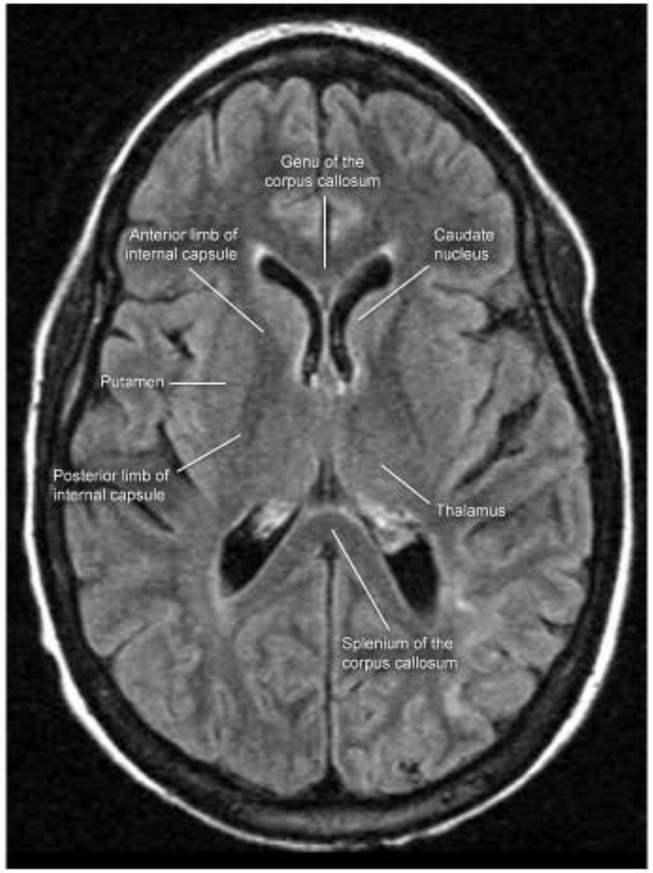

Zoom In | Zoom Out | Reset | Add To New Card | Existing Card

Block Time Remaining: 00:00:47
TUTOR

6 | Feedback | Suspend | End Block

Settings

1 2 3 4 5 6 7 8 9 10 11 12 13 14 15 16 17 18 19 20 21 22 23 24 25 26 27 28 29 30

Item 19 of 40
Question Id: 22

Mark | Previous | Next | Full Screen | Tutorial | Lab Values | Notes | Calculator | Reverse Color | Text Zoom | Settings

This patient has pure motor hemiparesis and a small cavitary lesion in the **internal capsule**, characteristic of a **lacunar infarct**. This type of

Exhibit Display

Chronic left corona radiata ischemic infarct

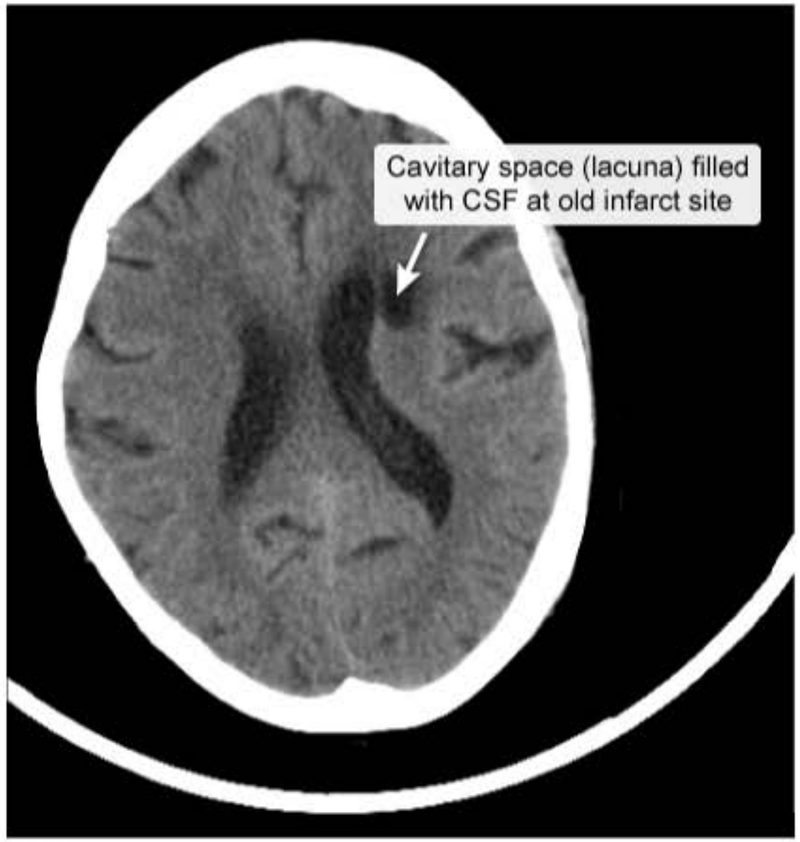

Zoom In | Zoom Out | Reset | Add To New Card | Existing Card

Educational objective:

Block Time Remaining: 00:00:47
TUTOR

6 | Feedback | Suspend | End Block

1
2
3
4
5
6
7
8
9
10
11
12
13
14
15
16
17
18
19
20
21
22
23
24
25
26
27
28
29
30

- Ventroposterolateral or ventroposteromedial thalamus - pure sensory stroke

Exhibit Display

Subarachnoid hemorrhage

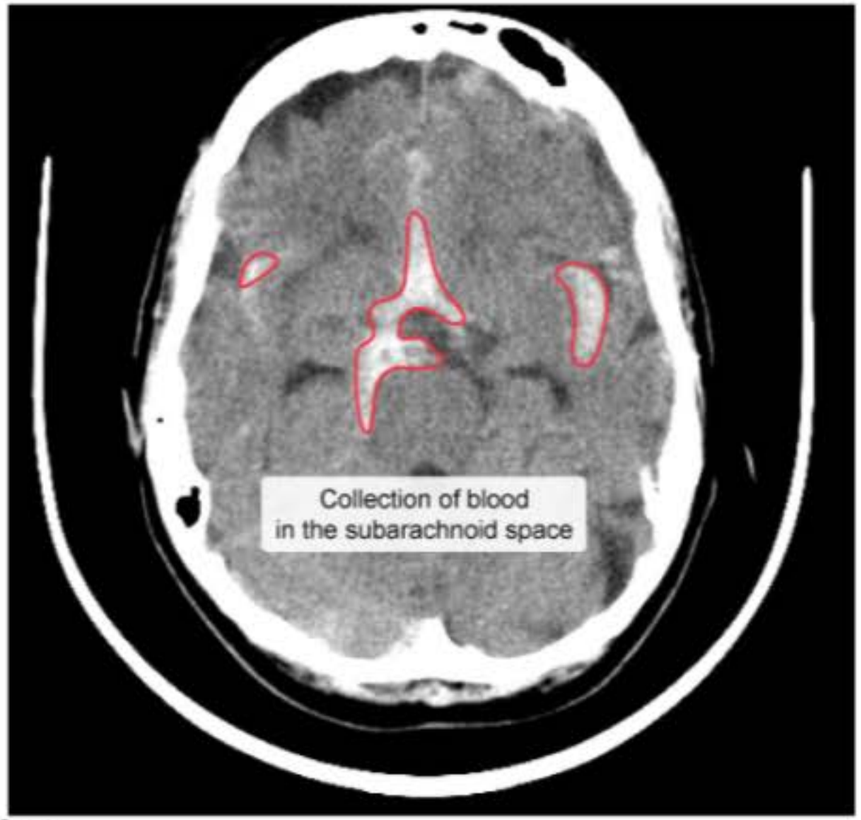

©UWorld

Zoom In | Zoom Out | Reset | Add To New Card | Existing Card

Settings

1 2 3 4 5 6 7 8 9 10 11 12 13 14 15 16 17 18 19 20 21 22 23 24 25 26 27 28 29 30

Item 20 of 40
Question Id: 906

Mark | Previous | Next | Full Screen | Tutorial | Lab Values | Notes | Calculator | Reverse Color | Text Zoom | Settings

A 44-year-old man comes to the office due to several weeks of difficulty walking and frequent falls. He has had no headache or visual impairment but reports episodes of sharp, stabbing pain in his extremities. The patient has HIV acquired from unprotected sexual contact and is nonadherent with treatments. Temperature is 37 C (98.6 F). Neurologic examination shows 5/5 motor power in all extremities. Deep-tendon reflexes are absent at the knee and ankle bilaterally. Proprioception and vibration sensation are reduced throughout the lower extremities. He has a wide-based gait and a positive Romberg sign. Which of the following diagnostic findings is most likely associated with this patient's current symptoms?

A. Cerebrospinal fluid (CSF) culture growing acid-fast bacilli

B. CSF PCR positive for herpes virus

C. Encapsulated yeasts on CSF India ink preparation

D. Polyomavirus-infected glial cells on brain biopsy

E. Reactive VDRL tests on CSF samples

F. Ring-enhancing lesions on brain MRI

Submit

Block Time Remaining: 00:00:47
TUTOR

3 | Feedback | Suspend | End Block

1 2 3 4 5 6 7 8 9 10 11 12 13 14 15 16 17 18 19 20 21 22 23 24 25 26 27 28 29 30

A 44-year-old man comes to the office due to several weeks of difficulty walking and frequent falls. He has had no headache or visual impairment but reports episodes of sharp, stabbing pain in his extremities. The patient has HIV acquired from unprotected sexual contact and is nonadherent with treatments. Temperature is 37 C (98.6 F). Neurologic examination shows 5/5 motor power in all extremities. Deep-tendon reflexes are absent at the knee and ankle bilaterally. Proprioception and vibration sensation are reduced throughout the lower extremities. He has a wide-based gait and a positive Romberg sign. Which of the following diagnostic findings is most likely associated with this patient's current symptoms?

- A. Cerebrospinal fluid (CSF) culture growing acid-fast bacilli (2%)
- B. CSF PCR positive for herpes virus (3%)
- C. Encapsulated yeasts on CSF India ink preparation (4%)
- D. Polyomavirus-infected glial cells on brain biopsy (13%)
- ✓ E. Reactive VDRL tests on CSF samples (65%)
- F. Ring-enhancing lesions on brain MRI (10%)

Omitted
Correct answer
E

65%
Answered correctly

02 secs
Time Spent

02/07/2020
Last Updated

Explanation

Features of tabes dorsalis	

Features of tabes dorsalis	
Epidemiology	• Increased incidence of syphilis in men who have sex with men & HIV-infected patients • HIV-positive patients develop neurosyphilis more rapidly
Pathogenesis	• *Treponema pallidum* spirochetes directly damage the dorsal sensory roots • Secondary degeneration of the dorsal columns
Clinical findings	• Sensory ataxia • Lancinating pains • Neurogenic urinary incontinence • Associated with Argyll Robertson pupils

This patient's sensory ataxia and lancinating pains raises suspicion for **tabes dorsalis**, a late form of **neurosyphilis** that usually manifests several years or decades after initial infection with *Treponema pallidum*. Tabes dorsalis is characterized by a slow degeneration of nerve fibers in the **dorsal column** of the spinal cord and **dorsal nerve roots**, which leads to diminished vibratory, proprioception, and discriminative touch sensation.

Common manifestations include:

- **Sensory ataxia**: Wide-based gait and loss of equilibrium when the patient's eyes are closed (positive Romberg sign); due to damaged lower extremity proprioception
- Absent deep-tendon reflexes: Due to damaged dorsal nerve roots
- **Lancinating pains**: Sharp, stabbing pains that may last minutes or hours; the exact cause is unclear

Spirochetal damage to the midbrain tectum also commonly results in **Argyll Robertson pupil**. This finding is marked by small, irregularly shaped pupils that fail to constrict to light but that constrict normally to accommodation (light-near dissociation). Most patients with tertiary syphilis will have a **positive VDRL** and mild lymphocytic pleocytosis on cerebrospinal fluid analysis.

(Choice A) Central nervous system infection with *Mycobacterium tuberculosis*, an acid-fast bacillus, is usually characterized by headache,

1
2
3
4
5
6
7
8
9
10
11
12
13
14
15
16
17
18
19
20
21
22
23
24
25
26
27
28
29
30

This patient's sensory ataxia and lancinating pains raises suspicion for **tabes dorsalis**, a late form of **neurosyphilis** that usually manifests several years or decades after initial infection with *Treponema pallidum*. Tabes dorsalis is characterized by a slow degeneration of nerve fibers in the **dorsal column** of the spinal cord and **dorsal nerve roots**, which leads to diminished vibratory, proprioception, and discriminative touch sensation.

Common manifestations include:

- **Sensory ataxia**: Wide-based gait and loss of equilibrium when the patient's eyes are closed (positive Romberg sign); due to damaged lower extremity proprioception
- Absent deep-tendon reflexes: Due to damaged dorsal nerve roots
- **Lancinating pains**: Sharp, stabbing pains that may last minutes or hours; the exact cause is unclear

Spirochetal damage to the midbrain tectum also commonly results in **Argyll Robertson pupil**. This finding is marked by small, irregularly shaped pupils that fail to constrict to light but that constrict normally to accommodation (light-near dissociation). Most patients with tertiary syphilis will have a **positive VDRL** and mild lymphocytic pleocytosis on cerebrospinal fluid analysis.

(Choice A) Central nervous system infection with *Mycobacterium tuberculosis*, an acid-fast bacillus, is usually characterized by headache, vomiting, cranial nerve deficits, and confusion. Lancinating pains and altered lower extremity sensation would be atypical.

(Choice B) Herpes simplex encephalitis primarily affects the temporal lobe and causes fever, headache, impaired consciousness, and seizures.

(Choice C) Cryptococcal meningitis can be diagnosed by examining the cerebrospinal fluid for encapsulated yeasts using India ink. However, cryptococcal meningitis usually manifests with fever, malaise, and headache. Lancinating pains, absent deep-tendon reflexes, and altered sensation would be atypical.

(Choice D) JC virus is a polyomavirus that replicates in oligodendrocytes (glial cells). Reactivation of JC virus causes progressive multifocal leukoencephalopathy, which occurs primarily in severely immunocompromised patients (eg, AIDS, lymphoma, leukemia) and causes progressive dementia, motor deficits, and visual impairment.

(Choice F) Patients with untreated HIV are at high risk for cerebral toxoplasmosis, which usually manifests with headache, confusion, fever, and

- Absent deep-tendon reflexes: Due to damaged dorsal nerve roots
- **Lancinating pains**: Sharp, stabbing pains that may last minutes or hours; the exact cause is unclear

Spirochetal damage to the midbrain tectum also commonly results in **Argyll Robertson pupil**. This finding is marked by small, irregularly shaped pupils that fail to constrict to light but that constrict normally to accommodation (light-near dissociation). Most patients with tertiary syphilis will have a **positive VDRL** and mild lymphocytic pleocytosis on cerebrospinal fluid analysis.

(Choice A) Central nervous system infection with *Mycobacterium tuberculosis*, an acid-fast bacillus, is usually characterized by headache, vomiting, cranial nerve deficits, and confusion. Lancinating pains and altered lower extremity sensation would be atypical.

(Choice B) Herpes simplex encephalitis primarily affects the temporal lobe and causes fever, headache, impaired consciousness, and seizures.

(Choice C) Cryptococcal meningitis can be diagnosed by examining the cerebrospinal fluid for encapsulated yeasts using India ink. However, cryptococcal meningitis usually manifests with fever, malaise, and headache. Lancinating pains, absent deep-tendon reflexes, and altered sensation would be atypical.

(Choice D) JC virus is a polyomavirus that replicates in oligodendrocytes (glial cells). Reactivation of JC virus causes progressive multifocal leukoencephalopathy, which occurs primarily in severely immunocompromised patients (eg, AIDS, lymphoma, leukemia) and causes progressive dementia, motor deficits, and visual impairment.

(Choice F) Patients with untreated HIV are at high risk for cerebral toxoplasmosis, which usually manifests with headache, confusion, fever, and focal neurologic deficits. MRI of the brain usually reveals ring-enhancing lesions.

Educational objective:
Tabes dorsalis, a late form of neurosyphilis, causes progressive degeneration of the dorsal columns and dorsal roots of the spinal cord. Manifestations include loss of proprioception and vibratory sensation, severe lancinating pains, and sensory ataxia (eg, wide-based gait, positive Romberg sign). Many patients also have Argyll Robertson pupils.

References

- REVIEW: Neurosyphilis: a historical perspective and review.

Settings

1 2 3 4 5 6 7 8 9 10 11 12 13 14 15 16 17 18 19 20 21 22 23 24 25 26 27 28 29 30

Item 21 of 40
Question Id: 505

Mark | Previous | Next | Full Screen | Tutorial | Lab Values | Notes | Calculator | Reverse Color | Text Zoom | Settings

A 23-year-old, previously healthy man was involved in a motor vehicle collision. He lost consciousness at the scene but recovered by the time emergency medical services arrived. The patient was alert and awake in the ambulance but lost consciousness again soon after arriving at the emergency department. His breath smells of alcohol. Blood pressure is 130/90 mm Hg, pulse is 68/min, and respirations are 12/min. A bruise is noted over the left temple area. The left pupil is mildly dilated. Brain imaging would most likely reveal blood accumulating between which of the following tissues?

- A. Aponeurosis and outer periosteum
- B. Arachnoid mater and pia mater
- C. Bone and dura mater
- D. Dura mater and arachnoid mater
- E. Pia mater and brain surface

Submit

Block Time Remaining: 00:00:50
TUTOR

3 | Feedback | Suspend | End Block

1 2 3 4 5 6 7 8 9 10 11 12 13 14 15 16 17 18 19 20 21 22 23 24 25 26 27 28 29 30

A 23-year-old, previously healthy man was involved in a motor vehicle collision. He lost consciousness at the scene but recovered by the time emergency medical services arrived. The patient was alert and awake in the ambulance but lost consciousness again soon after arriving at the emergency department. His breath smells of alcohol. Blood pressure is 130/90 mm Hg, pulse is 68/min, and respirations are 12/min. A bruise is noted over the left temple area. The left pupil is mildly dilated. Brain imaging would most likely reveal blood accumulating between which of the following tissues?

- A. Aponeurosis and outer periosteum (1%)
- B. Arachnoid mater and pia mater (5%)
- ✓ C. Bone and dura mater (78%)
- D. Dura mater and arachnoid mater (12%)
- E. Pia mater and brain surface (2%)

Omitted
Correct answer
C

78%
Answered correctly

03 secs
Time Spent

07/06/2020
Last Updated

Explanation

Intracranial hemorrhage			
	Epidural hematoma	Subdural hematoma	Subarachnoid hemorrhage

Explanation

Intracranial hemorrhage			
	Epidural hematoma	**Subdural hematoma**	**Subarachnoid hemorrhage**
Vessel typically involved	Middle meningeal artery	Bridging cortical veins	Aneurysm or arteriovenous malformation of anterior or posterior communicating arteries or MCA
Location	Between skull & dura mater	Between dura mater & arachnoid mater	Between arachnoid mater & pia mater
Clinical manifestation	Lucid interval, followed by loss of consciousness	Acute: coma at onset Chronic: gradual onset of headache and confusion	Severe headache ("worst headache of my life"), nuchal rigidity
Presentation on CT scan	Biconvex hematoma	Crescent-shaped hematoma	Blood in the basal cisterns

MCA= middle cerebral artery.

Epidural hematoma is an accumulation of blood between the **skull bone and dura mater**. Most cases are due to fracture of the pterion region of the skull (often involving the temporal bone with associated scalp contusion) and a subsequent rupture or tear of the **middle meningeal artery**.

Epidural hematoma characteristically results in **transient loss of consciousness** at the time of impact followed by a **lucid period** in which the patient regains consciousness. However, the eventual expansion of the hematoma results in elevated intracranial pressure (ICP) and can lead to brain herniation, coma, and death. Signs of **elevated ICP** include altered mental status, nausea/vomiting, and Cushing reflex (ie, bradycardia, irregular breathing, hypertension). An **ipsilateral dilated pupil** can also occur due to uncal herniation and oculomotor nerve compression.

The diagnosis is confirmed with a noncontrast CT scan demonstrating a hyperdense, **biconvex** (lens-shaped) mass between the brain and skull

1 2 3 4 5 6 7 8 9 10 11 12 13 14 15 16 17 18 19 20 21 22 23 24 25 26 27 28 29 30

MCA= middle cerebral artery.

Epidural hematoma is an accumulation of blood between the **skull bone and dura mater**. Most cases are due to fracture of the pterion region of the skull (often involving the temporal bone with associated scalp contusion) and a subsequent rupture or tear of the **middle meningeal artery**.

Epidural hematoma characteristically results in **transient loss of consciousness** at the time of impact followed by a **lucid period** in which the patient regains consciousness. However, the eventual expansion of the hematoma results in elevated intracranial pressure (ICP) and can lead to brain herniation, coma, and death. Signs of **elevated ICP** include altered mental status, nausea/vomiting, and Cushing reflex (ie, bradycardia, irregular breathing, hypertension). An **ipsilateral dilated pupil** can also occur due to uncal herniation and oculomotor nerve compression.

The diagnosis is confirmed with a noncontrast CT scan demonstrating a hyperdense, **biconvex** (lens-shaped) mass between the brain and skull. Epidural hematomas do not cross suture lines due to the tight adherence of the dura to the calvarium at these points.

(Choice A) The epicranial aponeurosis (galea aponeurotica) and outer periosteum cover the exterior surface of cranial bones. Intracranial hemorrhages are located inside the cranial vault.

(Choice B) Subarachnoid hemorrhage results in blood accumulation between the arachnoid mater and pia mater. It most often occurs due to rupture of berry aneurysms or arteriovenous malformations of the anterior communicating, posterior communicating, or middle cerebral arteries. Patients typically have severe headache and nuchal rigidity.

(Choice D) Subdural hematoma (SDH) is located between the dura mater and arachnoid mater and results from tearing of the bridging cortical veins. It typically presents in older patients with profoundly depressed mental status at onset (acute SDH) or an insidious onset of headache and confusion (chronic SDH)

(Choice E) The pia mater is closely adherent to the brain surface and does not form a space for accumulation of blood.

Educational objective:
Epidural hematoma is an accumulation of blood between the bone and dura mater. It typically occurs due to a tear of the middle meningeal artery associated with fracture of the pterion region of the skull (often involving the temporal bone). Patients characteristically have transient loss of consciousness followed by a lucid interval before increasing intracranial pressure leads to neurologic deterioration.

1 2 3 4 5 6 7 8 9 10 11 12 13 14 15 16 17 18 19 20 21 22 23 24 25 26 27 28 29 30

patient regains consciousness. However, the eventual expansion of the hematoma results in elevated intracranial pressure (ICP) and can lead to brain herniation, coma, and death. Signs of **elevated ICP** include altered mental status, nausea/vomiting, and Cushing reflex (ie, bradycardia, irregular breathing, hypertension). An **ipsilateral dilated pupil** can also occur due to uncal herniation and oculomotor nerve compression.

The diagnosis is confirmed with a noncontrast CT scan demonstrating a hyperdense, **biconvex** (lens-shaped) mass between the brain and skull. Epidural hematomas do not cross suture lines due to the tight adherence of the dura to the calvarium at these points.

(Choice A) The epicranial aponeurosis (galea aponeurotica) and outer periosteum cover the exterior surface of cranial bones. Intracranial hemorrhages are located inside the cranial vault.

(Choice B) Subarachnoid hemorrhage results in blood accumulation between the arachnoid mater and pia mater. It most often occurs due to rupture of berry aneurysms or arteriovenous malformations of the anterior communicating, posterior communicating, or middle cerebral arteries. Patients typically have severe headache and nuchal rigidity.

(Choice D) Subdural hematoma (SDH) is located between the dura mater and arachnoid mater and results from tearing of the bridging cortical veins. It typically presents in older patients with profoundly depressed mental status at onset (acute SDH) or an insidious onset of headache and confusion (chronic SDH)

(Choice E) The pia mater is closely adherent to the brain surface and does not form a space for accumulation of blood.

Educational objective:
Epidural hematoma is an accumulation of blood between the bone and dura mater. It typically occurs due to a tear of the middle meningeal artery associated with fracture of the pterion region of the skull (often involving the temporal bone). Patients characteristically have transient loss of consciousness followed by a lucid interval before increasing intracranial pressure leads to neurologic deterioration.

Pathology	Nervous System	Epidural hematoma
Subject	System	Topic

Copyright © UWorld. All rights reserved.

Settings

1 2 3 4 5 6 7 8 9 10 11 12 13 14 15 16 17 18 19 20 21 22 23 24 25 26 27 28 29 30

Item 21 of 40
Question Id: 505

Mark | Previous | Next | Full Screen | Tutorial | Lab Values | Notes | Calculator | Reverse Color | Text Zoom | Settings

Lucid interval, followed by loss of | Acute: coma at onset | Severe headache ("worst headache of

Exhibit Display

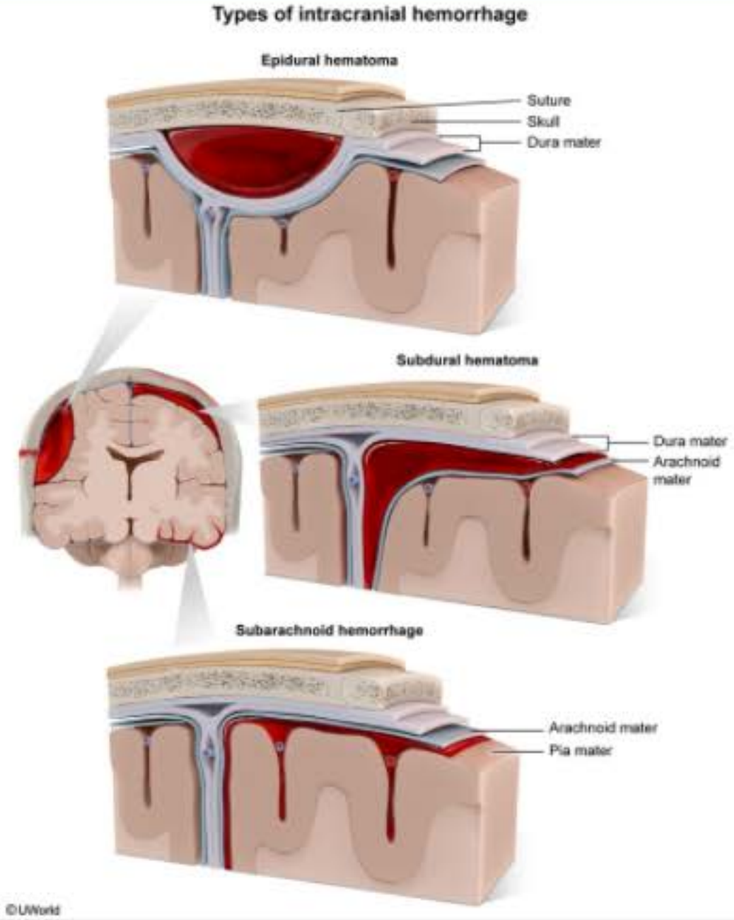

Zoom In | Zoom Out | Reset | Add To New Card | Existing Card

(Choice E) The pia mater is closely adherent to the brain surface and does not form a space for accumulation of blood

Block Time Remaining: 00:00:52
TUTOR

3 | Feedback | Suspend | End Block

Settings

1 2 3 4 5 6 7 8 9 10 11 12 13 14 15 16 17 18 19 20 21 22 23 24 25 26 27 28 29 30

Item 22 of 40
Question Id: 1259

Mark | Previous | Next | Full Screen | Tutorial | Lab Values | Notes | Calculator | Reverse Color | Text Zoom | Settings

A 5-year-old Caucasian boy is brought to the physician's office with recent-onset gait instability and gait ataxia. MRI of the brain shows a midline posterior fossa mass. Biopsy of the mass reveals sheets of primitive cells and many mitotic figures. This patient most likely suffers from which of the following?

A. Pilocytic astrocytoma
B. Glioblastoma
C. Oligodendroglioma
D. Ependymoma
E. Medulloblastoma
F. Primary CNS lymphoma
G. Meningioma
H. Craniopharyngioma
I. Schwannoma
J. Pituitary adenoma

Submit

Block Time Remaining: 00:00:53
TUTOR

1 | Feedback | Suspend | End Block

Settings

1 2 3 4 5 6 7 8 9 10 11 12 13 14 15 16 17 18 19 20 21 22 23 24 25 26 27 28 29 30

Item 22 of 40
Question Id: 1259

Mark | Previous | Next | Full Screen | Tutorial | Lab Values | Notes | Calculator | Reverse Color | Text Zoom | Settings

A 5-year-old Caucasian boy is brought to the physician's office with recent-onset gait instability and gait ataxia. MRI of the brain shows a midline posterior fossa mass. Biopsy of the mass reveals sheets of primitive cells and many mitotic figures. This patient most likely suffers from which of the following?

- A. Pilocytic astrocytoma (20%)
- B. Glioblastoma (4%)
- C. Oligodendroglioma (1%)
- D. Ependymoma (4%)
- ✓ E. Medulloblastoma (60%)
- F. Primary CNS lymphoma (0%)
- G. Meningioma (1%)
- H. Craniopharyngioma (5%)
- I. Schwannoma (0%)
- J. Pituitary adenoma (0%)

Omitted
Correct answer
E

60%
Answered correctly

02 secs
Time Spent

02/03/2020
Last Updated

Block Time Remaining: 00:00:54
TUTOR

Feedback | Suspend | End Block

Explanation

Gait instability and limb ataxia are symptoms of cerebellar involvement. The mass described indicates that a brain tumor is causing the cerebellar symptoms in this child. Because both pilocytic astrocytomas and medulloblastomas arise in the cerebellum, microscopic findings must be relied on to determine which type of tumor this patient has. Sheets of primitive cells with many mitotic figures described in the vignette indicate a medulloblastoma, not a pilocytic astrocytoma. Medulloblastomas are part of a group called "primitive neuroectodermal tumors" (PNETs). PNETs are composed of sheets of small cells with deeply basophilic nuclei and scant cytoplasm (small, round, blue cells). Abundant mitoses are also seen. Medulloblastomas are undifferentiated and aggressive tumors.

The cerebellar vermis is the most common location of a medulloblastoma. Symptoms include signs of **increased intracranial pressure** (morning headaches, vomiting, and lethargy). **Cerebellar dysfunction** occurs as the tumor compresses adjacent structures.

(Choice A) Pilocytic astrocytoma is the most common brain neoplasm of childhood. Although both pilocytic astrocytomas and medulloblastomas are often located in the cerebellum, they can be differentiated by histology. On microscopic examination of a pilocytic astrocytoma, pilocytic astrocytes and Rosenthal fibers are seen. Pilocytic astrocytomas are low-grade tumors and have a better prognosis than medulloblastomas.

(Choice D) Ependymomas are the third most common brain neoplasm found in children. They arise in the walls of the ventriculi and can hamper CSF flow and cause hydrocephalus. On microscopic examination, ependymal cells form gland-like structures called "rosettes."

Educational Objective:
Medulloblastoma is the second most common brain neoplasm of childhood. It is located in the cerebellum, often at the vermis, and consists of sheets of small, blue cells. Like other "PNET" tumors, medulloblastomas are poorly differentiated and have a bad prognosis.

Pathology	Nervous System	Brain tumors
Subject	System	Topic

Copyright © UWorld. All rights reserved.

Settings

1 2 3 4 5 6 7 8 9 10 11 12 13 14 15 16 17 18 19 20 21 22 23 24 25 26 27 28 29 30

Item 23 of 40
Question Id: 15866

Mark | Previous | Next | Full Screen | Tutorial | Lab Values | Notes | Calculator | Reverse Color | Text Zoom | Settings

A 38-year-old woman comes to the emergency department due to severe headache. An hour ago, she experienced a sudden, explosive headache followed by a brief loss of consciousness. Since regaining consciousness spontaneously, she has had persistent global headache and nausea. Head movement or bright light worsens the pain. Temperature is 37.2 C (99 F), blood pressure is 142/90 mm Hg, and pulse is 98/min. The patient is somnolent but easily rouses to voice. She is well oriented to time, place, and person. There is increased resistance to neck flexion, which elicits pain. The pupils are equal and reactive to light. Deep tendon reflexes and sensory examination are normal. Brain imaging would most likely reveal which of the following?

A. Blood layering the cerebral sulci

B. Diffuse cerebral edema

C. Intracerebral hemorrhage

D. Large vessel thrombosis

E. Scattered cerebral emboli

Submit

Block Time Remaining: 00:00:55
TUTOR

0 | Feedback | Suspend | End Block

Settings

1 2 3 4 5 6 7 8 9 10 11 12 13 14 15 16 17 18 19 20 21 22 23 24 25 26 27 28 29 30

Item 23 of 40
Question Id: 15866

Mark | Previous | Next | Full Screen | Tutorial | Lab Values | Notes | Calculator | Reverse Color | Text Zoom | Settings

A 38-year-old woman comes to the emergency department due to severe headache. An hour ago, she experienced a sudden, explosive headache followed by a brief loss of consciousness. Since regaining consciousness spontaneously, she has had persistent global headache and nausea. Head movement or bright light worsens the pain. Temperature is 37.2 C (99 F), blood pressure is 142/90 mm Hg, and pulse is 98/min. The patient is somnolent but easily rouses to voice. She is well oriented to time, place, and person. There is increased resistance to neck flexion, which elicits pain. The pupils are equal and reactive to light. Deep tendon reflexes and sensory examination are normal. Brain imaging would most likely reveal which of the following?

- ✓ A. Blood layering the cerebral sulci (58%)
- B. Diffuse cerebral edema (9%)
- C. Intracerebral hemorrhage (29%)
- D. Large vessel thrombosis (2%)
- E. Scattered cerebral emboli (0%)

Omitted
Correct answer
A

58%
Answered correctly

02 secs
Time Spent

02/19/2020
Last Updated

Explanation

Types of intracranial hemorrhage

Block Time Remaining: 00:00:56
TUTOR

0 | Feedback | Suspend | End Block

Settings

Item 23 of 40
Question Id: 15866

Mark | Previous | Next | Full Screen | Tutorial | Lab Values | Notes | Calculator | Reverse Color | Text Zoom | Settings

Types of intracranial hemorrhage

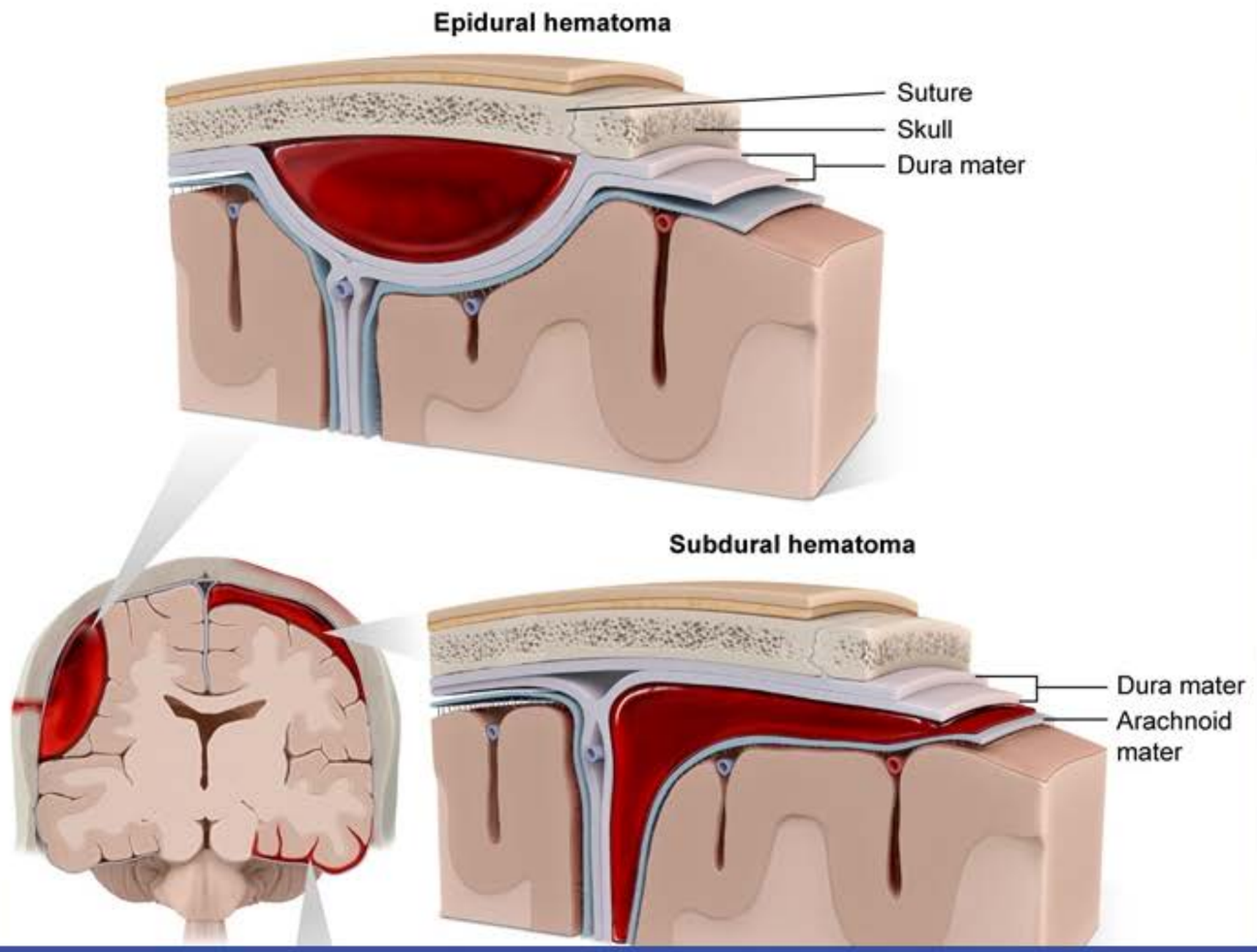

Block Time Remaining: 00:00:56
TUTOR

0 | Feedback | Suspend | End Block

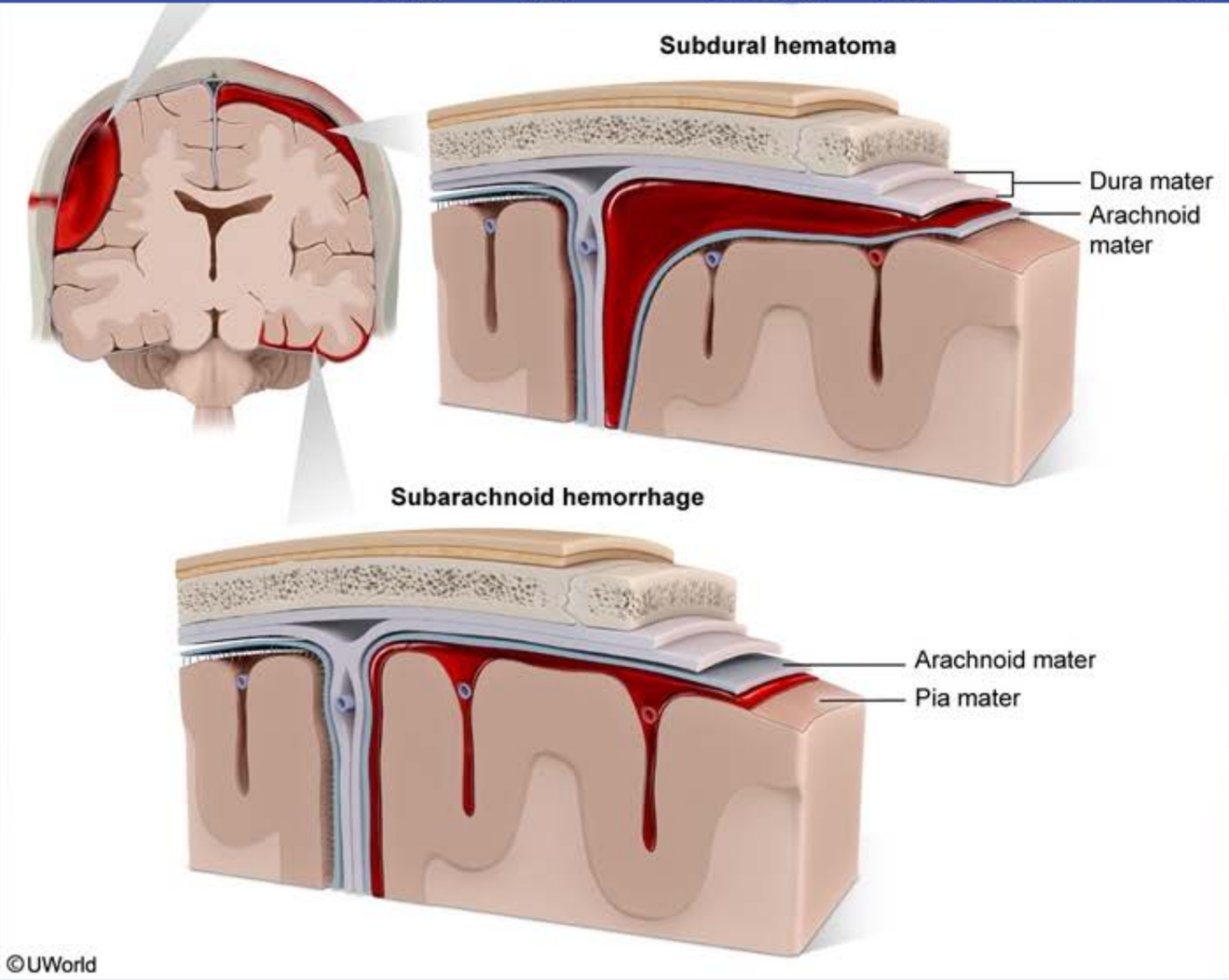

This patient with a sudden-onset, explosive headache (ie, **thunderclap headache**), brief loss of consciousness, and signs of **meningeal irritation** (eg, neck stiffness, pain) likely has a **subarachnoid hemorrhage** (SAH). SAH usually results from the spontaneous rupture of a **saccular (berry)**

This patient with a sudden-onset, explosive headache (ie, **thunderclap headache**), brief loss of consciousness, and signs of **meningeal irritation** (eg, neck stiffness, pain) likely has a **subarachnoid hemorrhage** (SAH). SAH usually results from the spontaneous rupture of a **saccular (berry) aneurysm**. These aneurysms most commonly develop at branch points of the anterior, middle, or posterior cerebral arteries in patients with a genetic predisposition (eg, family history, autosomal dominant polycystic kidney disease, Ehlers-Danlos syndrome). Blood empties into the subarachnoid space and **pools in the cerebral sulci and basal cisterns**, which is the diagnostic finding of SAH on CT scan.

Blood in direct contact with the pia mater triggers severe headache and meningeal irritation. Nausea, photophobia, and transient loss of consciousness are also common. Many patients appear neurologically intact at presentation; however, progressively **deteriorating mental status** (eg, somnolence) is typical. In addition, SAH commonly triggers delayed cerebral vasospasm (eg, 4 days after initial bleeding) resulting in stroke with focal neurologic deficits.

(Choice B) Diffuse cerebral edema can result from too-rapid correction of hypernatremia. The drop in serum osmolarity stimulates water flow into brain cells, which can increase intracranial pressure to cause impaired cerebral perfusion and eventual brain herniation.

(Choice C) Intracerebral hemorrhage usually results from the rupture of small arteries in the pons, thalamus, or basal ganglia, commonly in the setting of underlying hypertensive vasculopathy. The hemorrhage occurs within the brain parenchyma, with patients usually experiencing focal neurologic deficits. Severe headache is sometimes present, but meningeal signs are not expected.

(Choices D and E) Plaque rupture and thrombosis of a large cerebral artery (eg, anterior cerebral artery) and embolization of thrombus (eg, cardioembolic thrombus due to atrial fibrillation) are common mechanisms of ischemic stroke. Patients usually have focal neurologic deficits without headache or meningeal signs.

Educational objective:
Sudden-onset, severe headache with signs of meningeal irritation (eg, neck pain, stiffness) should raise suspicion for subarachnoid hemorrhage (SAH). SAH usually results from rupture of a saccular (berry) aneurysm, and it is recognized on CT scan by blood pooling in the cerebral sulci and basal cisterns.

Pathology	Nervous System	Subarachnoid hemorrhage
Subject	System	Topic

Settings

1 2 3 4 5 6 7 8 9 10 11 12 13 14 15 16 17 18 19 20 21 22 23 24 25 26 27 28 29 30

Item 23 of 40
Question Id: 15866

Mark | Previous | Next | Full Screen | Tutorial | Lab Values | Notes | Calculator | Reverse Color | Text Zoom | Settings

This patient with a sudden-onset, explosive headache (ie, **thunderclap headache**), brief loss of consciousness, and signs of **meningeal irritation**

Exhibit Display

Common locations of berry (saccular) aneurysms

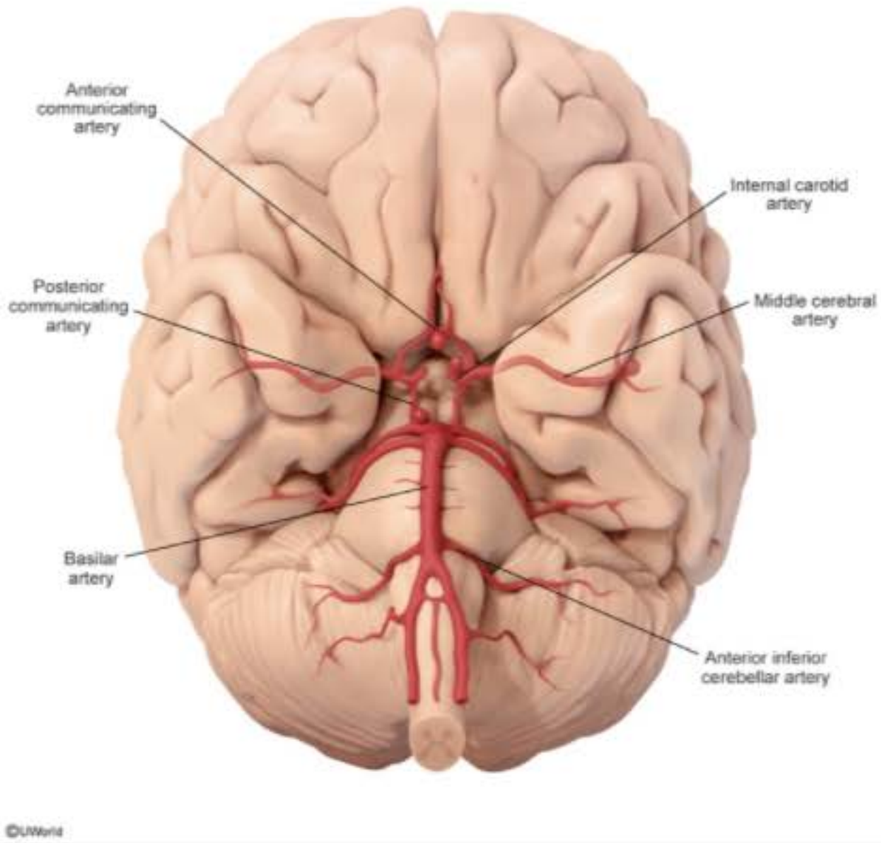

Zoom In | Zoom Out | Reset | Add To Flash Card

Subject System Topic

Block Time Remaining: 00:00:56
TUTOR

0 | Feedback | Suspend | End Block

Settings

1 2 3 4 5 6 7 8 9 10 11 12 13 14 15 16 17 18 19 20 21 22 23 24 25 26 27 28 29 30

Item 23 of 40
Question Id: 15866

Mark | Previous | Next | Full Screen | Tutorial | Lab Values | Notes | Calculator | Reverse Color | Text Zoom | Settings

This patient with a sudden-onset, explosive headache (ie, **thunderclap headache**), brief loss of consciousness, and signs of **meningeal irritation**

Exhibit Display

Intracranial hemorrhage imaging

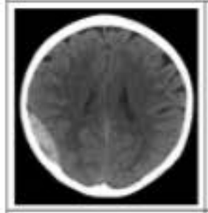

Epidural hematoma
- Lens-shaped convexity
- Contained between suture lines
- May span midline falx

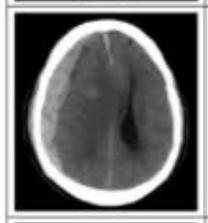

Subdural hematoma
- Crescent-shaped
- Crosses suture lines
- Cannot span midline falx

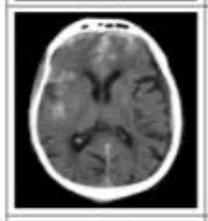

Subarachnoid hemorrhage
- Blood pooling in cerebral sulci
- Not contained by sutures or midline falx

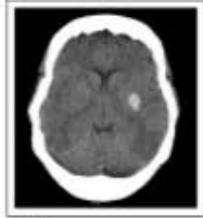

Intracerebral hemorrhage
- Blood contained within brain parenchyma
- Commonly affects basal ganglia, thalamus
- May extend into ventricles

Zoom In | Zoom Out | Reset | Add To Flash Card

Subject System Topic

Block Time Remaining: 00:00:56
TUTOR

0 | Feedback | Suspend | End Block

Settings

1 2 3 4 5 6 7 8 9 10 11 12 13 14 15 16 17 18 19 20 21 22 23 24 25 26 27 28 29 30

Item 24 of 40
Question Id: 1304

Mark | Previous | Next | Full Screen | Tutorial | Lab Values | Notes | Calculator | Reverse Color | Text Zoom | Settings

An intracranial mass is removed from a 33-year-old patient. The mass is composed of elongated cells that have regular, oval nuclei. A biphasic pattern of growth is identified, consisting of areas of dense cellularity interspersed with less dense myxoid regions. The cells show S-100 immunoreactivity. Which of the following is the most likely diagnosis in this patient?

A. Glioblastoma

B. Meningioma

C. Metastatic lung adenocarcinoma

D. Optic glioma

E. Schwannoma

Submit

Block Time Remaining: 00:00:56
TUTOR

7 | Feedback | Suspend | End Block

1 2 3 4 5 6 7 8 9 10 11 12 13 14 15 16 17 18 19 20 21 22 23 24 25 26 27 28 29 30

An intracranial mass is removed from a 33-year-old patient. The mass is composed of elongated cells that have regular, oval nuclei. A biphasic pattern of growth is identified, consisting of areas of dense cellularity interspersed with less dense myxoid regions. The cells show S-100 immunoreactivity. Which of the following is the most likely diagnosis in this patient?

A. Glioblastoma (17%)

B. Meningioma (16%)

C. Metastatic lung adenocarcinoma (5%)

D. Optic glioma (1%)

✓ E. Schwannoma (58%)

Omitted
Correct answer
E

58%
Answered correctly

02 secs
Time Spent

04/04/2020
Last Updated

Explanation

Schwannomas are tumors of the peripheral nervous system that arise from Schwann cells. Microscopically, they appear biphasic with highly cellular areas (Antoni A pattern) intermixed with myxoid regions of low cellularity (Antoni B pattern). The Antoni A areas are composed of spindle cells (elongated cells with regular, oval nuclei) that form palisading patterns with interspersing nuclear-free zones called Verocay bodies. Schwannomas are universally **S-100 positive** due to their neural crest cell origin. Another important S-100 positive tumor is melanoma (also derived from the neural crest).

1 2 3 4 5 6 7 8 9 10 11 12 13 14 15 16 17 18 19 20 21 22 23 24 25 26 27 28 29 30

Schwannomas are tumors of the peripheral nervous system that arise from Schwann cells. Microscopically, they appear biphasic with highly cellular areas (Antoni A pattern) intermixed with myxoid regions of low cellularity (Antoni B pattern). The Antoni A areas are composed of spindle cells (elongated cells with regular, oval nuclei) that form palisading patterns with interspersing nuclear-free zones called Verocay bodies. Schwannomas are universally **S-100 positive** due to their neural crest cell origin. Another important S-100 positive tumor is melanoma (also derived from the neural crest).

Schwann cells are to the peripheral nervous system as oligodendrocytes are to the central nervous system: both protect and insulate axons. The transition from oligodendrocytes to Schwann cells occurs within a few millimeters from the surface of the brain and spinal cord. Therefore, schwannomas can occur within the cranial vault and spinal canal. Schwannomas may arise from any cranial nerve except the optic nerve (CN II), which is covered by oligodendrocytes instead of Schwann cells. The most common site of intracranial schwannomas is the **cerebellopontine angle** at CN VIII. Schwannomas in this particular location are also called acoustic neuromas, and can present with **tinnitus, vertigo**, and sensorineural **hearing loss**.

(Choice A) Glioblastoma is a highly aggressive primary brain tumor that consists of bizarre-looking glial cells with multiple mitotic figures, pseudopalisading necrosis, and abundant neovascularization and hemorrhage. It commonly occurs in the frontotemporoparietal white matter and grows along the white matter tracts across the corpus callosum to affect the opposite hemisphere.

(Choice B) Meningiomas are typically slow-growing extra-axial tumors that arise from the meningothelial cells of the arachnoid. Meningiomas most commonly appear as cells arranged in lobules or whorls with or without psammoma bodies (laminar calcifications).

(Choice C) Brain metastases are the most common cause of intracranial tumors in adults. Lung, breast, skin (melanoma), and renal cancer are particularly likely to metastasize to the brain. Metastatic brain lesions form well-circumscribed masses along the grey-white junction. Histologically, there is often central necrosis with surrounding areas of reactive gliosis and edema.

(Choice D) Optic glioma is a form of glioma that affects the optic nerve. It is often found in association with neurofibromatosis type 1. Histologically, optic gliomas consist of immature astrocytes with microcystic degeneration and Rosenthal fibers (elongated or corkscrew intracytoplasmic eosinophilic bundles).

Settings

1
2
3
4
5
6
7
8
9
10
11
12
13
14
15
16
17
18
19
20
21
22
23
24
25
26
27
28
29
30

Item 24 of 40
Question Id: 1304

Mark | Previous | Next | Full Screen | Tutorial | Lab Values | Notes | Calculator | Reverse Color | Text Zoom | Settings

Exhibit Display

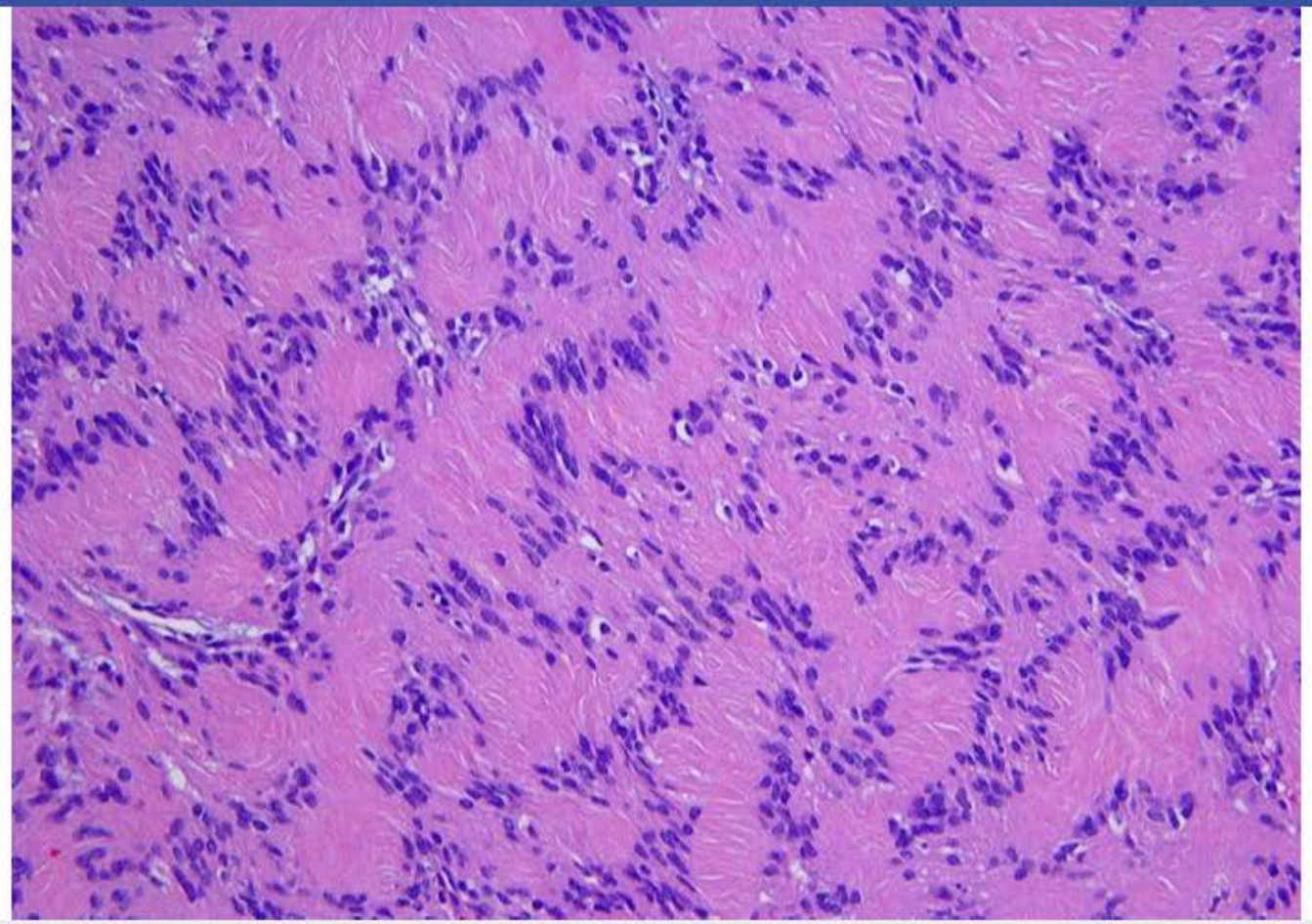

Zoom In | Zoom Out | Reset | Add To New Card | Existing Card

Block Time Remaining: 00:00:58
TUTOR

7 | Feedback | Suspend | End Block

Settings

1
2
3
4
5
6
7
8
9
10
11
12
13
14
15
16
17
18
19
20
21
22
23
24
25
26
27
28
29
30

Item 24 of 40
Question Id: 1304

Mark | Previous | Next | Full Screen | Tutorial | Lab Values | Notes | Calculator | Reverse Color | Text Zoom | Settings

Exhibit Display

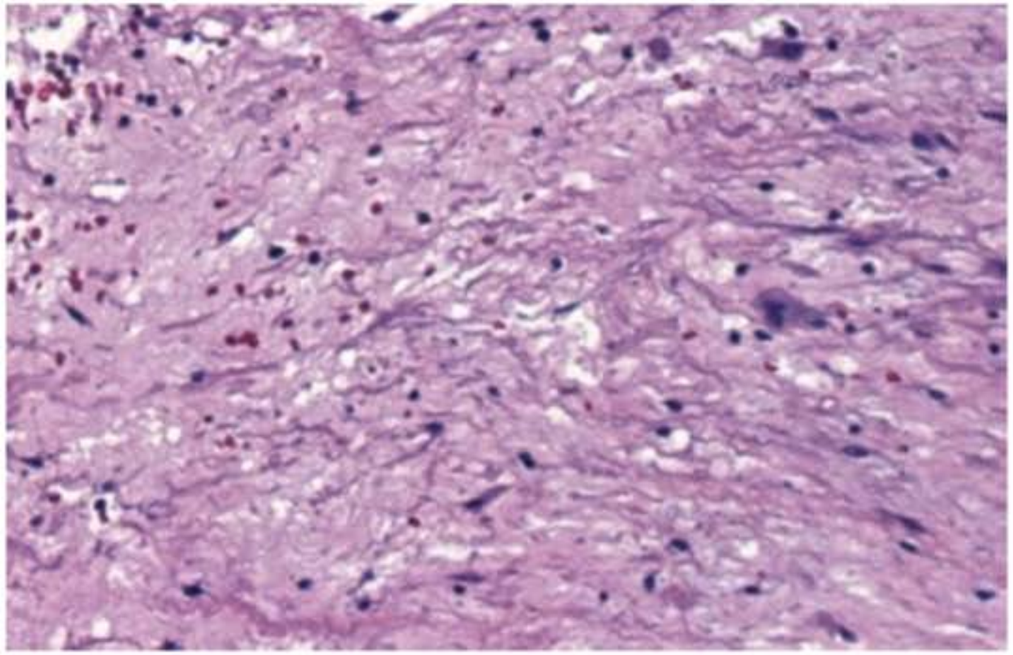

Zoom In | Zoom Out | Reset | Add To New Card | Existing Card

Block Time Remaining: 00:00:58
TUTOR

7 | Feedback | Suspend | End Block

Settings

1
2
3
4
5
6
7
8
9
10
11
12
13
14
15
16
17
18
19
20
21
22
23
24
25
26
27
28
29
30

Item 24 of 40
Question Id: 1304

Mark | Previous | Next | Full Screen | Tutorial | Lab Values | Notes | Calculator | Reverse Color | Text Zoom | Settings

Exhibit Display

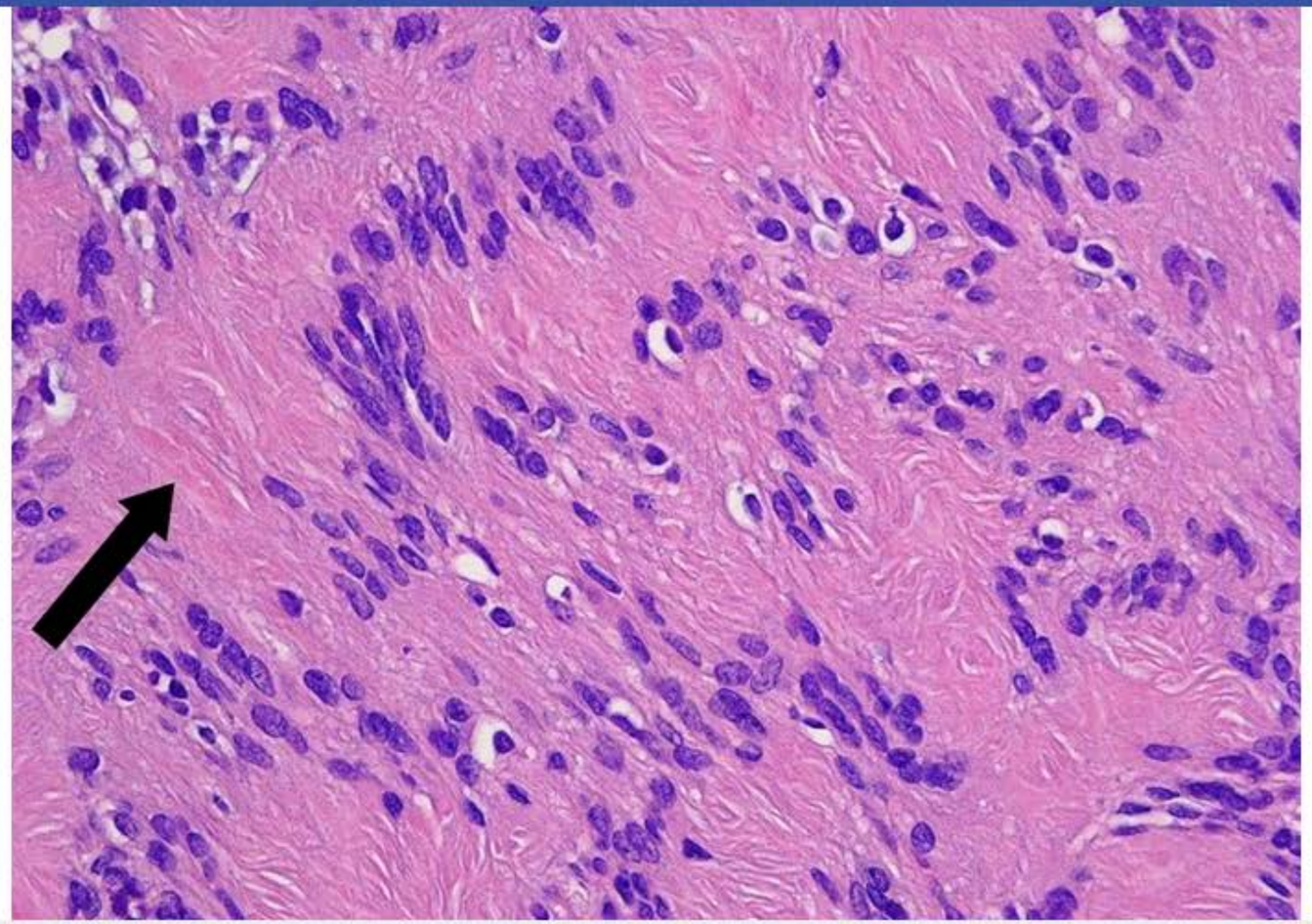

Zoom In | Zoom Out | Reset | Add To New Card | Existing Card

Block Time Remaining: 00:00:58
TUTOR

7 | Feedback | Suspend | End Block

Settings

1
2
3
4
5
6
7
8
9
10
11
12
13
14
15
16
17
18
19
20
21
22
23
24
25
26
27
28
29
30

Item 24 of 40
Question Id: 1304

Mark | Previous | Next | Full Screen | Tutorial | Lab Values | Notes | Calculator | Reverse Color | Text Zoom | Settings

schwannomas can occur within the cranial vault and spinal canal. Schwannomas may arise from any cranial nerve except the optic nerve (CN II),

Exhibit Display

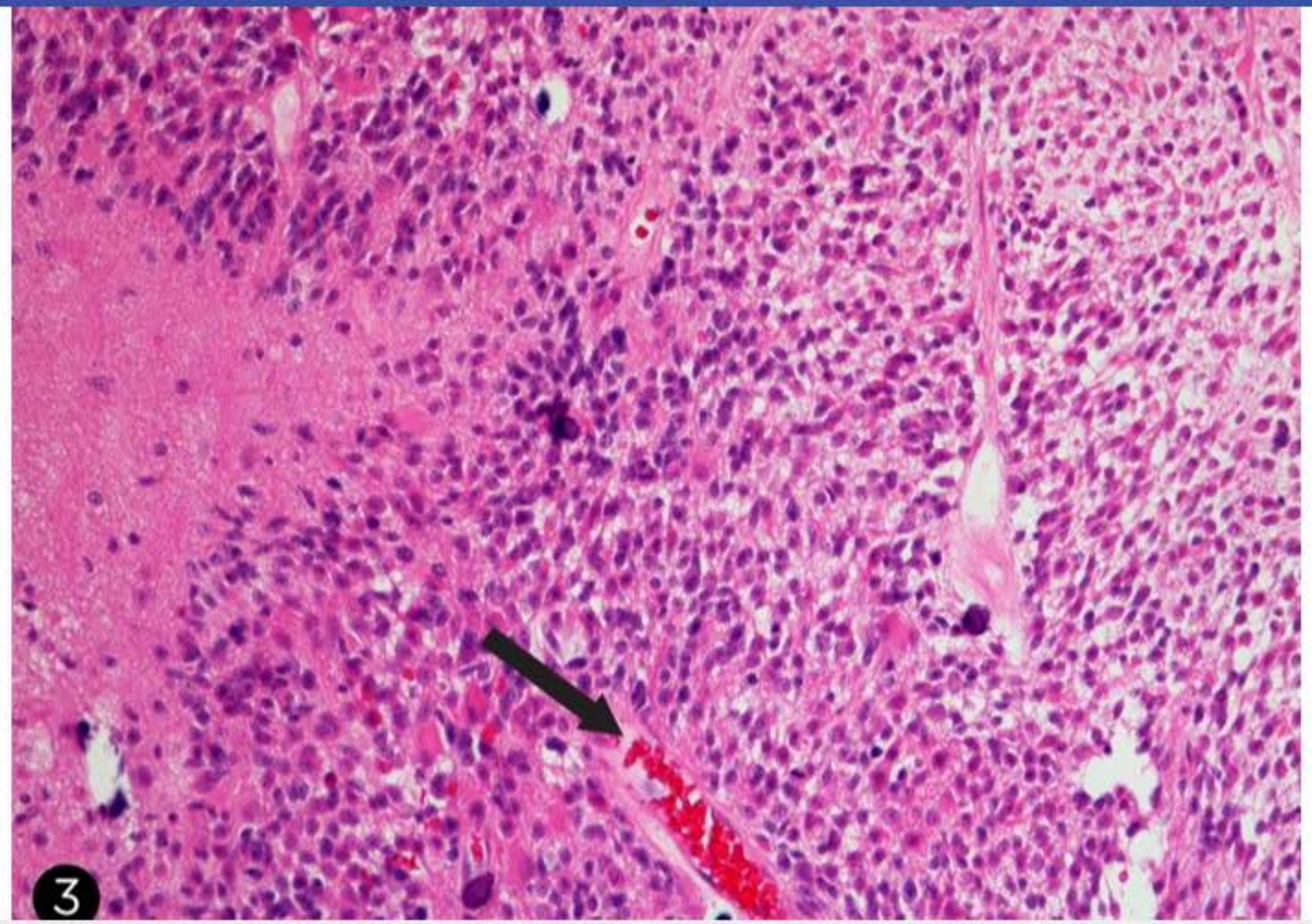

Zoom In | Zoom Out | Reset | Add To New Card | Existing Card

Block Time Remaining: 00:00:58
TUTOR

7 | Feedback | Suspend | End Block

Settings

1 2 3 4 5 6 7 8 9 10 11 12 13 14 15 16 17 18 19 20 21 22 23 24 25 26 27 28 29 30

Item 24 of 40
Question Id: 1304

Mark | Previous | Next | Full Screen | Tutorial | Lab Values | Notes | Calculator | Reverse Color | Text Zoom | Settings

schwannomas can occur within the cranial vault and spinal canal. Schwannomas may arise from any cranial nerve except the optic nerve (CN II),

Exhibit Display

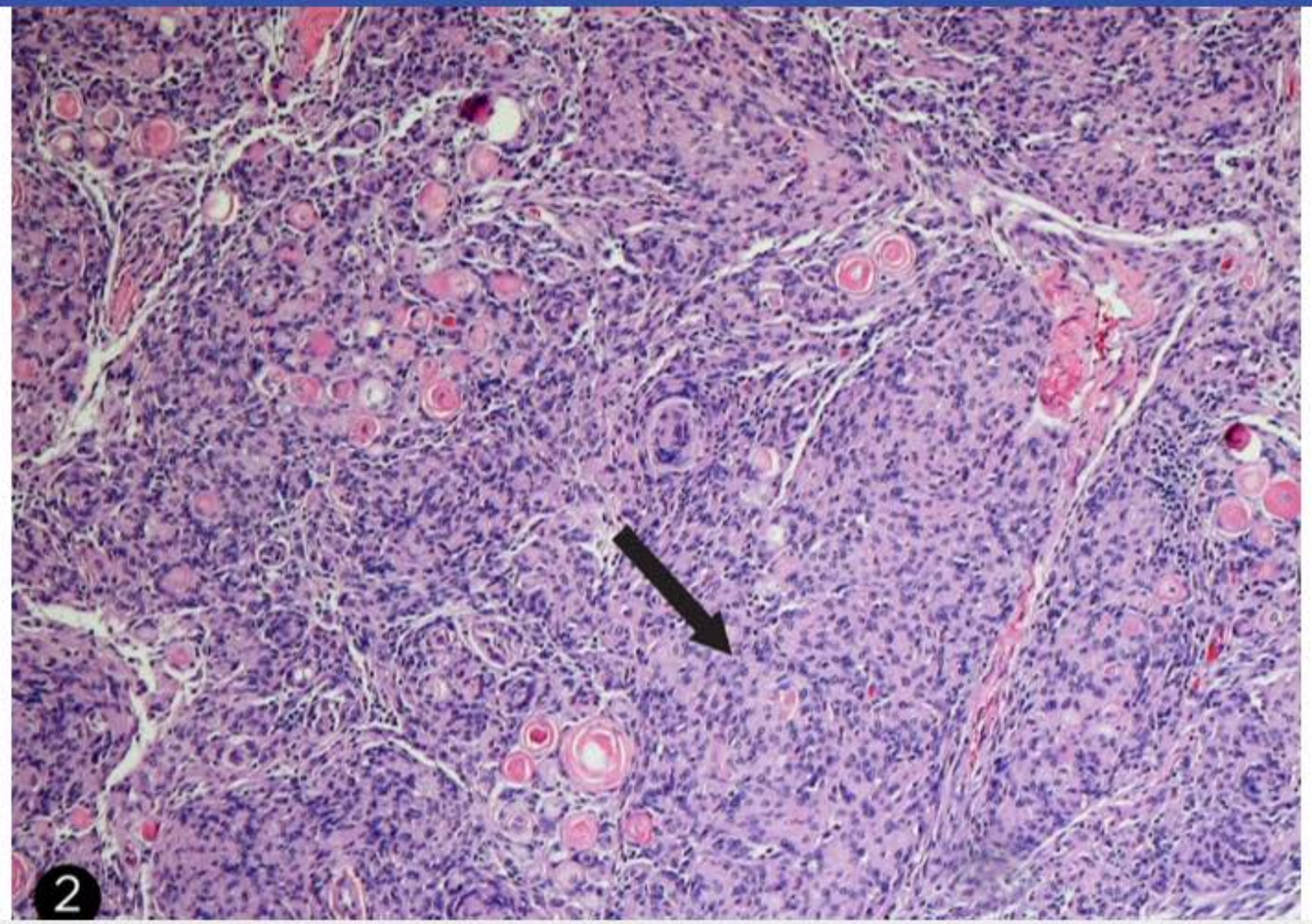

Zoom In | Zoom Out | Reset | Add To New Card | Existing Card

Block Time Remaining: 00:00:58
TUTOR

7 | Feedback | Suspend | End Block

Settings

1 2 3 4 5 6 7 8 9 10 11 12 13 14 15 16 17 18 19 20 21 22 23 24 25 26 27 28 29 30

Item 25 of 40
Question Id: 7490

Mark | Previous | Next | Full Screen | Tutorial | Lab Values | Notes | Calculator | Reverse Color | Text Zoom | Settings

An 82-year-old woman comes to the clinic due to memory loss. She lives with her daughter, who reports that her mother has had difficulty remembering recent conversations. The patient has also forgotten recent events, such as her grandson's birthday party last month. Two years ago, she was forced to give up driving after repeatedly getting lost in her own neighborhood and being involved in a minor motor vehicle accident. The patient still enjoys reminiscing about old times with friends and playing bingo at church. The daughter now manages her mother's finances and acts as her health care proxy. Which of the following is the most likely pathological finding in this patient?

A. Demyelinated plaques

B. Large intracytoplasmic vacuoles

C. Lewy bodies

D. Multiple lacunar infarcts

E. Negri bodies

F. Neuritic plaques

Submit

Block Time Remaining: 00:00:59
TUTOR

2 | Feedback | Suspend | End Block

1 2 3 4 5 6 7 8 9 10 11 12 13 14 15 16 17 18 19 20 21 22 23 24 25 26 27 28 29 30

An 82-year-old woman comes to the clinic due to memory loss. She lives with her daughter, who reports that her mother has had difficulty remembering recent conversations. The patient has also forgotten recent events, such as her grandson's birthday party last month. Two years ago, she was forced to give up driving after repeatedly getting lost in her own neighborhood and being involved in a minor motor vehicle accident. The patient still enjoys reminiscing about old times with friends and playing bingo at church. The daughter now manages her mother's finances and acts as her health care proxy. Which of the following is the most likely pathological finding in this patient?

- A. Demyelinated plaques (4%)
- B. Large intracytoplasmic vacuoles (3%)
- C. Lewy bodies (11%)
- D. Multiple lacunar infarcts (3%)
- E. Negri bodies (1%)
- ✓ F. Neuritic plaques (75%)

Omitted
Correct answer
F

75%
Answered correctly

02 secs
Time Spent

05/27/2020
Last Updated

Explanation

This elderly patient likely has Alzheimer dementia, a neurodegenerative disorder that presents insidiously with **memory loss**, especially of **recent events**. Other cognitive deficits such as **executive dysfunction** (eg, difficulty planning and organizing) and **visuospatial impairment** (eg, getting

1 2 3 4 5 6 7 8 9 10 11 12 13 14 15 16 17 18 19 20 21 22 23 24 25 26 27 28 29 30

This elderly patient likely has Alzheimer dementia, a neurodegenerative disorder that presents insidiously with **memory loss**, especially of **recent events**. Other cognitive deficits such as **executive dysfunction** (eg, difficulty planning and organizing) and **visuospatial impairment** (eg, getting lost in one's own neighborhood) may also occur early in the disease course, whereas language and behavioral abnormalities often appear later.

Classic histopathologic findings of Alzheimer disease include amyloid plaques and neurofibrillary tangles. Neuritic (senile) plaques are extracellular deposits often found in the medial temporal lobe (eg, hippocampus, amygdala, entorhinal cortex) and are composed of a central amyloid beta (Aβ) core surrounded by dystrophic neurites. Abnormal accumulation of Aβ is toxic to neurons and is thought to occur secondary to impaired clearance or overproduction of amyloid precursor protein. Neurofibrillary tangles are found in the neuronal cytoplasm and consist of aggregates of hyperphosphorylated tau protein, which normally mediates microtubule stabilization.

(Choice A) Demyelinated plaques are seen in multiple sclerosis, which typically presents in young to middle-age adults with neurologic deficits disseminated in space and time.

(Choice B) Large intracytoplasmic vacuoles, sometimes described as spongiform, are seen in prion diseases such as Creutzfeldt-Jakob disease. This condition typically presents with rapidly progressive dementia and myoclonus.

(Choice C) Lewy bodies are intracellular eosinophilic inclusions composed of α-synuclein that are typically seen in patients with Parkinson disease and Lewy body dementia. Lewy body dementia classically presents with attention deficits, visual hallucinations, and spontaneous parkinsonism (eg, bradykinesia, rigidity, resting tremor).

(Choice D) Multiple lacunar infarcts would be expected in vascular dementia. Vascular dementia is distinguished from Alzheimer dementia by a step-wise rather than gradual decline in cognitive function, as well as focal neurologic deficits.

(Choice E) Negri bodies are round eosinophilic inclusions seen in the cytoplasm of pyramidal hippocampal neurons and cerebellar Purkinje cells in patients infected with the rabies virus.

Educational objective:
Alzheimer dementia typically presents insidiously with memory loss (especially of recent events), executive dysfunction, and visuospatial impairment. Classic histopathologic findings include amyloid plaques (central amyloid beta core surrounded by dystrophic neurites) and

Settings

1
2
3
4
5
6
7
8
9
10
11
12
13
14
15
16
17
18
19
20
21
22
23
24
25
26
27
28
29
30

Item 25 of 40
Question Id: 7490

Mark | Previous | Next | Full Screen | Tutorial | Lab Values | Notes | Calculator | Reverse Color | Text Zoom | Settings

Exhibit Display

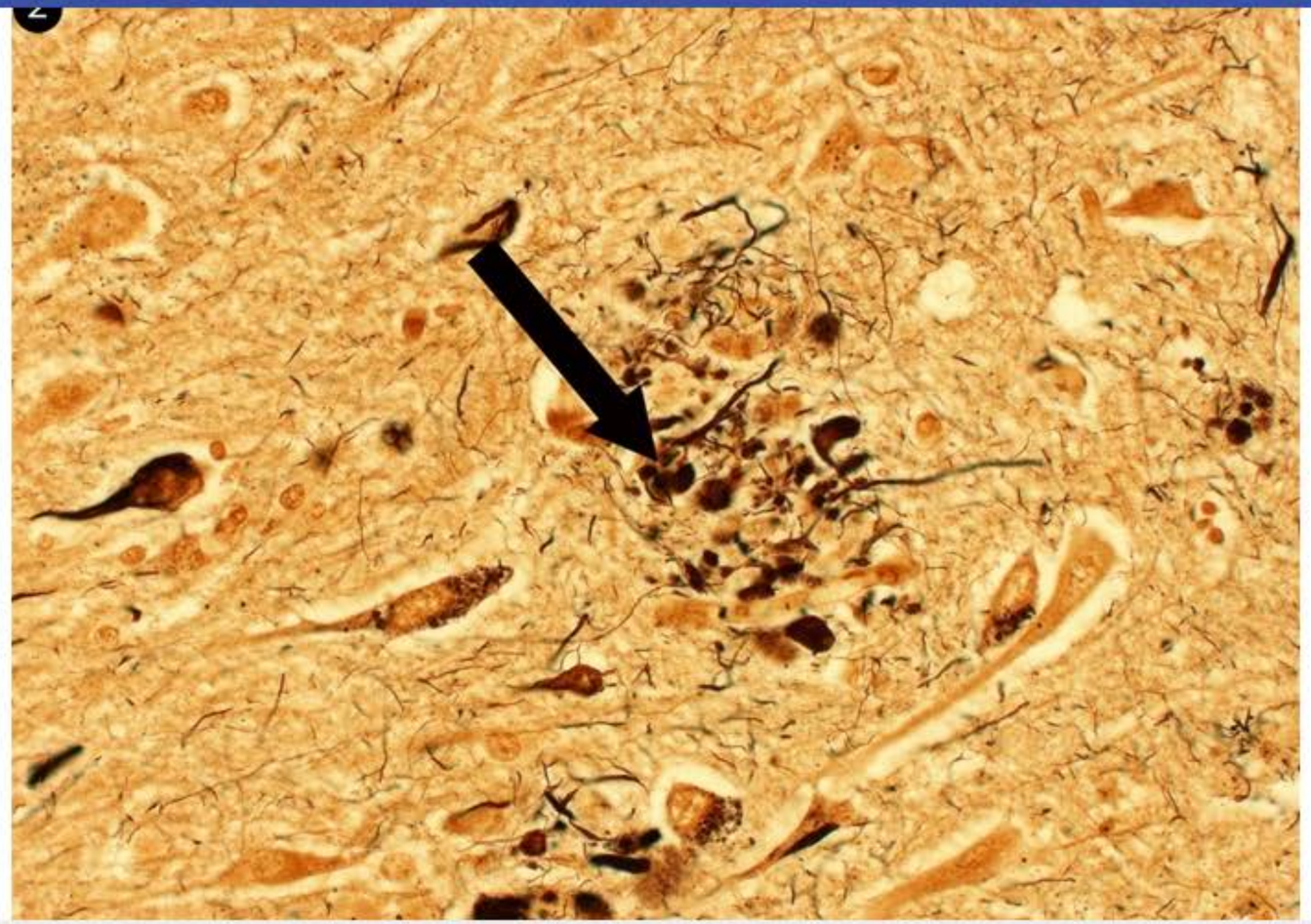

Zoom In | Zoom Out | Reset | Add To New Card | Existing Card

impairment. Classic histopathologic findings include amyloid plaques (central amyloid beta core surrounded by dystrophic neurites) and

Block Time Remaining: 00:01:00
TUTOR

2 | Feedback | Suspend | End Block

Settings

1 2 3 4 5 6 7 8 9 10 11 12 13 14 15 16 17 18 19 20 21 22 23 24 25 26 27 28 29 30

Item 25 of 40
Question Id: 7490

Mark | Previous | Next | Full Screen | Tutorial | Lab Values | Notes | Calculator | Reverse Color | Text Zoom | Settings

Exhibit Display

Alzheimer's disease

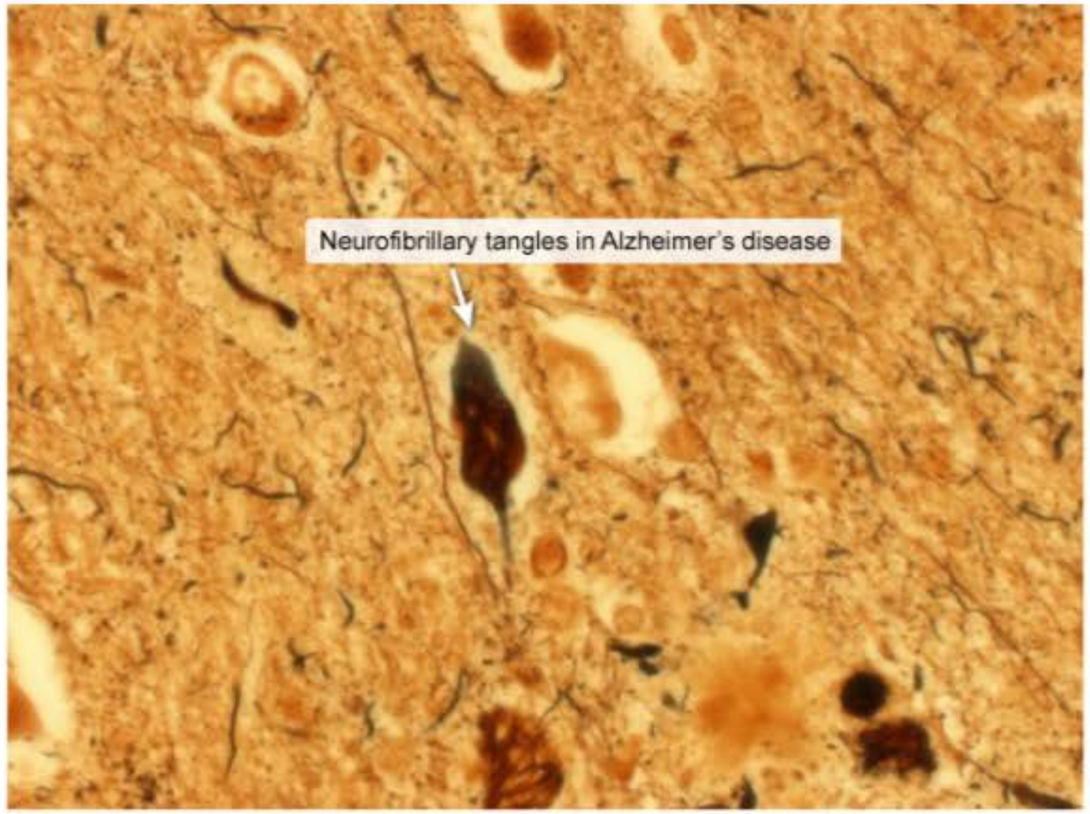

©UWorld

Zoom In | Zoom Out | Reset | Add To New Card | Existing Card

impairment. Classic histopathologic findings include amyloid plaques (central amyloid beta core surrounded by dystrophic neurites) and

Block Time Remaining: 00:01:00
TUTOR

2 | Feedback | Suspend | End Block

aggregates of hyperphosphorylated tau protein, which normally mediates microtubule stabilization.

(Choice A) Demyelinated plaques are seen in multiple sclerosis, which typically presents in young to middle-age adults with neurologic deficits disseminated in space and time.

(Choice B) Large intracytoplasmic vacuoles, sometimes described as spongiform, are seen in prion diseases such as Creutzfeldt-Jakob disease. This condition typically presents with rapidly progressive dementia and myoclonus.

(Choice C) Lewy bodies are intracellular eosinophilic inclusions composed of α-synuclein that are typically seen in patients with Parkinson disease and Lewy body dementia. Lewy body dementia classically presents with attention deficits, visual hallucinations, and spontaneous parkinsonism (eg, bradykinesia, rigidity, resting tremor).

(Choice D) Multiple lacunar infarcts would be expected in vascular dementia. Vascular dementia is distinguished from Alzheimer dementia by a step-wise rather than gradual decline in cognitive function, as well as focal neurologic deficits.

(Choice E) Negri bodies are round eosinophilic inclusions seen in the cytoplasm of pyramidal hippocampal neurons and cerebellar Purkinje cells in patients infected with the rabies virus.

Educational objective:
Alzheimer dementia typically presents insidiously with memory loss (especially of recent events), executive dysfunction, and visuospatial impairment. Classic histopathologic findings include amyloid plaques (central amyloid beta core surrounded by dystrophic neurites) and neurofibrillary tangles (aggregates of hyperphosphorylated tau protein).

References

- Pathogenesis of Alzheimer's disease.

Pathology	Nervous System	Alzheimer disease
Subject	System	Topic

Copyright © UWorld. All rights reserved.

Settings

1 2 3 4 5 6 7 8 9 10 11 12 13 14 15 16 17 18 19 20 21 22 23 24 25 26 27 28 29 30

Item 26 of 40
Question Id: 4

Mark | Previous | Next | Full Screen | Tutorial | Lab Values | Notes | Calculator | Reverse Color | Text Zoom | Settings

A 56-year-old male with history of polycystic kidney disease presented to the emergency room because of sudden onset severe headache. He has never had this type of headache in the past. Examination shows some nuchal rigidity. Neurologic examination is within normal limits. Which of the following is the most likely diagnosis?

A. Bacterial meningitis

B. Migraine headaches

C. Intracerebral hemorrhage

D. Subarachnoid hemorrhage

E. Temporal arteritis

F. Cluster headache

Submit

Block Time Remaining: 00:01:00
TUTOR

2 | Feedback | Suspend | End Block

1 2 3 4 5 6 7 8 9 10 11 12 13 14 15 16 17 18 19 20 21 22 23 24 25 26 27 28 29 30

A 56-year-old male with history of polycystic kidney disease presented to the emergency room because of sudden onset severe headache. He has never had this type of headache in the past. Examination shows some nuchal rigidity. Neurologic examination is within normal limits. Which of the following is the most likely diagnosis?

- A. Bacterial meningitis (6%)
- B. Migraine headaches (0%)
- C. Intracerebral hemorrhage (6%)
- ✓ D. Subarachnoid hemorrhage (84%)
- E. Temporal arteritis (1%)
- F. Cluster headache (1%)

Omitted
Correct answer
D

84%
Answered correctly

02 secs
Time Spent

06/11/2020
Last Updated

Explanation

Although the major pathologic process in Autosomal Dominant Polycystic Kidney Disease (ADPKD) is in the kidneys, it is a systemic disorder. Cysts and other anomalies are noted in different organs. Intracranial berry aneurysms arise in the circle of Willis, and when these aneurysms rupture they cause subarachnoid hemorrhage (SAH). The clinical presentation described in this question is suggestive of SAH. Patients complain

Explanation

Although the major pathologic process in Autosomal Dominant Polycystic Kidney Disease (ADPKD) is in the kidneys, it is a systemic disorder. Cysts and other anomalies are noted in different organs. Intracranial berry aneurysms arise in the circle of Willis, and when these aneurysms rupture they cause subarachnoid hemorrhage (SAH). The clinical presentation described in this question is suggestive of SAH. Patients complain of a severe headache ("the worst headache of their life"); neck stiffness is usually present or develops in the next 24 hours as blood in the subarachnoid space acts as a meningeal irritant. Papilledema and pupillary dilation may be noted, but there are no focal neurologic findings.

CT scan of the brain without contrast is the most commonly used initial imaging study for diagnosing SAH and should be done during the first 24 hours from the onset of symptoms. This is positive in up to 90% of patients. If the CT scan does not show SAH, but the clinical suspicion remains high, a lumbar puncture needs to be performed to evaluate the cerebrospinal fluid for the presence of xanthochromia (blood in the CSF). Thus, presence of the xanthochromia in a clinical scenario suggestive of SAH is the most sensitive test for diagnosing SAH.

(Choice A) The classic presentation of meningitis includes fever, headache, neck stiffness, photophobia, nausea, vomiting, and signs of cerebral dysfunction (eg, lethargy, confusion, and coma). Additionally, remember to look for clues leading you to the correct answer. For example, the question writer here mentioned that this patient has ADPKD for a reason, to lead you to SAH.

(Choice B) Migraine headache is throbbing or pulsatile. It is initially unilateral and localized in the frontotemporal and ocular area, then progresses posteriorly and becomes diffuse. It typically lasts from several hours to an entire day.

(Choice C) Intracerebral hemorrhage manifests with headache, vomiting and sudden onset of focal neurological deficits (hemiplegia, hemianesthesia, cranial nerve deficits, aphasia etc). Focal neurologic manifestations are unusual with SAH.

(Choice E) An elderly male with scalp tenderness over the temporal area (or headache), blurred vision and intermittent claudication of jaw is a typical presentation of temporal arteritis. This condition is also accompanied by a very high ESR (erythrocyte sedimentation rate) and many times occurs in the setting of polymyalgia rheumatica. Rapid treatment with corticosteroids is necessary to prevent potential blindness.

(Choice F) Cluster headache consists of recurrent brief attacks of sudden, severe, unilateral periorbital pain associated with ipsilateral rhinorrhea, and watering of the eyes.

hours from the onset of symptoms. This is positive in up to 90% of patients. If the CT scan does not show SAH, but the clinical suspicion remains high, a lumbar puncture needs to be performed to evaluate the cerebrospinal fluid for the presence of xanthochromia (blood in the CSF). Thus, presence of the xanthochromia in a clinical scenario suggestive of SAH is the most sensitive test for diagnosing SAH.

(Choice A) The classic presentation of meningitis includes fever, headache, neck stiffness, photophobia, nausea, vomiting, and signs of cerebral dysfunction (eg, lethargy, confusion, and coma). Additionally, remember to look for clues leading you to the correct answer. For example, the question writer here mentioned that this patient has ADPKD for a reason, to lead you to SAH.

(Choice B) Migraine headache is throbbing or pulsatile. It is initially unilateral and localized in the frontotemporal and ocular area, then progresses posteriorly and becomes diffuse. It typically lasts from several hours to an entire day.

(Choice C) Intracerebral hemorrhage manifests with headache, vomiting and sudden onset of focal neurological deficits (hemiplegia, hemianesthesia, cranial nerve deficits, aphasia etc). Focal neurologic manifestations are unusual with SAH.

(Choice E) An elderly male with scalp tenderness over the temporal area (or headache), blurred vision and intermittent claudication of jaw is a typical presentation of temporal arteritis. This condition is also accompanied by a very high ESR (erythrocyte sedimentation rate) and many times occurs in the setting of polymyalgia rheumatica. Rapid treatment with corticosteroids is necessary to prevent potential blindness.

(Choice F) Cluster headache consists of recurrent brief attacks of sudden, severe, unilateral periorbital pain associated with ipsilateral rhinorrhea, and watering of the eyes.

Educational Objective:
Intracranial berry aneurysms of the circle of Willis are often seen in patients with ADPKD; when ruptured, they cause subarachnoid hemorrhage that presents with sudden onset of "thunderclap headache".

Pathology	Nervous System	Subarachnoidal hemorrhage
Subject	System	Topic

Copyright © UWorld. All rights reserved.

Settings

1 2 3 4 5 6 7 8 9 10 11 12 13 14 15 16 17 18 19 20 21 22 23 24 25 26 27 28 29 30

Item 27 of 40
Question Id: 177

Mark | Previous | Next | Full Screen | Tutorial | Lab Values | Notes | Calculator | Reverse Color | Text Zoom | Settings

A 73-year-old man comes to the emergency department due to right-sided weakness and difficulty speaking. The patient woke up with the symptoms an hour before arriving but felt well when he went to bed last night. He has a history of paroxysmal atrial fibrillation but is not adherent with medical therapy. Temperature is 98.6 F (37 C), blood pressure is 130/70 mm Hg, and pulse is 110/min and irregularly irregular. Physical examination shows right-sided hemiplegia, hemisensory loss, and aphasia. Despite appropriate treatment, the patient's symptoms fail to improve. Over the next week, which of the following processes is most likely to occur in the affected brain region?

A. Accumulation of fibrin-like material in vessel walls

B. Formation of a necrotic focus surrounded by epithelioid macrophages

C. Deposition of fatty acid and calcium complexes

D. Hydrolytic enzyme-induced tissue digestion

E. Tissue necrosis with preservation of cellular architecture

Submit

Block Time Remaining: 00:01:02
TUTOR

6 | Feedback | Suspend | End Block

A 73-year-old man comes to the emergency department due to right-sided weakness and difficulty speaking. The patient woke up with the symptoms an hour before arriving but felt well when he went to bed last night. He has a history of paroxysmal atrial fibrillation but is not adherent with medical therapy. Temperature is 98.6 F (37 C), blood pressure is 130/70 mm Hg, and pulse is 110/min and irregularly irregular. Physical examination shows right-sided hemiplegia, hemisensory loss, and aphasia. Despite appropriate treatment, the patient's symptoms fail to improve. Over the next week, which of the following processes is most likely to occur in the affected brain region?

- A. Accumulation of fibrin-like material in vessel walls (3%)
- B. Formation of a necrotic focus surrounded by epithelioid macrophages (22%)
- C. Deposition of fatty acid and calcium complexes (1%)
- ✓ D. Hydrolytic enzyme-induced tissue digestion (65%)
- E. Tissue necrosis with preservation of cellular architecture (7%)

Omitted
Correct answer
D

65%
Answered correctly

01 sec
Time Spent

03/31/2020
Last Updated

Explanation

Patterns of tissue necrosis		
Type	Etiology	Morphology

Patterns of tissue necrosis

Type	Etiology	Morphology
Liquefactive necrosis	• Severe bacterial infections (eg, gangrene) • CNS infarcts	• Necrotic tissue is digested by hydrolytic enzymes into a viscous fluid: ◦ Infected abscess fluid is creamy yellow due to dead leukocytes (pus) ◦ Brain infarcts resolve into CSF-filled spaces
Fibrinoid necrosis	• Hypertension • Vasculitis	• Damaged vessels leak fibrin/immune complexes • Eosinophilic layer of proteinaceous material in vessel walls
Fat necrosis	• Acute pancreatitis • Trauma (subcutaneous adipose tissue)	• Free fatty acids released by active enzymes (eg, lipases) or mechanical damage • Fatty acids combine with calcium, forming chalky-white deposits (saponification)
Caseous necrosis	• Mycobacterial infections • Fungal infections (eg, *Histoplasma*, *Cryptococcus*, *Coccidioides*)	• Friable, cheeselike material composed of cell fragments & amorphous proteinaceous debris • Surrounded by epithelioid macrophages & giant cells (granuloma)
Coagulative necrosis	• Irreversible ischemic injury outside CNS	• Tissue architecture is preserved due to denaturation of lytic enzymes: ◦ Cells are anucleate with eosinophilic cytoplasm ◦ Leukocytes eventually infiltrate & digest necrotic tissue

CSF = cerebrospinal fluid.

This patient's symptoms are consistent with an **ischemic stroke** involving the left middle cerebral artery territory. An **embolism** is the most likely cause given his history of atrial fibrillation in the absence of anticoagulation therapy. The resulting irreversible neural cell injury initiates immune cell migration and **hydrolytic enzyme release**, leading to necrosis of damaged neural tissue. Although ischemic cell death in most organs results in coagulative necrosis, in the brain such injury causes **liquefactive necrosis** within 10 days of the infarction due to the brain's lack of supporting architecture.

The infarcted CNS tissue is then digested by microglia and replaced with a cystic space surrounded by a dense astroglial scar (gliosis) over the ensuing months to years.

(Choice A) Fibrinoid necrosis is a pattern of injury that results in accumulation of fibrin-like material in the walls of blood vessels affected by vasculitis syndromes (eg, polyarteritis nodosa) or malignant hypertension. Although fibrinoid necrosis in cerebral arteries can predispose a patient to hemorrhagic stroke, this change would not be an expected complication of acute ischemic stroke.

(Choice B) Focal tuberculous infection can occur in the CNS and cause caseous necrosis (epithelioid macrophages around a necrotic focus) within the affected parenchyma. However, the onset of neurologic symptoms in patients with tuberculous brain abscesses tends to be more chronic and progressive than this patient's acute presentation.

(Choice C) Breakdown of adipose tissue (ie, fat necrosis) due to mechanical trauma or pancreatic enzyme release (eg, acute pancreatitis) is characterized by infiltrating foamy macrophages containing engulfed lipid debris and release of free fatty acids that combine with calcium to form basophilic deposits.

(Choice E) Coagulative necrosis occurs following hypoxic cell death in all tissues except the CNS. It results in the acute denaturation of structural and enzymatic cellular proteins. Cell nuclei disappear, but the basic architecture of the affected tissue is preserved because intracellular proteolytic enzymes are inactivated during the injury process.

Educational objective:
Irreversible ischemic injury to brain tissue causes tissue digestion by hydrolytic enzymes (liquefactive necrosis). The infarcted CNS tissue is eventually replaced with a cystic astroglial scar. In other organs, lethal ischemic injury results in coagulative necrosis.

Settings

1
2
3
4
5
6
7
8
9
10
11
12
13
14
15
16
17
18
19
20
21
22
23
24
25
26
27
28
29
30

Item 27 of 40
Question Id: 177

Mark | Previous | Next | Full Screen | Tutorial | Lab Values | Notes | Calculator | Reverse Color | Text Zoom | Settings

Exhibit Display

Zoom In | Zoom Out | Reset | Add To New Card | Existing Card

Block Time Remaining: 00:01:03
TUTOR

6 | Feedback | Suspend | End Block

Settings

1 2 3 4 5 6 7 8 9 10 11 12 13 14 15 16 17 18 19 20 21 22 23 24 25 26 27 28 29 30

Item 27 of 40
Question Id: 177

Mark | Previous | Next | Full Screen | Tutorial | Lab Values | Notes | Calculator | Reverse Color | Text Zoom | Settings

Exhibit Display

Fibrinoid necrosis

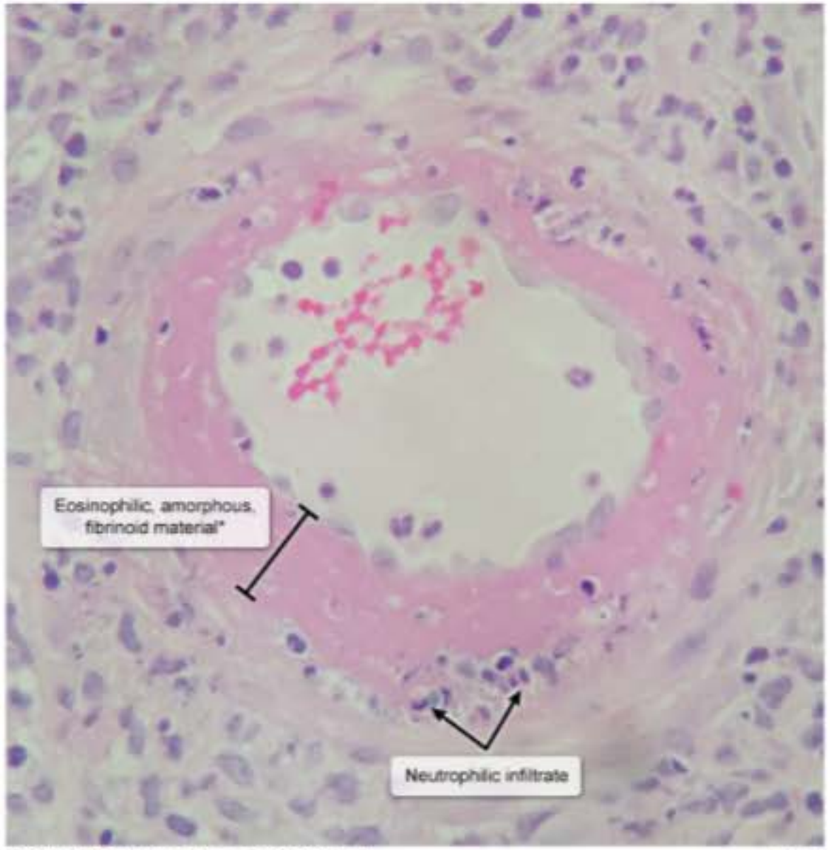

*Deposits of immune complexes with fibrin in vessel wall

Zoom In | Zoom Out | Reset | Add To New Card | Existing Card

Block Time Remaining: 00:01:03
TUTOR

6 | Feedback | Suspend | End Block

Settings

1
2
3
4
5
6
7
8
9
10
11
12
13
14
15
16
17
18
19
20
21
22
23
24
25
26
27
28
29
30

Item 27 of 40
Question Id: 177

Mark | Previous | Next | Full Screen | Tutorial | Lab Values | Notes | Calculator | Reverse Color | Text Zoom | Settings

Exhibit Display

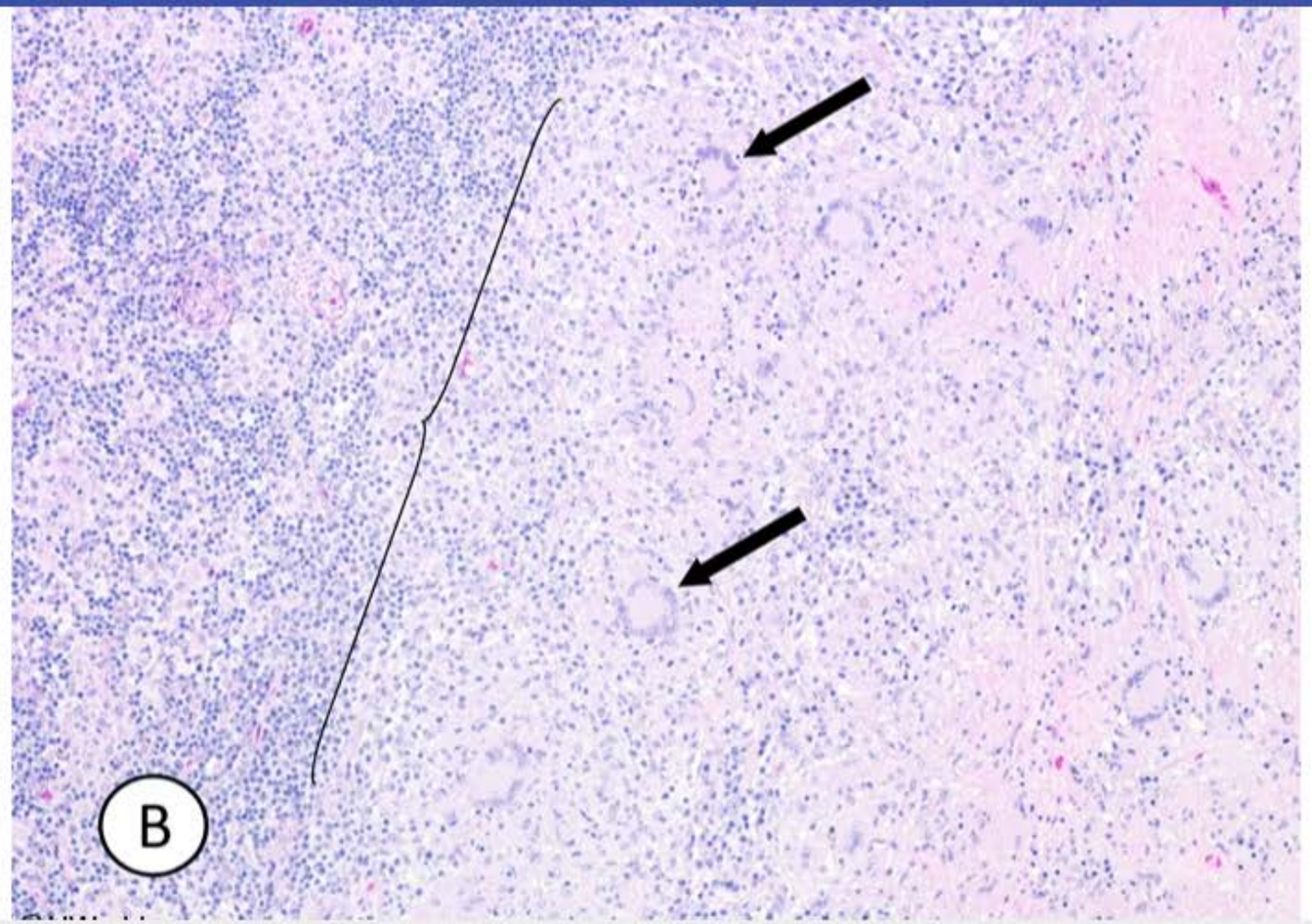

Zoom In | Zoom Out | Reset | Add To New Card | Existing Card

Block Time Remaining: 00:01:03
TUTOR

6 | Feedback | Suspend | End Block

Settings

1
2
3
4
5
6
7
8
9
10
11
12
13
14
15
16
17
18
19
20
21
22
23
24
25
26
27
28
29
30

Item 27 of 40
Question Id: 177

Mark | Previous | Next | Full Screen | Tutorial | Lab Values | Notes | Calculator | Reverse Color | Text Zoom | Settings

Exhibit Display

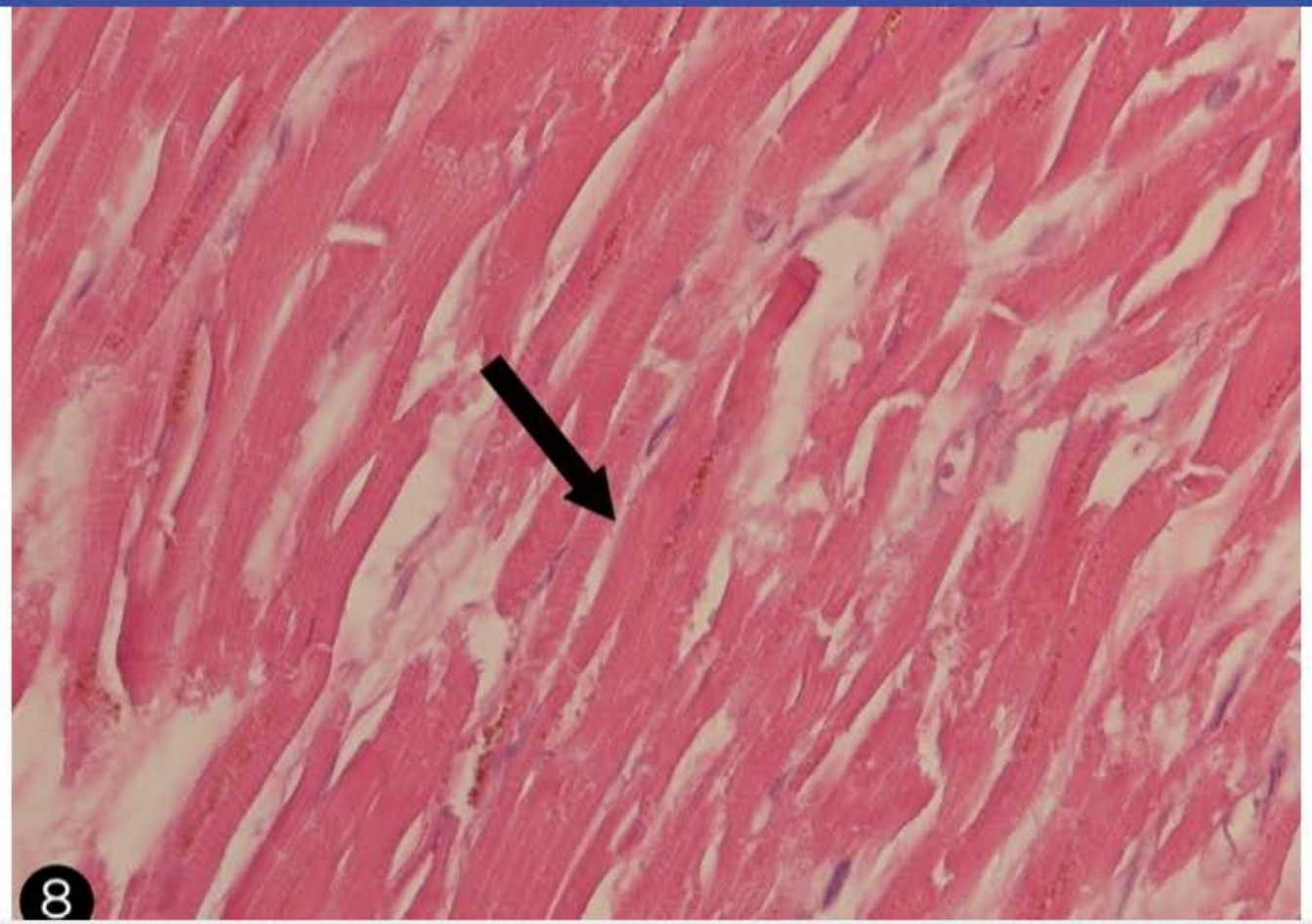

Zoom In | Zoom Out | Reset | Add To New Card | Existing Card

Block Time Remaining: 00:01:03
TUTOR

6 | Feedback | Suspend | End Block

Settings

1 2 3 4 5 6 7 8 9 10 11 12 13 14 15 16 17 18 19 20 21 22 23 24 25 26 27 28 29 30

Item 28 of 40
Question Id: 911

Mark | Previous | Next | Full Screen | Tutorial | Lab Values | Notes | Calculator | Reverse Color | Text Zoom | Settings

A 57-year-old man is hospitalized for aspiration pneumonia. Until 4 months ago, the patient was healthy and worked as an engineer without difficulty. However, since that time, he has developed severe confusion, mood changes, and memory impairment and had to take medical leave from work. The patient is now completely dependent on his wife for toileting, feeding, and general self-care. Physical examination shows disorientation and sporadic, jerky extremity movements. Soon after admission, he lapses into a coma and dies. Postmortem examination of brain tissue shows widespread neuronal loss with small, uniform intracellular vacuoles throughout the gray matter. No inflammatory changes are present. Which of the following is the most likely diagnosis?

- A. Creutzfeldt-Jakob disease
- B. Frontotemporal dementia
- C. HIV-associated dementia
- D. Multiple sclerosis
- E. Neurosyphilis
- F. Progressive multifocal leukoencephalopathy
- G. Subacute sclerosing panencephalitis

Submit

Block Time Remaining: 00:01:03
TUTOR

3 | Feedback | Suspend | End Block

1 2 3 4 5 6 7 8 9 10 11 12 13 14 15 16 17 18 19 20 21 22 23 24 25 26 27 28 29 30

A 57-year-old man is hospitalized for aspiration pneumonia. Until 4 months ago, the patient was healthy and worked as an engineer without difficulty. However, since that time, he has developed severe confusion, mood changes, and memory impairment and had to take medical leave from work. The patient is now completely dependent on his wife for toileting, feeding, and general self-care. Physical examination shows disorientation and sporadic, jerky extremity movements. Soon after admission, he lapses into a coma and dies. Postmortem examination of brain tissue shows widespread neuronal loss with small, uniform intracellular vacuoles throughout the gray matter. No inflammatory changes are present. Which of the following is the most likely diagnosis?

- ✓ A. Creutzfeldt-Jakob disease (85%)
- B. Frontotemporal dementia (4%)
- C. HIV-associated dementia (0%)
- D. Multiple sclerosis (0%)
- E. Neurosyphilis (0%)
- F. Progressive multifocal leukoencephalopathy (5%)
- G. Subacute sclerosing panencephalitis (2%)

Omitted
Correct answer
A

85%
Answered correctly

02 secs
Time Spent

04/04/2020
Last Updated

Explanation

This previously healthy patient developed **rapidly progressive dementia** associated with **myoclonus** (eg, involuntary, jerky extremity movements). Autopsy showed **spongiform** changes (eg, uniform intracellular vacuoles throughout the grey matter) with widespread neuronal loss and no inflammatory response; these findings are consistent with the prion disease known as **Creutzfeldt-Jakob disease** (CJD).

Prion diseases (transmissible spongiform encephalopathies) are associated with the change in structural conformation (alpha-helix to beta-sheet) of **prion protein** (PrP^{C}). The abnormal prion protein (designated PrP^{SC}) is resistant to enzymatic degradation and converts other prion protein to PrP^{SC}, which accumulates within neuronal and glial cells, causing neural cell death.

Although CJD may be inherited or iatrogenic (eg, contaminated corneal or dural graft transplant), most cases are sporadic, typically present around age 60, and are **rapidly fatal** after symptom onset (within 4-6 months). Other types of prion diseases include kuru (historically associated with ritual cannibalistic practices in Papua, New Guinea) and fatal familial insomnia (progressive insomnia with confusion and hallucinations).

(Choice B) Frontotemporal dementia typically presents around age 60 with personality changes and progressive mental deterioration. However, the decline usually over the course of years and myoclonus (if it develops) is typically a late finding. In addition, the histopathologic changes in frontotemporal dementia include neuronal loss, gliosis, and inclusions in the frontal and temporal lobes.

(Choice C) HIV-associated dementia occurs most often in patients with a long history of untreated HIV and causes mild, subacute cognitive impairment. Myoclonus and spongiform changes on histology would not be expected.

(Choice D) Multiple sclerosis is a demyelinating disease that most often presents in young adults and follows a relapsing-remitting course with intermittent and varied neurological manifestations. Pathologic changes include irregular periventricular white matter plaques with inflammatory infiltration and loss of oligodendrocytes.

(Choice E) Late-stage neurosyphilis has become rare since the advent of penicillin and is typically seen in patients with HIV decades after the initial infection, manifesting as progressive dementia with personality changes and paralysis.

(Choice F) Progressive multifocal leukoencephalopathy usually presents with altered mental status and neurological deficits (eg, ataxia, hemiparesis, diplopia) in immunocompromised (eg, HIV, lymphoma, leukemia) patients. It is caused by infection of oligodendrocytes by the JC polyoma virus, which causes patches of demyelination with enlarged, abnormal astrocytes.

impairment. Myoclonus and spongiform changes on histology would not be expected.

(Choice D) Multiple sclerosis is a demyelinating disease that most often presents in young adults and follows a relapsing-remitting course with intermittent and varied neurological manifestations. Pathologic changes include irregular periventricular white matter plaques with inflammatory infiltration and loss of oligodendrocytes.

(Choice E) Late-stage neurosyphilis has become rare since the advent of penicillin and is typically seen in patients with HIV decades after the initial infection, manifesting as progressive dementia with personality changes and paralysis.

(Choice F) Progressive multifocal leukoencephalopathy usually presents with altered mental status and neurological deficits (eg, ataxia, hemiparesis, diplopia) in immunocompromised (eg, HIV, lymphoma, leukemia) patients. It is caused by infection of oligodendrocytes by the JC polyoma virus, which causes patches of demyelination with enlarged, abnormal astrocytes.

(Choice G) Although subacute sclerosing panencephalitis can cause progressive dementia and myoclonus (with eventual paralysis), it occurs almost exclusively in patients age <20 with a history of measles infection 7-10 years earlier. Microscopic examination reveals myelin degeneration and viral inclusions.

Educational objective:
Creutzfeldt-Jakob disease is a prion disease characterized by rapidly progressive dementia, myoclonus, and death within a year of symptom onset. Histopathology shows widespread neuronal loss with small, uniform vacuoles in the gray matter of the brain (eg, spongiform encephalopathy).

References

- Creutzfeldt-Jakob disease.

Pathology	Nervous System	Prion disease
Subject	System	Topic

Copyright © UWorld. All rights reserved.

Exhibit Display

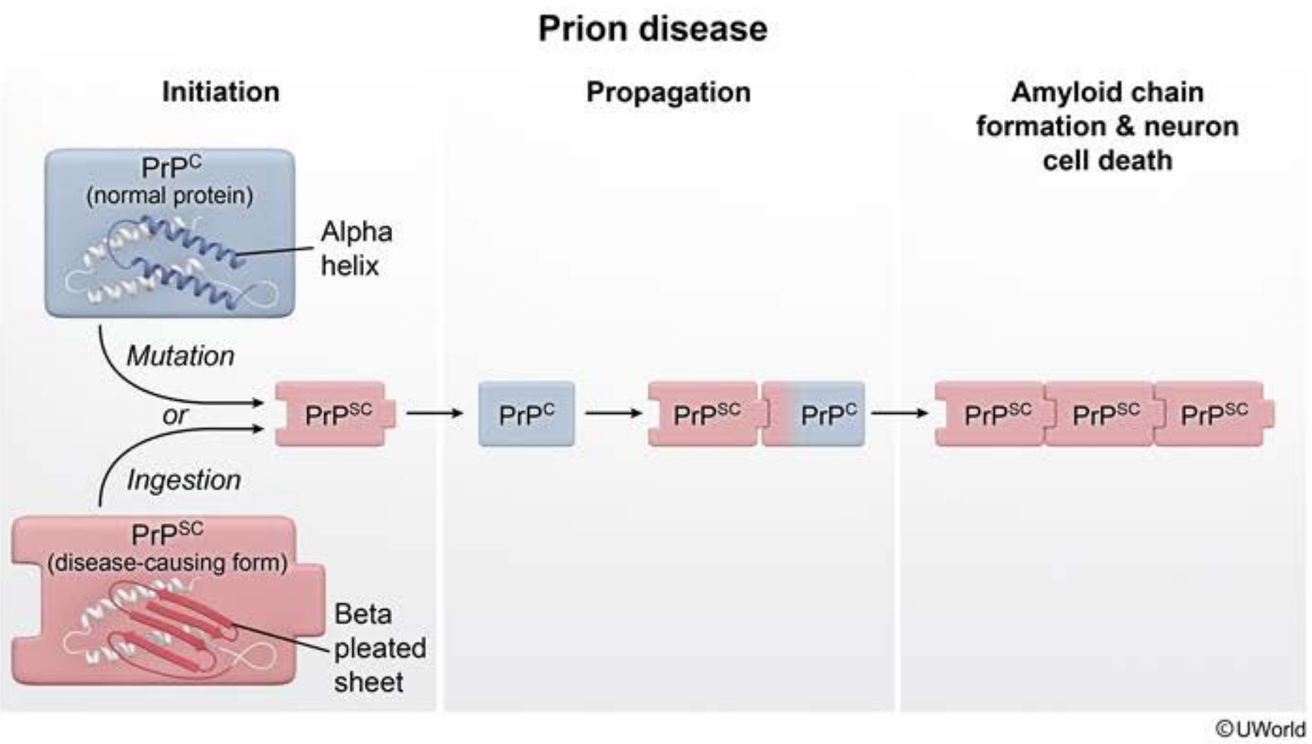

Zoom In | Zoom Out | Reset | Add To New Card | Existing Card

Settings

1 2 3 4 5 6 7 8 9 10 11 12 13 14 15 16 17 18 19 20 21 22 23 24 25 26 27 28 29 30

Item 29 of 40
Question Id: 1058

Mark | Previous | Next | Full Screen | Tutorial | Lab Values | Notes | Calculator | Reverse Color | Text Zoom | Settings

A 32-year-old man is brought to the emergency department due to weakness and tingling that started in his feet and is now at his knees. A week ago, the patient noticed that his legs felt weak while climbing stairs. Since then, the weakness has progressively worsened every day. Today, he fell twice when attempting to walk. Medical history is insignificant, except for a mild respiratory infection 2 weeks ago that resolved spontaneously. The patient does not use tobacco, alcohol, or illicit drugs. He takes no medications. Vital signs are within normal limits. Physical examination shows marked weakness in the distal muscles and moderate weakness in the proximal muscles in both legs. Deep tendon reflexes are absent at the knees. This patient's condition is most likely associated with which of the following?

A. Endomysial inflammatory infiltration

B. Endoneurial arteriole hyalinization

C. Endoneurial inflammatory infiltration

D. Mutations of a muscle structural protein gene

E. Toxin penetration through the blood-nerve barrier

Submit

Block Time Remaining: 00:01:05
TUTOR

3 | Feedback | Suspend | End Block

1 2 3 4 5 6 7 8 9 10 11 12 13 14 15 16 17 18 19 20 21 22 23 24 25 26 27 28 29 30

A 32-year-old man is brought to the emergency department due to weakness and tingling that started in his feet and is now at his knees. A week ago, the patient noticed that his legs felt weak while climbing stairs. Since then, the weakness has progressively worsened every day. Today, he fell twice when attempting to walk. Medical history is insignificant, except for a mild respiratory infection 2 weeks ago that resolved spontaneously. The patient does not use tobacco, alcohol, or illicit drugs. He takes no medications. Vital signs are within normal limits. Physical examination shows marked weakness in the distal muscles and moderate weakness in the proximal muscles in both legs. Deep tendon reflexes are absent at the knees. This patient's condition is most likely associated with which of the following?

A. Endomysial inflammatory infiltration (12%)

B. Endoneurial arteriole hyalinization (1%)

✓ C. Endoneurial inflammatory infiltration (76%)

D. Mutations of a muscle structural protein gene (1%)

E. Toxin penetration through the blood-nerve barrier (8%)

Omitted
Correct answer
C

76%
Answered correctly

02 secs
Time Spent

04/09/2020
Last Updated

Explanation

Guillain-Barré syndrome

1 2 3 4 5 6 7 8 9 10 11 12 13 14 15 16 17 18 19 20 21 22 23 24 25 26 27 28 29 30

A 32-year-old man is brought to the emergency department due to weakness and tingling that started in his feet and is now at his knees. A week ago, the patient noticed that his legs felt weak while climbing stairs. Since then, the weakness has progressively worsened every day. Today, he fell twice when attempting to walk. Medical history is insignificant, except for a mild respiratory infection 2 weeks ago that resolved spontaneously. The patient does not use tobacco, alcohol, or illicit drugs. He takes no medications. Vital signs are within normal limits. Physical examination shows marked weakness in the distal muscles and moderate weakness in the proximal muscles in both legs. Deep tendon reflexes are absent at the knees. This patient's condition is most likely associated with which of the following?

A. Endomysial inflammatory infiltration (12%)

B. Endoneurial arteriole hyalinization (1%)

✓ C. Endoneurial inflammatory infiltration (76%)

D. Mutations of a muscle structural protein gene (1%)

E. Toxin penetration through the blood-nerve barrier (8%)

Omitted
Correct answer
C

76%
Answered correctly

02 secs
Time Spent

04/09/2020
Last Updated

Explanation

Guillain-Barré syndrome

Settings

1 2 3 4 5 6 7 8 9 10 11 12 13 14 15 16 17 18 19 20 21 22 23 24 25 26 27 28 29 30

Item 29 of 40
Question Id: 1058

Mark | Previous | Next | Full Screen | Tutorial | Lab Values | Notes | Calculator | Reverse Color | Text Zoom | Settings

Guillain-Barré syndrome

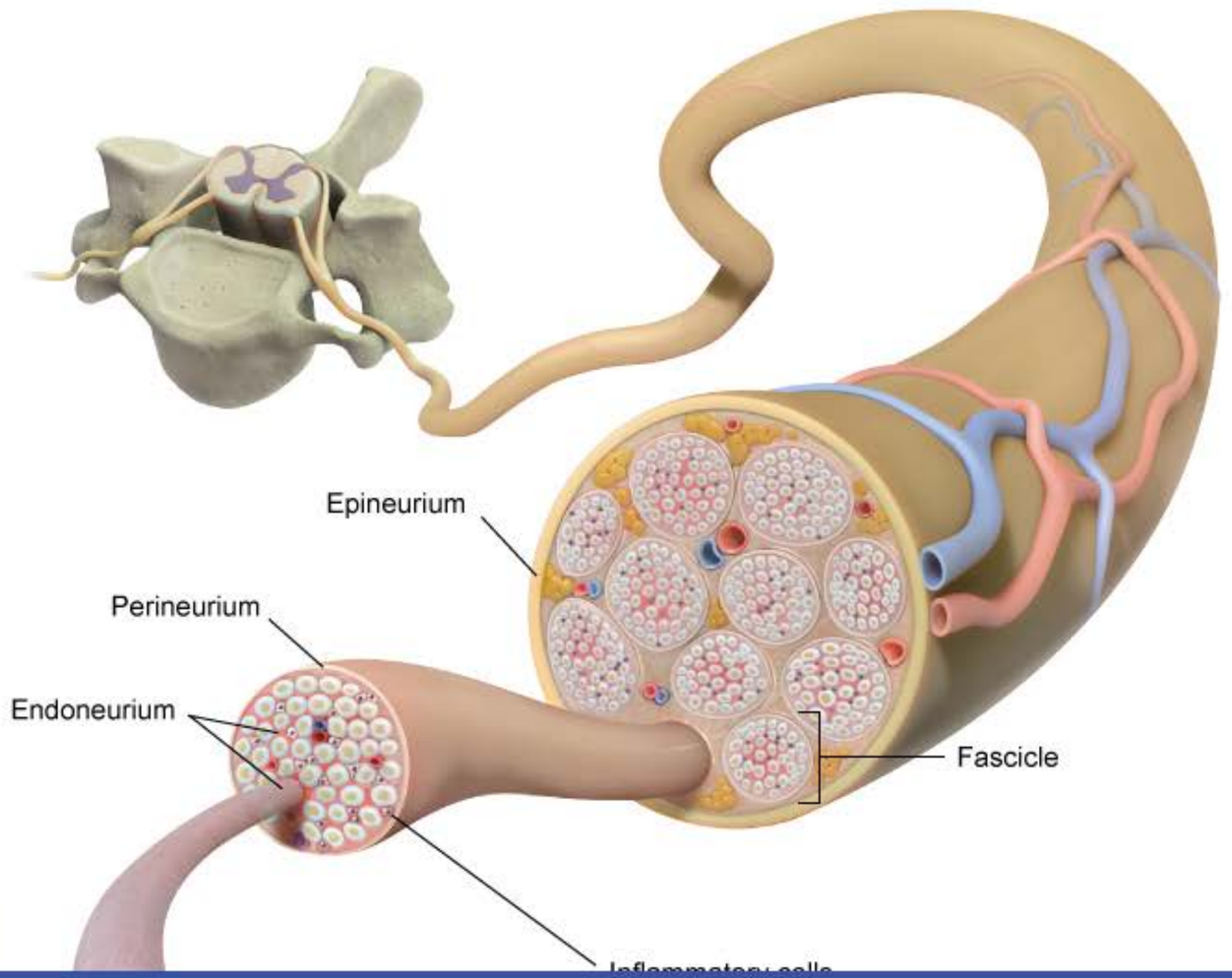

Block Time Remaining: 00:01:07
TUTOR

3 | Feedback | Suspend | End Block

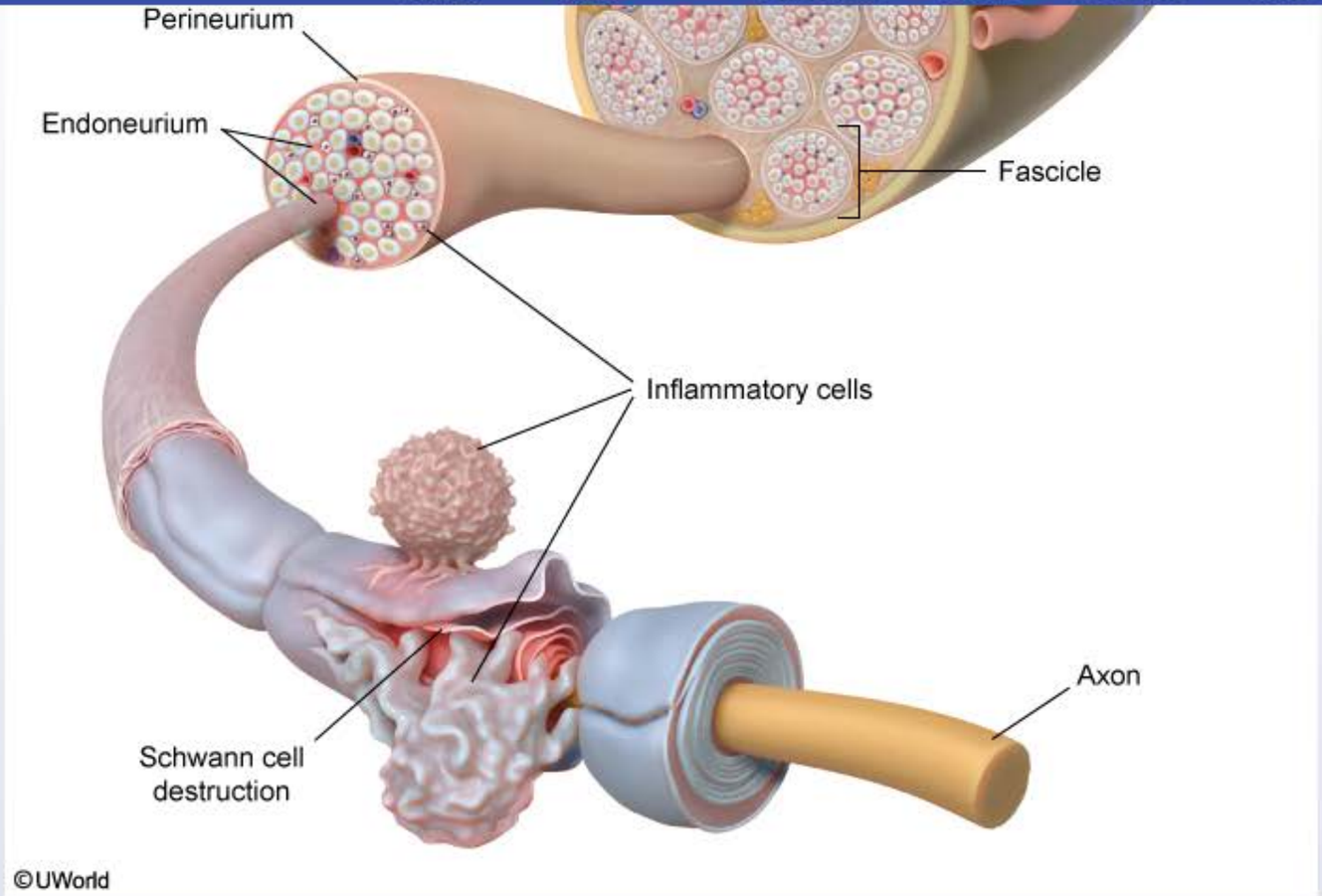

This patient has **ascending symmetric weakness** following a febrile illness, likely due to **Guillain-Barré syndrome** (GBS). GBS is an acute, immune-mediated, demyelinating polyneuropathy thought to be due to molecular mimicry; infectious antigens provoke an immune response that cross-reacts with the myelin of the spinal roots and peripheral nerves, resulting in demyelination of peripheral nerves. Patients develop a symmetric, ascending flaccid paralysis and areflexia leading to eventual respiratory failure; cranial nerve involvement can also occur. This is typically preceded by an upper respiratory viral illness or an episode of diarrhea (due to *Campylobacter jejuni*).

This patient has **ascending symmetric weakness** following a febrile illness, likely due to **Guillain-Barré syndrome** (GBS). GBS is an acute, immune-mediated, demyelinating polyneuropathy thought to be due to molecular mimicry; infectious antigens provoke an immune response that cross-reacts with the myelin of the spinal roots and peripheral nerves, resulting in demyelination of peripheral nerves. Patients develop a symmetric, ascending flaccid paralysis and areflexia leading to eventual respiratory failure; cranial nerve involvement can also occur. This is typically preceded by an upper respiratory viral illness or an episode of diarrhea (due to *Campylobacter jejuni*).

Histology demonstrates an **inflammatory infiltrate** located within the **endoneurium** (the innermost layer of connective tissue that surrounds a nerve axon and its corresponding blood vessel). The infiltrate, consisting largely of lymphocytes and macrophages, extends from the small vessels (perivenular) to the associated nerve axon. Macrophages strip the myelin sheath from the axon, and **lipid laden macrophages** are seen following the engulfment of myelin.

(Choice A) Endomysial inflammatory infiltration is characteristic of polymyositis (an immune-mediated inflammatory myopathy). Patients develop symmetric weakness; however, weakness is greater proximally than distally.

(Choice B) Hyalinization of the nerve arterioles leads to ischemic nerve injury and is a cause of diabetic neuropathy. However, this occurs over an extended time (decades) in patients with long-standing, uncontrolled diabetes.

(Choice D) Mutations in the gene that codes for the muscle protein dystrophin can cause either a complete absence of this protein (Duchenne muscular dystrophy) or its decreased synthesis (Becker muscular dystrophy). Both of these diseases cause progressive weakness and lead to eventual respiratory failure but weakness is worse proximally and patients present in early childhood with a waddling gait and calf enlargement.

(Choice E) *Corynebacterium diphtheriae* can cause neuropathies due to Diphtheria toxin penetration through the blood-nerve barrier; however, diphtheria usually presents as pharyngitis with pseudomembrane formation and stridor. In addition, the neuropathy typically affects the cranial nerves prior to the peripheral nerves.

Educational objective:
Guillain-Barré syndrome is an acute demyelinating polyneuropathy. It is thought to be due to molecular mimicry and is commonly preceded by an upper respiratory viral illness or gastroenteritis. Segmental demyelination of the peripheral nerves and an endoneural inflammatory infiltrate are seen on light microscopy.

Histology demonstrates an **inflammatory infiltrate** located within the **endoneurium** (the innermost layer of connective tissue that surrounds a nerve axon and its corresponding blood vessel). The infiltrate, consisting largely of lymphocytes and macrophages, extends from the small vessels (perivenular) to the associated nerve axon. Macrophages strip the myelin sheath from the axon, and **lipid laden macrophages** are seen following the engulfment of myelin.

(Choice A) Endomysial inflammatory infiltration is characteristic of polymyositis (an immune-mediated inflammatory myopathy). Patients develop symmetric weakness; however, weakness is greater proximally than distally.

(Choice B) Hyalinization of the nerve arterioles leads to ischemic nerve injury and is a cause of diabetic neuropathy. However, this occurs over an extended time (decades) in patients with long-standing, uncontrolled diabetes.

(Choice D) Mutations in the gene that codes for the muscle protein dystrophin can cause either a complete absence of this protein (Duchenne muscular dystrophy) or its decreased synthesis (Becker muscular dystrophy). Both of these diseases cause progressive weakness and lead to eventual respiratory failure but weakness is worse proximally and patients present in early childhood with a waddling gait and calf enlargement.

(Choice E) *Corynebacterium diphtheriae* can cause neuropathies due to Diphtheria toxin penetration through the blood-nerve barrier; however, diphtheria usually presents as pharyngitis with pseudomembrane formation and stridor. In addition, the neuropathy typically affects the cranial nerves prior to the peripheral nerves.

Educational objective:
Guillain-Barré syndrome is an acute demyelinating polyneuropathy. It is thought to be due to molecular mimicry and is commonly preceded by an upper respiratory viral illness or gastroenteritis. Segmental demyelination of the peripheral nerves and an endoneural inflammatory infiltrate are seen on light microscopy.

Pathology	Nervous System	Guillain Barre syndrome
Subject	System	Topic

Copyright © UWorld. All rights reserved.

Settings

1 2 3 4 5 6 7 8 9 10 11 12 13 14 15 16 17 18 19 20 21 22 23 24 25 26 27 28 29 30

Item 30 of 40
Question Id: 8859

Mark | Previous | Next | Full Screen | Tutorial | Lab Values | Notes | Calculator | Reverse Color | Text Zoom | Settings

A 32-year-old woman describes five episodes of intractable vomiting over the last year. The episodes last several hours and are associated with a sensation that the room is spinning or tilting. At these times, it is difficult for her to walk because she loses her balance. She cannot relate the timing of the episodes to any particular inciting event. Physical examination reveals stability in the Romberg position and during tandem walk. Proprioception is intact. Dysfunction of which of the following structures best explains this patient's symptoms?

- A. Posterior columns of the spinal cord
- B. Vagal nerve
- C. Optic tract
- D. Inner ear
- E. Cerebellum
- F. Frontal cortex

Submit

Block Time Remaining: 00:01:07
TUTOR

Feedback | Suspend | End Block

A 32-year-old woman describes five episodes of intractable vomiting over the last year. The episodes last several hours and are associated with a sensation that the room is spinning or tilting. At these times, it is difficult for her to walk because she loses her balance. She cannot relate the timing of the episodes to any particular inciting event. Physical examination reveals stability in the Romberg position and during tandem walk. Proprioception is intact. Dysfunction of which of the following structures best explains this patient's symptoms?

- A. Posterior columns of the spinal cord (0%)
- B. Vagal nerve (2%)
- C. Optic tract (0%)
- ✓ D. Inner ear (90%)
- E. Cerebellum (5%)
- F. Frontal cortex (0%)

Omitted
Correct answer
D

90%
Answered correctly

02 secs
Time Spent

02/28/2020
Last Updated

Explanation

This patient is experiencing vertigo due to vestibular dysfunction. Vertigo is a sensation of motion when no motion is present or an exaggerated sense of motion for a given bodily movement. It must be distinguished from other sensations that are often described by patients using similar terminology, such as imbalance, light-headedness, and syncope. Vertigo resulting from vestibular dysfunction tends to be of sudden onset,

This patient is experiencing vertigo due to vestibular dysfunction. Vertigo is a sensation of motion when no motion is present or an exaggerated sense of motion for a given bodily movement. It must be distinguished from other sensations that are often described by patients using similar terminology, such as imbalance, light-headedness, and syncope. Vertigo resulting from vestibular dysfunction tends to be of sudden onset, interfere with walking, and cause nausea and vomiting. Typical causes of vestibulopathy include Meniere's disease, perilymphatic fistulas, benign positional vertigo, labyrinthitis, and acoustic neuromas.

(Choice A) Disease of the posterior column of the spinal cord can occur in syphilis (i.e., tabes dorsalis) and vitamin B12 deficiency. Typical symptoms include ataxia, decreased proprioception and vibratory sense, and hyporeflexia. This patient's normal neurologic exam makes posterior column disease unlikely.

(Choice B) Vagal nerve damage can present as hoarseness, dysphagia, abnormal gastrointestinal motility, or tachycardia. Vagal nerve dysfunction will not cause vertigo.

(Choice C) Optic tract dysfunction will result in visual problems. Vision deficits do not typically cause vertigo, but may cause people to feel unsteady on their feet.

(Choice E) Cerebellar dysfunction presents as ataxia, imbalance, incoordination, and nystagmus. Patients with cerebellar dysfunction will be unable to perform tandem walking due to their imbalance.

(Choice F) The frontal cortex controls executive functions and response inhibition. Damage to the frontal cortex results in "frontal release" symptoms, such as personality change, inability to organize or plan, and disinhibition.

Educational Objective:
Vertigo is a sensation of excessive motion compared to physical reality. It is most commonly due to dysfunction within the vestibular system.

Pathology	Nervous System	Vertigo
Subject	System	Topic

Copyright © UWorld. All rights reserved.

Settings

1 2 3 4 5 6 7 8 9 10 11 12 13 14 15 16 17 18 19 20 21 22 23 24 25 26 27 28 29 30

Item 31 of 40
Question Id: 632

Mark | Previous | Next | Full Screen | Tutorial | Lab Values | Notes | Calculator | Reverse Color | Text Zoom | Settings

A 42-year-old woman comes to the office with her husband for evaluation of abnormal movements. The patient has been having involuntary facial grimaces and extremity fidgeting. She has no prior medical or psychiatric conditions, but her husband says she has had frequent anger outbursts over the past year. The patient takes no medications. She smoked cigarettes and used illicit drugs for several years during college but not since then. Her father died of a neurological disorder at age 55. Physical examination shows intermittent, fidgety, jerky movements of the hands. MRI of the brain is ordered. Which of the following neuroimaging findings is most likely to be seen in this patient?

A. Diffuse ventriculomegaly without sulcal widening

B. Enlargement of frontal horns of the lateral ventricles

C. Hypoplastic vermis with a dilated fourth ventricle

D. Pronounced atrophy of bilateral hippocampi

E. Regional atrophy of frontal and temporal lobes

Submit

Block Time Remaining: 00:01:09
TUTOR

3 | Feedback | Suspend | End Block

A 42-year-old woman comes to the office with her husband for evaluation of abnormal movements. The patient has been having involuntary facial grimaces and extremity fidgeting. She has no prior medical or psychiatric conditions, but her husband says she has had frequent anger outbursts over the past year. The patient takes no medications. She smoked cigarettes and used illicit drugs for several years during college but not since then. Her father died of a neurological disorder at age 55. Physical examination shows intermittent, fidgety, jerky movements of the hands. MRI of the brain is ordered. Which of the following neuroimaging findings is most likely to be seen in this patient?

- A. Diffuse ventriculomegaly without sulcal widening (16%)
- ✓ B. Enlargement of frontal horns of the lateral ventricles (44%)
- C. Hypoplastic vermis with a dilated fourth ventricle (3%)
- D. Pronounced atrophy of bilateral hippocampi (9%)
- E. Regional atrophy of frontal and temporal lobes (25%)

Omitted
Correct answer
B

44%
Answered correctly

01 sec
Time Spent

03/31/2020
Last Updated

Explanation

Huntington disease features	
	• Autosomal dominant inheritance • Increased number of CAG repeats in *HTT* gene

Huntington disease features	
Pathogenesis	• Autosomal dominant inheritance • Increased number of CAG repeats in *HTT* gene • Anticipation: earlier onset, more severe disease in subsequent generations • Gain of function mutation: protein accumulation toxic to neurons • Decrease in GABA and acetylcholine in caudate nuclei
Clinical features	• Chorea: involuntary, jerky movements of face and extremities • Behavioral abnormalities (eg, aggressiveness, depression) • Progressive dementia
Confirmatory testing	• Neuroimaging: caudate atrophy with enlargement of the lateral ventricles • Genetic testing for # of CAG repeats

This patient with chorea (eg, fidgety, jerky, involuntary movements), behavioral abnormalities (eg, outbursts of anger), and a family history of a fatal neurological disease likely has **Huntington disease** (HD). HD is an autosomal dominant, progressive neurodegenerative disorder that results in the production and accumulation of abnormal huntingtin protein, which is toxic to neurons.

Although patients with HD display generalized cortical **atrophy** as the disease progresses, the most prominent atrophy is seen bilaterally in the **caudate nucleus** and putamen, leading to the **enlargement** of the frontal horns of the **lateral ventricles**. The loss of inhibitory GABAergic neurons in these areas causes decreased regulation of the movement and behavioral centers of the cerebral cortex, resulting in the characteristic constellation of symptoms in patients with HD.

(Choice A) Diffuse ventriculomegaly *without sulcal widening* is seen in normal pressure hydrocephalus (eg, urinary incontinence, gait disturbance, cognitive impairment) due to an increase in cerebrospinal fluid volume. In contrast, neurodegenerative disorders such as Huntington disease typically present with both ventriculomegaly and sulcal widening due to generalized cortical atrophy.

(Choice C) A hypoplastic cerebellar vermis with cystic dilation of the fourth ventricle and a posterior fossa cyst is characteristic of congenital

fatal neurological disease likely has **Huntington disease** (HD). HD is an autosomal dominant, progressive neurodegenerative disorder that results in the production and accumulation of abnormal huntingtin protein, which is toxic to neurons.

Although patients with HD display generalized cortical **atrophy** as the disease progresses, the most prominent atrophy is seen bilaterally in the **caudate nucleus** and putamen, leading to the **enlargement** of the frontal horns of the **lateral ventricles**. The loss of inhibitory GABAergic neurons in these areas causes decreased regulation of the movement and behavioral centers of the cerebral cortex, resulting in the characteristic constellation of symptoms in patients with HD.

(Choice A) Diffuse ventriculomegaly *without sulcal widening* is seen in normal pressure hydrocephalus (eg, urinary incontinence, gait disturbance, cognitive impairment) due to an increase in cerebrospinal fluid volume. In contrast, neurodegenerative disorders such as Huntington disease typically present with both ventriculomegaly and sulcal widening due to generalized cortical atrophy.

(Choice C) A hypoplastic cerebellar vermis with cystic dilation of the fourth ventricle and a posterior fossa cyst is characteristic of congenital Dandy-Walker malformation. Although the diagnosis of Dandy-Walker malformation can be delayed into early adulthood, patients typically have a long history of chronic headaches and neurologic abnormalities (eg, unsteady gait, facial palsy).

(Choices D and E) Early-onset Alzheimer disease (eg, bilateral hippocampal atrophy) or frontotemporal dementia (eg, frontal/temporal lobe atrophy) can present in patients as early as the fourth decade. However, changes in memory, speech, or behavior are the predominant symptoms at presentation; movement abnormalities (eg, myoclonus, akinesia, hyperreflexia) typically develop later in the disease course.

Educational objective:
Huntington disease is an autosomal dominant neurodegenerative disorder that manifests with chorea (eg, involuntary, jerky, fidgety movements) and behavioral abnormalities (eg, aggressiveness, depression). Characteristic neuroimaging findings include atrophy of the caudate nuclei which results in enlargement of the frontal horns of the lateral ventricles.

Pathology	Nervous System	Huntington disease
Subject	System	Topic

Copyright © UWorld. All rights reserved.

fatal neurological disease likely has **Huntington disease** (HD). HD is an autosomal dominant, progressive neurodegenerative disorder that

Exhibit Display

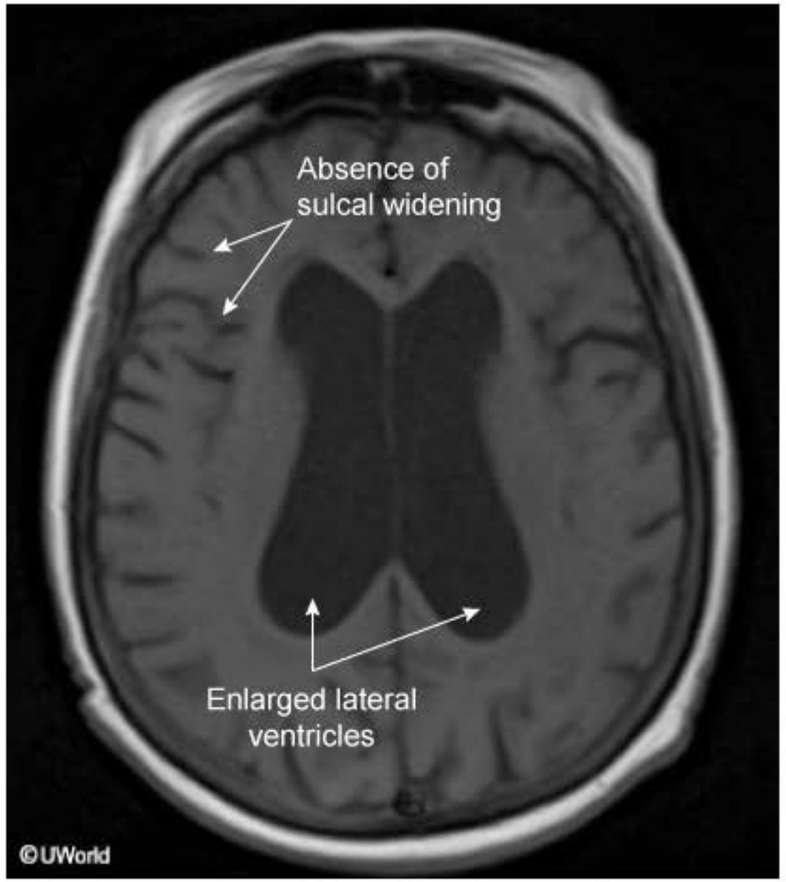

Zoom In | Zoom Out | Reset | Add To New Card | Existing Card

Settings

1 2 3 4 5 6 7 8 9 10 11 12 13 14 15 16 17 18 19 20 21 22 23 24 25 26 27 28 29 30

Item 32 of 40
Question Id: 65

Mark | Previous | Next | Full Screen | Tutorial | Lab Values | Notes | Calculator | Reverse Color | Text Zoom | Settings

A 65-year-old woman was found dead in her house. The family notes that she had difficulty walking over the past few months. The patient had a history of atrial fibrillation treated with anticoagulation therapy. Gross examination shows bruising of the scalp. Autopsy reveals a large epidural hemorrhage with brain herniation; spinal cord evaluation reveals symmetric myelin layer vacuolization and axonal degeneration involving the posterior columns and the lateral corticospinal tracts. Which of the following is the most likely cause of this patient's spinal cord findings?

- A. Amyotrophic lateral sclerosis
- B. Multiple sclerosis
- C. Syringomyelia
- D. Tabes dorsalis
- E. Thiamine deficiency
- F. Varicella-zoster virus infection
- G. Vitamin B_{12} deficiency

Submit

Block Time Remaining: 00:01:10
TUTOR

3 | Feedback | Suspend | End Block

Settings

1 2 3 4 5 6 7 8 9 10 11 12 13 14 15 16 17 18 19 20 21 22 23 24 25 26 27 28 29 30

Item 32 of 40
Question Id: 65

Mark | Previous | Next | Full Screen | Tutorial | Lab Values | Notes | Calculator | Reverse Color | Text Zoom | Settings

A 65-year-old woman was found dead in her house. The family notes that she had difficulty walking over the past few months. The patient had a history of atrial fibrillation treated with anticoagulation therapy. Gross examination shows bruising of the scalp. Autopsy reveals a large epidural hemorrhage with brain herniation; spinal cord evaluation reveals symmetric myelin layer vacuolization and axonal degeneration involving the posterior columns and the lateral corticospinal tracts. Which of the following is the most likely cause of this patient's spinal cord findings?

- A. Amyotrophic lateral sclerosis (10%)
- B. Multiple sclerosis (6%)
- C. Syringomyelia (4%)
- D. Tabes dorsalis (10%)
- E. Thiamine deficiency (2%)
- F. Varicella-zoster virus infection (0%)
- ✓ G. Vitamin B_{12} deficiency (66%)

Omitted
Correct answer
G

66%
Answered correctly

02 secs
Time Spent

04/20/2020
Last Updated

Explanation

Major fiber tracts of the spinal cord

Block Time Remaining: 00:01:12
TUTOR

3 | Feedback | Suspend | End Block

Settings

1 2 3 4 5 6 7 8 9 10 11 12 13 14 15 16 17 18 19 20 21 22 23 24 25 26 27 28 29 30

Item 32 of 40
Question Id: 65

Mark | Previous | Next | Full Screen | Tutorial | Lab Values | Notes | Calculator | Reverse Color | Text Zoom | Settings

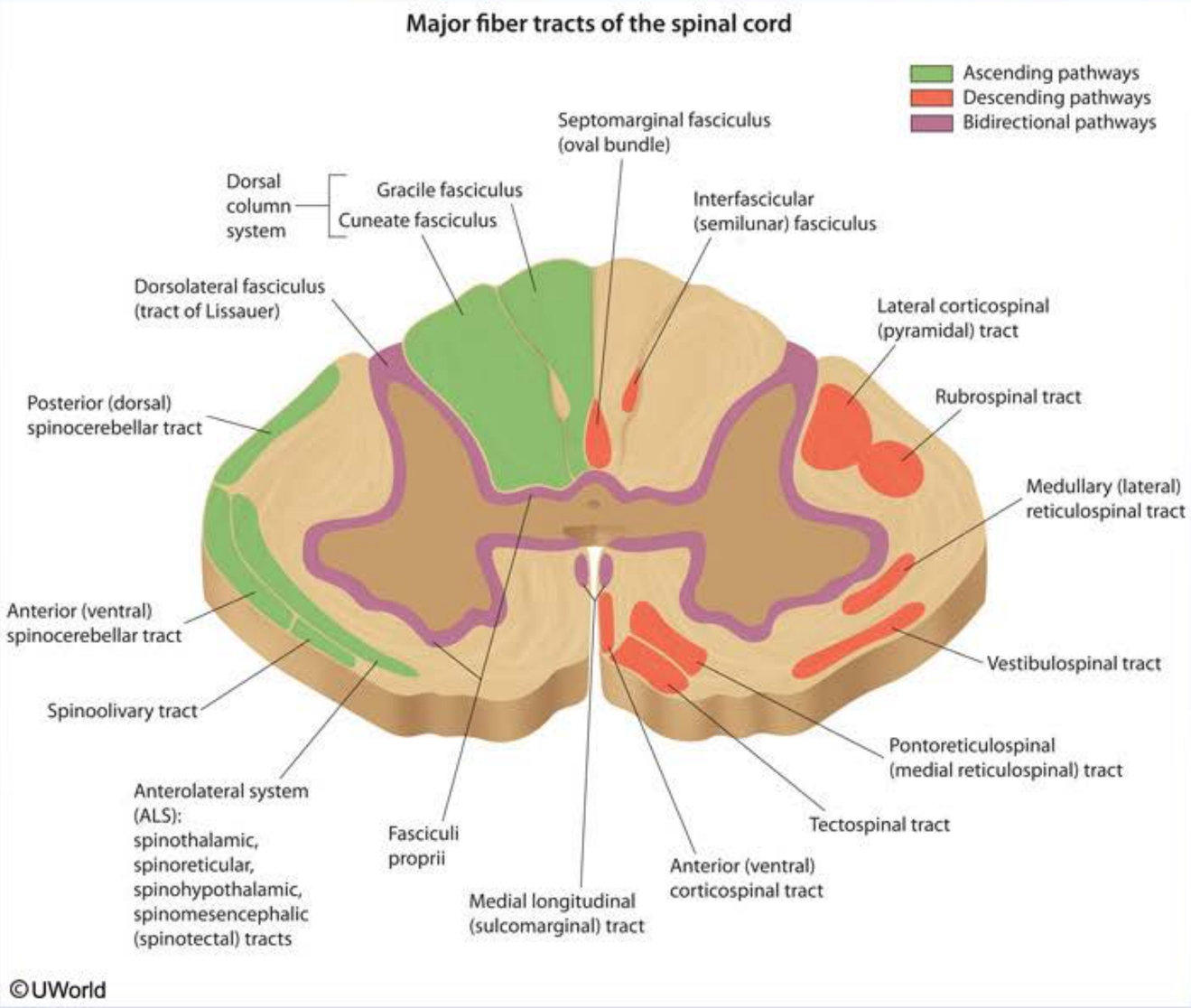

Block Time Remaining: 00:01:12
TUTOR

3 | Feedback | Suspend | End Block

This patient's history of gait dysfunction and evidence of myelin/axonal degeneration in the dorsal columns and corticospinal tract are highly suggestive of **vitamin B_{12} deficiency**. Vitamin B_{12} is an essential dietary nutrient that contributes to DNA synthesis and repair (via reduction of 5-methyltetrahydrofolate to tetrahydrofolate) and to the generation/maintenance of myelin (via methylation of neuronal lipids and proteins). Although deficiency often presents with **megaloblastic anemia** (due to impaired nuclear maturation of rapidly dividing hematologic cells), many patients develop **neurologic manifestations** due to:

- damage to the dorsal column of the spinal cord, leading to bilateral loss of position and vibration sensation. This commonly results in gait dysfunction, particularly when the patient's eyes are closed (sensory ataxia)
- damage to the lateral corticospinal tracts, leading to upper motor neuron signs (eg, spastic paresis) and positive Babinski sign
- axonal degeneration of the peripheral nerves, leading to numbness, paresthesia, and depressed motor reflexes

The spinal cord damage seen with vitamin B_{12} deficiency is called **subacute combined degeneration**; "combined" refers to the **degeneration** of ascending pathways (**dorsal columns**) and descending pathways (**corticospinal tract**).

(Choice A) Amyotrophic lateral sclerosis is marked by progressive upper and lower motor neuron signs. Although damage to the lateral corticospinal tract often occurs, the dorsal columns are generally spared. Most cases present with asymmetric limb weakness, atrophy, and fasciculation due to anterior horn damage.

(Choice B) Multiple sclerosis usually causes focal demyelinated plaques within the central nervous system. These are typically asymmetric and in different phases of evolution. This patient's symmetric degeneration of the dorsal columns and corticospinal tract would be unusual.

(Choice C) Syringomyelia, a cyst within the spinal cord, can expand over time, leading to central spinal cord injury. The corticospinal tracts and anterior horn are often affected (eg, flaccid paralysis, atrophy). However, syringomyelia would likely be identified on gross autopsy.

(Choice D) Tabes dorsalis (a form of neurosyphilis) is associated with damage to the dorsal columns and dorsal nerve roots, leading to loss of position and vibration sensation, sensory gait ataxia, and paresthesia of the extremities. However, the lateral corticospinal tracts are not generally affected.

(Choice E) Thiamine deficiency causes Wernicke encephalopathy, which often manifests with gait dysfunction, confusion, and oculomotor impairment. However, histopathology generally shows demyelination in the brain (eg, mamillary bodies, thalamus, ocular motor nuclei), not

corticospinal tract often occurs, the dorsal columns are generally spared. Most cases present with asymmetric limb weakness, atrophy, and fasciculation due to anterior horn damage.

(Choice B) Multiple sclerosis usually causes focal demyelinated plaques within the central nervous system. These are typically asymmetric and in different phases of evolution. This patient's symmetric degeneration of the dorsal columns and corticospinal tract would be unusual.

(Choice C) Syringomyelia, a cyst within the spinal cord, can expand over time, leading to central spinal cord injury. The corticospinal tracts and anterior horn are often affected (eg, flaccid paralysis, atrophy). However, syringomyelia would likely be identified on gross autopsy.

(Choice D) Tabes dorsalis (a form of neurosyphilis) is associated with damage to the dorsal columns and dorsal nerve roots, leading to loss of position and vibration sensation, sensory gait ataxia, and paresthesia of the extremities. However, the lateral corticospinal tracts are not generally affected.

(Choice E) Thiamine deficiency causes Wernicke encephalopathy, which often manifests with gait dysfunction, confusion, and oculomotor impairment. However, histopathology generally shows demyelination in the brain (eg, mamillary bodies, thalamus, ocular motor nuclei), not corticospinal tracts and dorsal columns.

(Choice F) Varicella-zoster virus infection can cause painful neuritis in the peripheral nervous system. Central nervous system lesions are less common.

Educational objective:
Myelopathy associated with vitamin B_{12} deficiency is called subacute combined degeneration. "Combined" refers to myelin degeneration of both the ascending (dorsal columns) and descending (corticospinal tract) pathways. Loss of position and vibration sensation, sensory ataxia, and spastic paresis are common manifestations.

Pathology	Nervous System	Vitamin b12 deficiency
Subject	System	Topic

Copyright © UWorld. All rights reserved.

Settings

1 2 3 4 5 6 7 8 9 10 11 12 13 14 15 16 17 18 19 20 21 22 23 24 25 26 27 28 29 30

Item 33 of 40
Question Id: 19

Mark | Previous | Next | Full Screen | Tutorial | Lab Values | Notes | Calculator | Reverse Color | Text Zoom | Settings

An 82-year-old man is found unresponsive by his neighbor. The patient lives alone in his suburban home. When the neighbor went to check on him, the patient was on the floor and not answering any questions. His medical history is unknown. On arrival of emergency medical services, the patient is obtunded and responds only to painful stimuli. Supportive measures are begun, including endotracheal intubation, but the patient dies en route to the hospital. Autopsy reveals extensive atherosclerotic disease involving the coronary and internal carotid arteries. Histopathologic examination of the brain in the right middle cerebral artery territory shows neurons with intensely eosinophilic cytoplasm and nuclear fragmentation. Based on these findings, this patient's cerebral injury most likely occurred approximately how long ago?

- A. Less than an hour
- B. 12-24 hours
- C. 1-2 weeks
- D. 2 months
- E. 2 years

Submit

Block Time Remaining: 00:01:12
TUTOR

3 | Feedback | Suspend | End Block

Settings

1 2 3 4 5 6 7 8 9 10 11 12 13 14 15 16 17 18 19 20 21 22 23 24 25 26 27 28 29 30

Item 33 of 40
Question Id: 19

Mark | Previous | Next | Full Screen | Tutorial | Lab Values | Notes | Calculator | Reverse Color | Text Zoom | Settings

An 82-year-old man is found unresponsive by his neighbor. The patient lives alone in his suburban home. When the neighbor went to check on him, the patient was on the floor and not answering any questions. His medical history is unknown. On arrival of emergency medical services, the patient is obtunded and responds only to painful stimuli. Supportive measures are begun, including endotracheal intubation, but the patient dies en route to the hospital. Autopsy reveals extensive atherosclerotic disease involving the coronary and internal carotid arteries. Histopathologic examination of the brain in the right middle cerebral artery territory shows neurons with intensely eosinophilic cytoplasm and nuclear fragmentation. Based on these findings, this patient's cerebral injury most likely occurred approximately how long ago?

- A. Less than an hour (12%)
- ✓ B. 12-24 hours (82%)
- C. 1-2 weeks (4%)
- D. 2 months (0%)
- E. 2 years (0%)

Omitted
Correct answer
B

82%
Answered correctly

01 sec
Time Spent

07/04/2020
Last Updated

Explanation

Ischemic stroke		
Time after		

Block Time Remaining: 00:01:13
TUTOR

3 | Feedback | Suspend | End Block

Ischemic stroke		
Time after injury	**Microscopic changes**	**Macroscopic changes**
12-24 hours	Red neurons (eosinophilic cytoplasm, pyknotic nuclei, loss of Nissl substance)	
24-72 hours	Neutrophilic infiltration	
3-7 days	Macrophage/microglia infiltration & phagocytosis begins	
1-2 weeks	Reactive gliosis & vascular proliferation around the necrotic area	Liquefactive necrosis (1 week-1 month)
>2 weeks	Glial scar formation	Cystic area surrounded by dense glial fibers (>1 month)

This patient was found unconscious, in rapid hemodynamic decline, an unknown amount of time after an inciting cardiovascular event. The autopsy demonstrates histopathologic evidence of **ischemic stroke** caused by widespread atherosclerosis. Sustained interruption in blood circulation to branches of the internal carotid arteries (eg, middle cerebral artery) can lead to tissue hypoxia and **irreversible cellular injury** with characteristic microscopic and macroscopic changes.

Specific findings vary with time but follow a predictable course. **Red neurons** are typically seen **12-24 hours** after irreversible ischemic injury and are characterized by intense **eosinophilic staining** of the cytoplasm due to dissolution of **Nissl bodies** (basophilic granules consisting of rough endoplasmic reticulum and ribosomes). The nuclei also become pyknotic (eg, shrunken and deeply basophilic) and undergo **fragmentation** (karyorrhexis). After about a day, the tissue damage promotes neutrophil infiltration, followed by macrophage/microglial recruitment a few days later.

(Choice A) There is typically little change in the microscopic or macroscopic appearance of brain tissue <1 hour after irreversible ischemic injury.

circulation to branches of the internal carotid arteries (eg, middle cerebral artery) can lead to tissue hypoxia and **irreversible cellular injury** with characteristic microscopic and macroscopic changes.

Specific findings vary with time but follow a predictable course. **Red neurons** are typically seen **12-24 hours** after irreversible ischemic injury and are characterized by intense **eosinophilic staining** of the cytoplasm due to dissolution of **Nissl bodies** (basophilic granules consisting of rough endoplasmic reticulum and ribosomes). The nuclei also become pyknotic (eg, shrunken and deeply basophilic) and undergo **fragmentation** (karyorrhexis). After about a day, the tissue damage promotes neutrophil infiltration, followed by macrophage/microglial recruitment a few days later.

(Choice A) There is typically little change in the microscopic or macroscopic appearance of brain tissue <1 hour after irreversible ischemic injury.

(Choice C) At 1-2 weeks, there will be robust phagocytosis of neuron and myelin breakdown products by activated macrophages/microglia. Around this time, astrocytes start proliferating with the development of a network of cytoplasmic extensions (reactive gliosis), and new vessels are formed in the periphery of the necrotic area.

(Choices D and E) Several months to years after brain infarction, the necrotic area appears as a cystic cavity surrounded by a wall of dense fibers formed by astrocytic processes (glial scar).

Educational objective:
Inadequate blood supply to the brain (eg, arterial thrombosis or embolism) leads to ischemic stroke. The first microscopic changes are typically seen 12-24 hours after irreversible ischemic injury and include intense eosinophilic staining of the neuronal cytoplasm (red neurons) and nuclear fragmentation.

References

- Histopathological changes in acute ischemic stroke.

Pathology	Nervous System	Ischemic stroke
Subject	System	Topic

Copyright © UWorld. All rights reserved.

Settings

1 2 3 4 5 6 7 8 9 10 11 12 13 14 15 16 17 18 19 20 21 22 23 24 25 26 27 28 29 30

Item 34 of 40
Question Id: 1260

Mark | Previous | Next | Full Screen | Tutorial | Lab Values | Notes | Calculator | Reverse Color | Text Zoom | Settings

A 43-year-old male with advanced HIV is hospitalized for evaluation of recent-onset headaches and personality changes. Imaging of the brain shows a solitary mass within the temporal lobe. Biopsy of the mass reveals uniform cells containing the Epstein-Barr virus genome. This patient most likely suffers from which of the following?

- A. Pilocytic astrocytoma
- B. Glioblastoma
- C. Oligodendroglioma
- D. Ependymoma
- E. Medulloblastoma
- F. Primary CNS lymphoma
- G. Meningioma
- H. Craniopharyngioma
- I. Schwannoma
- J. Pituitary adenoma

Submit

Block Time Remaining: 00:01:13
TUTOR

1 | Feedback | Suspend | End Block

Settings

1 2 3 4 5 6 7 8 9 10 11 12 13 14 15 16 17 18 19 20 21 22 23 24 25 26 27 28 29 30

Item 34 of 40
Question Id: 1260

Mark | Previous | Next | Full Screen | Tutorial | Lab Values | Notes | Calculator | Reverse Color | Text Zoom | Settings

A 43-year-old male with advanced HIV is hospitalized for evaluation of recent-onset headaches and personality changes. Imaging of the brain shows a solitary mass within the temporal lobe. Biopsy of the mass reveals uniform cells containing the Epstein-Barr virus genome. This patient most likely suffers from which of the following?

- A. Pilocytic astrocytoma
- B. Glioblastoma
- C. Oligodendroglioma
- D. Ependymoma
- E. Medulloblastoma
- F. Primary CNS lymphoma
- G. Meningioma
- H. Craniopharyngioma
- I. Schwannoma
- J. Pituitary adenoma

Submit

Block Time Remaining: 00:01:15
TUTOR

1 | Feedback | Suspend | End Block

Settings

1 2 3 4 5 6 7 8 9 10 11 12 13 14 15 16 17 18 19 20 21 22 23 24 25 26 27 28 29 30

Item 34 of 40
Question Id: 1260

Mark | Previous | Next | Full Screen | Tutorial | Lab Values | Notes | Calculator | Reverse Color | Text Zoom | Settings

A 43-year-old male with advanced HIV is hospitalized for evaluation of recent-onset headaches and personality changes. Imaging of the brain shows a solitary mass within the temporal lobe. Biopsy of the mass reveals uniform cells containing the Epstein-Barr virus genome. This patient most likely suffers from which of the following?

- A. Pilocytic astrocytoma (1%)
- B. Glioblastoma (4%)
- C. Oligodendroglioma (2%)
- D. Ependymoma (1%)
- E. Medulloblastoma (1%)
- ✓ F. Primary CNS lymphoma (80%)
- G. Meningioma (2%)
- H. Craniopharyngioma (2%)
- I. Schwannoma (1%)
- J. Pituitary adenoma (0%)

Omitted
Correct answer
F

80%
Answered correctly

03 secs
Time Spent

04/22/2020
Last Updated

Block Time Remaining: 00:01:16
TUTOR

1 | Feedback | Suspend | End Block

Explanation

The most frequent CNS tumor in immunosuppressed patients is a primary CNS lymphoma. This CNS tumor is commonly associated with AIDS.

Primary CNS lymphomas appear microscopically as dense, cellular aggregates of uniform, atypical lymphoid cells. The majority of primary CNS lymphomas arise from B-cells. Diffuse large B-cell lymphoma is the most common subtype. The cells of CNS lymphomas are commonly positive for the B-cell markers CD20 and CD79a.

Primary CNS lymphomas are universally associated with the Epstein-Barr virus (EBV). The clinical presentation is non-specific. Mental status changes, seizures, or progressive focal neurologic deficits may occur. Most of CNS lymphomas are high-grade and respond poorly to chemotherapy.

(Choice G) Meningiomas are not associated with immunosuppressive diseases, nor are they associated with EBV. Meningiomas are located adjacent to the brain surface and are attached to the dura mater.

(Choice H) Craniopharyngiomas are located in the suprasellar region and can be calcified. Craniopharyngiomas can cause visual disturbances and endocrinopathies (such as hypopituitarism).

(Choice I) Intracranial schwannomas are most commonly located at the cerebellopontine angle. They cause symptoms of CN VIII compression (hearing loss, tinnitus, loss of balance).

Educational Objective:
Primary CNS lymphomas occur in immunosuppressed patients, such as those suffering from AIDS. These tumors arise from B cells and are universally associated with EBV. They are high-grade tumors with a poor prognosis.

Pathology	Nervous System	Cns lymphoma
Subject	System	Topic

Copyright © UWorld. All rights reserved.

Settings

1 2 3 4 5 6 7 8 9 10 11 12 13 14 15 16 17 18 19 20 21 22 23 24 25 26 27 28 29 30

Item 35 of 40
Question Id: 634

Mark | Previous | Next | Full Screen | Tutorial | Lab Values | Notes | Calculator | Reverse Color | Text Zoom | Settings

A 36-year-old Caucasian male presents to your office complaining of periodic involuntary deviation of the head to the right, accompanied by muscle pain in his neck. The spells start spontaneously, last 30-40 minutes, and can sometimes be suppressed by placing a hand on the chin. This patient's condition can be best characterized as which of the following?

A. Myoclonus
B. Cogwheel rigidity
C. Bradykinesia
D. Chorea
E. Dystonia
F. Hemiballism

Submit

Block Time Remaining: 00:01:16
TUTOR

2 | Feedback | Suspend | End Block

A 36-year-old Caucasian male presents to your office complaining of periodic involuntary deviation of the head to the right, accompanied by muscle pain in his neck. The spells start spontaneously, last 30-40 minutes, and can sometimes be suppressed by placing a hand on the chin. This patient's condition can be best characterized as which of the following?

- A. Myoclonus (26%)
- B. Cogwheel rigidity (3%)
- C. Bradykinesia (1%)
- D. Chorea (6%)
- ✓ E. Dystonia (55%)
- F. Hemiballism (6%)

Omitted
Correct answer
E

55%
Answered correctly

01 sec
Time Spent

04/25/2020
Last Updated

Explanation

Dystonia is a neurological movement disorder characterized by sustained, involuntary muscle contractions, which force certain parts of the body into abnormal, sometimes painful, movements or postures. These movements may affect a single muscle, a group of muscles, or the entire body. Dystonias may occur without any obvious cause (idiopathic).

Focal dystonias involve one muscle or a muscle group. Cervical dystonia, also called **spasmodic torticollis**, is the most common of the focal

Dystonia is a neurological movement disorder characterized by sustained, involuntary muscle contractions, which force certain parts of the body into abnormal, sometimes painful, movements or postures. These movements may affect a single muscle, a group of muscles, or the entire body. Dystonias may occur without any obvious cause (idiopathic).

Focal dystonias involve one muscle or a muscle group. Cervical dystonia, also called **spasmodic torticollis**, is the most common of the focal dystonias.

Blepharospasm is the second most common focal dystonia. It is an involuntary, forcible closure of the eyelids. The initial symptom is often uncontrollable blinking. Later, blepharospasm may cause complete closure of the eyelids. Another common type of focal dystonia is a **writer's cramp**, which affects the muscles of the hand.

(Choice A) Myoclonus is a sudden, brief, sometimes severe (shock-like) muscle contraction. Examples of physiologic myoclonus are hiccups and hypnic jerks (occur when falling asleep). Pathological myoclonus is seen in epilepsy and Creutzfeldt-Jakob disease.

(Choice B) On passive extension/flexion of a Parkinsonian limb, the examiner will feel intermittent resistance. This "ratchet-like" resistance to movement is called cogwheel rigidity.

(Choice C) Bradykinesia means slow movement. It is also commonly seen in Parkinson disease.

(Choice D) Chorea is involuntary muscle activity that "flows" from one muscle group to another. Movements may appear fragmented or jerky, and the patient may display a "dancing" gait (Greek, chorea = dance). Chorea is a feature of Huntington disease.

(Choice F) Hemiballism refers to flinging of the limbs (arm and/or leg) on one side of the body. Hemiballism occurs due to contralateral injury in or near the subthalamic nucleus.

Educational Objective:
Dystonia is a syndrome of prolonged, repetitive muscle contractions. This condition may be the result of impaired function of the basal ganglia. Cervical dystonia (spasmodic torticollis), blepharospasm, and writer's cramp are the most common types of focal dystonia.

Focal dystonias involve one muscle or a muscle group. Cervical dystonia, also called **spasmodic torticollis**, is the most common of the focal dystonias.

Blepharospasm is the second most common focal dystonia. It is an involuntary, forcible closure of the eyelids. The initial symptom is often uncontrollable blinking. Later, blepharospasm may cause complete closure of the eyelids. Another common type of focal dystonia is a **writer's cramp**, which affects the muscles of the hand.

(Choice A) Myoclonus is a sudden, brief, sometimes severe (shock-like) muscle contraction. Examples of physiologic myoclonus are hiccups and hypnic jerks (occur when falling asleep). Pathological myoclonus is seen in epilepsy and Creutzfeldt-Jakob disease.

(Choice B) On passive extension/flexion of a Parkinsonian limb, the examiner will feel intermittent resistance. This "ratchet-like" resistance to movement is called cogwheel rigidity.

(Choice C) Bradykinesia means slow movement. It is also commonly seen in Parkinson disease.

(Choice D) Chorea is involuntary muscle activity that "flows" from one muscle group to another. Movements may appear fragmented or jerky, and the patient may display a "dancing" gait (Greek, chorea = dance). Chorea is a feature of Huntington disease.

(Choice F) Hemiballism refers to flinging of the limbs (arm and/or leg) on one side of the body. Hemiballism occurs due to contralateral injury in or near the subthalamic nucleus.

Educational Objective:
Dystonia is a syndrome of prolonged, repetitive muscle contractions. This condition may be the result of impaired function of the basal ganglia. Cervical dystonia (spasmodic torticollis), blepharospasm, and writer's cramp are the most common types of focal dystonia.

Pathology	Nervous System	Dystonia
Subject	System	Topic

Copyright © UWorld. All rights reserved.

A 60-year-old professor is brought to the emergency department after developing right-sided weakness and numbness during a lecture an hour ago. He also has nausea and confusion. The patient smoked a pack of cigarettes daily for 20 years but quit 10 years ago. He does not drink alcohol. His father died of myocardial infarction at age 70. Blood pressure is 190/100 mm Hg, and pulse is 60 /min. On physical examination, there are no signs of head trauma. There is diminished right-sided strength (1/5) and an upgoing plantar reflex. Brain CT without contrast is obtained immediately. The image is shown below.

Settings

1 2 3 4 5 6 7 8 9 10 11 12 13 14 15 16 17 18 19 20 21 22 23 24 25 26 27 28 29 30

Item 36 of 40
Question Id: 498

Mark | Previous | Next | Full Screen | Tutorial | Lab Values | Notes | Calculator | Reverse Color | Text Zoom | Settings

obtained immediately. The image is shown below.

Block Time Remaining: 00:01:19
TUTOR

3 | Feedback | Suspend | End Block

Settings

1 2 3 4 5 6 7 8 9 10 11 12 13 14 15 16 17 18 19 20 21 22 23 24 25 26 27 28 29 30

Item 36 of 40
Question Id: 498

Mark | Previous | Next | Full Screen | Tutorial | Lab Values | Notes | Calculator | Reverse Color | Text Zoom | Settings

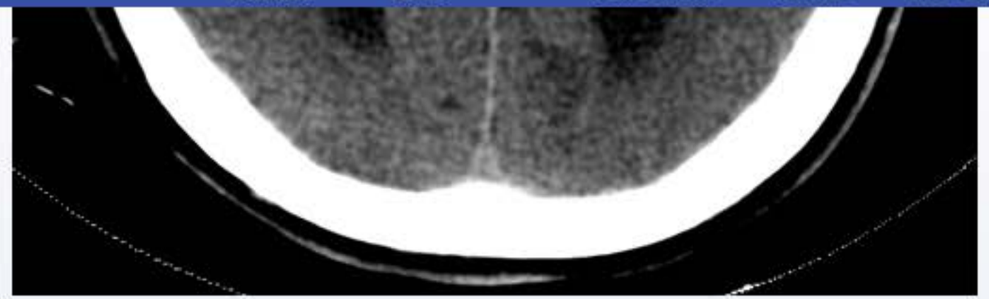

Which of the following is the most likely cause of this patient's condition?

- A. Arteriovenous malformation
- B. Cardiac embolism
- C. Carotid artery atherosclerosis
- D. Cerebral amyloid angiopathy
- E. Charcot-Bouchard aneurysm
- F. Hypertensive encephalopathy
- G. Hypoxic encephalopathy
- H. Large vessel arteritis
- I. Saccular aneurysm

Submit

Block Time Remaining: 00:01:21
TUTOR

3 | Feedback | Suspend | End Block

Settings

1 2 3 4 5 6 7 8 9 10 11 12 13 14 15 16 17 18 19 20 21 22 23 24 25 26 27 28 29 30

Item 36 of 40
Question Id: 498

Mark | Previous | Next | Full Screen | Tutorial | Lab Values | Notes | Calculator | Reverse Color | Text Zoom | Settings

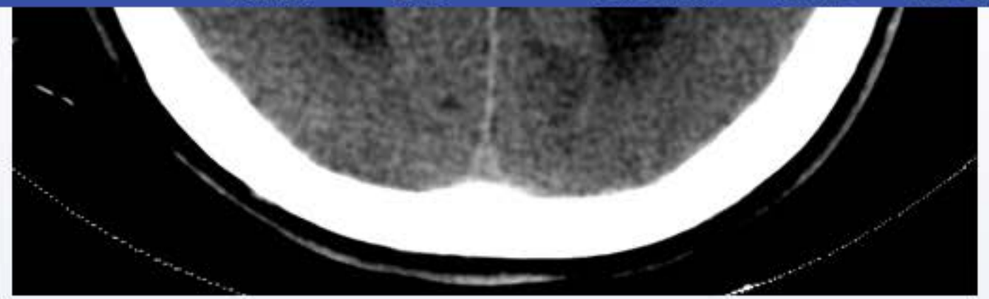

Which of the following is the most likely cause of this patient's condition?

- A. Arteriovenous malformation (2%)
- B. Cardiac embolism (4%)
- C. Carotid artery atherosclerosis (6%)
- D. Cerebral amyloid angiopathy (3%)
- ✓ E. Charcot-Bouchard aneurysm (52%)
- F. Hypertensive encephalopathy (16%)
- G. Hypoxic encephalopathy (1%)
- H. Large vessel arteritis (0%)
- I. Saccular aneurysm (13%)

Omitted
Correct answer

52%
Answered correctly

06 secs
Time Spent

03/08/2020
Last Updated

Block Time Remaining: 00:01:23
TUTOR

3 | Feedback | Suspend | End Block

	Charcot-Bouchard aneurysms	Saccular (berry) aneurysms
Associated conditions	• Hypertension	• ADPKD, Ehlers-Danlos syndrome, hypertension
Location	• Basal ganglia • Cerebellum • Thalamus • Pons	• Circle of Willis
Size	• <1 mm	• Variable, 2-25 mm
Result of rupture	• Intracerebral hemorrhage	• Subarachnoid hemorrhage
Symptoms of rupture	• Progressive neurologic deficits • Headache may follow	• Sudden severe headache • Focal neurologic deficits uncommon

ADPKD = autosomal dominant polycystic kidney disease.

©UWorld

This patient's brain CT is diagnostic for **acute hypertensive intracerebral hemorrhage** of the thalamus. Hypertensive vasculopathy involving the small penetrating branches of the cerebral arteries is the most common cause of deep intracranial hemorrhage. Chronic hypertension can lead to progressive arteriolar hyalinization and fibrinoid necrosis, weakening the vessel wall and predisposing to the formation of **Charcot-Bouchard aneurysms**. Aneurysmal rupture may ultimately lead to hemorrhage within the brain.

©UWorld

This patient's brain CT is diagnostic for **acute hypertensive intracerebral hemorrhage** of the thalamus. Hypertensive vasculopathy involving the small penetrating branches of the cerebral arteries is the most common cause of deep intracranial hemorrhage. Chronic hypertension can lead to progressive arteriolar hyalinization and fibrinoid necrosis, weakening the vessel wall and predisposing to the formation of **Charcot-Bouchard aneurysms**. Aneurysmal rupture may ultimately lead to hemorrhage within the brain.

The most common sites of intracranial hemorrhage are **deep brain structures**, such as the basal ganglia (putamen), cerebellar nuclei, thalamus, and pons. **Acute neurologic deficits** can vary depending on hemorrhage location. This patient's contralateral weakness/numbness and extensor plantar response is consistent with thalamic hemorrhage with edema/mass effect on the internal capsule. Symptoms may worsen within minutes to hours and can be associated with headache, nausea/vomiting, or decreased level of consciousness as the hematoma expands. Acute bleeding appears as **hyperattenuated**, or bright, lesions on noncontrast head CT.

(Choices A) Arteriovenous malformations are the most common cause of intracranial hemorrhage in children. This patient's older age makes the diagnosis less likely.

(Choices B and C) Carotid artery atherosclerosis and cardiac embolism are 2 common causes of ischemic stroke. Clinical presentation may resemble hemorrhagic stroke; however, this patient's CT findings are consistent with hemorrhage. Spontaneous hemorrhagic transformation of ischemic stroke would be rare within hours of symptom onset.

(Choice D) Cerebral amyloid angiopathy is the most common cause of lobar/cortical parenchymal hemorrhage, particularly in older adults. This patient's deep intracranial hemorrhage makes hypertensive vasculopathy more likely.

(Choice F) Hypertensive encephalopathy is characterized by a **progressive** headache and nausea/vomiting followed by nonlocalizing neurologic symptoms (eg, confusion). This patient's focal neurologic deficits and evidence of hemorrhage on CT exclude this diagnosis.

(Choice G) Hypoxic encephalopathy is caused by decreased oxygenation of the blood (eg, due to cardiac arrest). It most often presents with decreased consciousness (eg, coma or vegetative state); focal neurologic deficits and intracranial hemorrhage would not be seen.

(Choice H) Intracranial vasculitis can lead to intraparenchymal hemorrhage but is a far less common etiology compared to hypertensive vasculopathy.

(Choice D) Cerebral amyloid angiopathy is the most common cause of lobar/cortical parenchymal hemorrhage, particularly in older adults. This patient's deep intracranial hemorrhage makes hypertensive vasculopathy more likely.

(Choice F) Hypertensive encephalopathy is characterized by a **progressive** headache and nausea/vomiting followed by nonlocalizing neurologic symptoms (eg, confusion). This patient's focal neurologic deficits and evidence of hemorrhage on CT exclude this diagnosis.

(Choice G) Hypoxic encephalopathy is caused by decreased oxygenation of the blood (eg, due to cardiac arrest). It most often presents with decreased consciousness (eg, coma or vegetative state); focal neurologic deficits and intracranial hemorrhage would not be seen.

(Choice H) Intracranial vasculitis can lead to intraparenchymal hemorrhage but is a far less common etiology compared to hypertensive vasculopathy.

(Choice I) Saccular aneurysm rupture is typically associated with subarachnoid hemorrhage as opposed to intraparenchymal hematoma. Patients usually have an abrupt onset of severe headache (thunderclap headache), and focal neurologic deficits are less common. On CT, subarachnoid hemorrhage appears as hyperattenuation of the sulci and basal cisterns.

Educational objective:
Deep intraparenchymal hemorrhage is most commonly caused by hypertensive vasculopathy of the small penetrating branches of the cerebral arteries (Charcot-Bouchard aneurysm rupture). This is in contrast to rupture of saccular aneurysms, which typically cause subarachnoid hemorrhage.

References

- Primary intracerebral hemorrhage.
- Fibrinoid necrosis of small brain arteries and arterioles and miliary aneurysms as causes of hypertensive hemorrhage: a critical reappraisal.

Pathology	Nervous System	Hemorrhagic stroke
Subject	System	Topic

Copyright © UWorld. All rights reserved.

Settings

1 2 3 4 5 6 7 8 9 10 11 12 13 14 15 16 17 18 19 20 21 22 23 24 25 26 27 28 29 30

Item 37 of 40
Question Id: 671

Mark | Previous | Next | Full Screen | Tutorial | Lab Values | Notes | Calculator | Reverse Color | Text Zoom | Settings

A 16-year-old boy is evaluated for progressive gait instability, dysmetria, and dysarthria for the past several years. The patient enjoys basketball but can no longer play due to his worsening symptoms. He is worried as his brother died of a neurologic disease at age 21. Physical examination of the lower extremities reveals bilateral motor weakness and loss of deep tendon reflexes, joint position, and vibration sense. MRI of the brain and spine shows degeneration of the posterior columns and spinocerebellar tracts. Which of the following conditions has clinical manifestations that closely resemble this patient's disease?

A. Acute intermittent porphyria

B. Lead intoxication

C. Poliomyelitis

D. Prion disease

E. Thiamine deficiency

F. Vitamin E deficiency

Submit

Block Time Remaining: 00:01:23
TUTOR

2 | Feedback | Suspend | End Block

A 16-year-old boy is evaluated for progressive gait instability, dysmetria, and dysarthria for the past several years. The patient enjoys basketball but can no longer play due to his worsening symptoms. He is worried as his brother died of a neurologic disease at age 21. Physical examination of the lower extremities reveals bilateral motor weakness and loss of deep tendon reflexes, joint position, and vibration sense. MRI of the brain and spine shows degeneration of the posterior columns and spinocerebellar tracts. Which of the following conditions has clinical manifestations that closely resemble this patient's disease?

- A. Acute intermittent porphyria (2%)
- B. Lead intoxication (6%)
- C. Poliomyelitis (28%)
- D. Prion disease (3%)
- E. Thiamine deficiency (21%)
- ✓ F. Vitamin E deficiency (36%)

Omitted
Correct answer
F

36%
Answered correctly

01 sec
Time Spent

06/02/2020
Last Updated

Explanation

Vitamin E is a lipid-soluble, antioxidant vitamin that is widely available in the diet. **Vitamin E deficiency** is rare but may occur in patients with fat malabsorption and abetalipoproteinemia. The most notable manifestations include hemolysis and **neurologic dysfunction** (due to free radical

Vitamin E is a lipid-soluble, antioxidant vitamin that is widely available in the diet. **Vitamin E deficiency** is rare but may occur in patients with fat malabsorption and abetalipoproteinemia. The most notable manifestations include hemolysis and **neurologic dysfunction** (due to free radical damage of cell membranes).

Neurologic symptoms of vitamin E deficiency closely **mimic** Friedreich ataxia (an autosomal recessive degenerative condition) as many of the same areas in the nervous system are affected. Specifically, patients with either condition may have ataxia (due to degeneration of spinocerebellar tracts), loss of position and vibration sense (due to degeneration of the dorsal columns), and loss of deep tendon reflexes (due to peripheral nerve degeneration). Vitamin B12 deficiency may also present similarly due to subacute combined degeneration of the dorsal and lateral spinal columns.

(Choice A) Unlike Friedrich ataxia, acute intermittent porphyria does not result in progressive spinal cord degeneration. Instead, it usually causes intermittent acute attacks of abdominal pain and peripheral neuropathy.

(Choice B) Lead intoxication is seen in children more often than adults. It manifests with irritability, loss of developmental milestones (in infants), or learning problems (in older children). Gastrointestinal symptoms (eg, constipation, nausea, abdominal pain) also occur.

(Choice C) Poliomyelitis causes damage to the anterior horn cells and leads to asymmetric flaccid paralysis and hyporeflexia. Sensation is typically preserved.

(Choice D) Creutzfeldt-Jakob disease is a prion disease that presents with rapidly progressive dementia and myoclonic jerks of the extremities.

(Choice E) Thiamine (vitamin B1) deficiency occurs in alcoholics and malnourished patients. It is associated with peripheral neuropathy, high-output cardiac failure, and Wernicke encephalopathy (eg, ataxia, confusion, ophthalmoplegia).

Educational objective:
Vitamin E is a lipid-soluble vitamin that has antioxidative properties. Neurologic symptoms of vitamin E deficiency closely mimic Friedreich ataxia and include ataxia (due to degeneration of spinocerebellar tracts), loss of position and vibration sense (due to degeneration of the dorsal columns), and loss of deep tendon reflexes (due to peripheral nerve degeneration).

Settings

1 2 3 4 5 6 7 8 9 10 11 12 13 14 15 16 17 18 19 20 21 22 23 24 25 26 27 28 29 30

Item 37 of 40
Question Id: 671

Mark | Previous | Next | Full Screen | Tutorial | Lab Values | Notes | Calculator | Reverse Color | Text Zoom | Settings

Exhibit Display

Friedreich ataxia

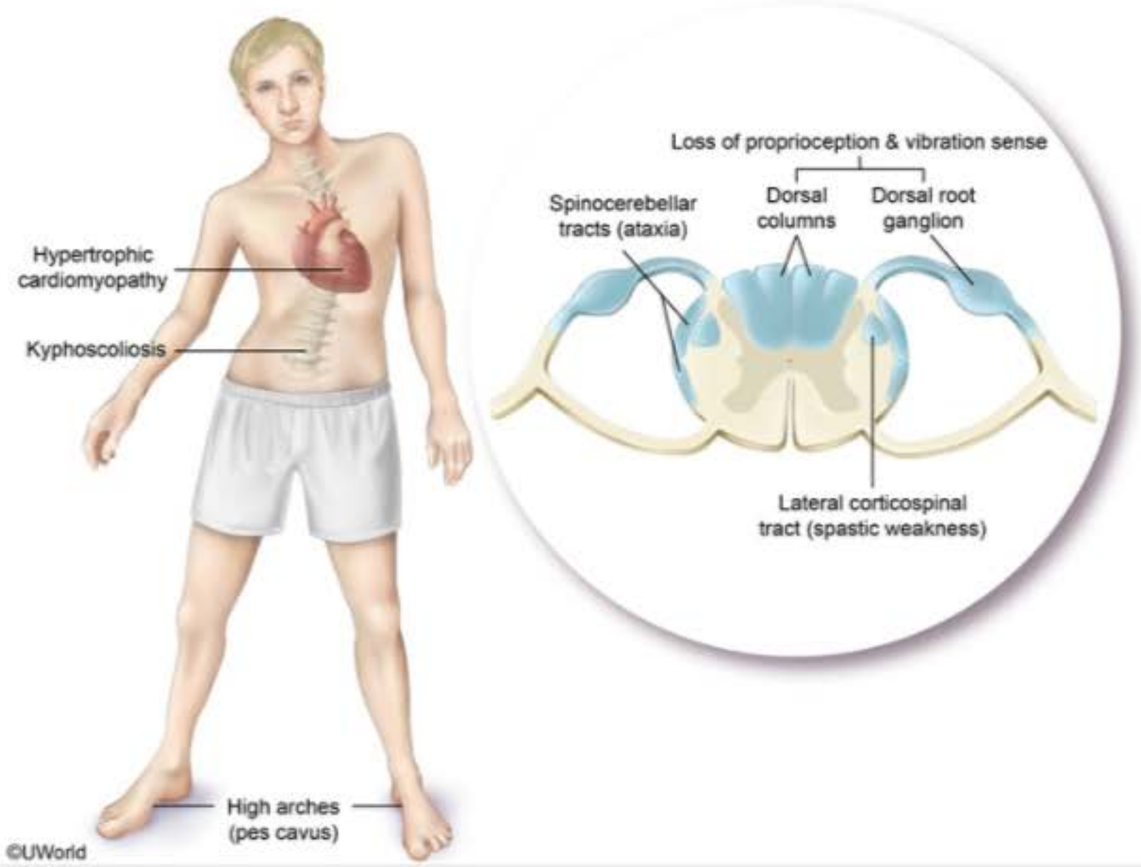

Zoom In | Zoom Out | Reset | Add To New Card | Existing Card

Block Time Remaining: 00:01:24
TUTOR

2 | Feedback | Suspend | End Block

spinocerebellar tracts), loss of position and vibration sense (due to degeneration of the dorsal columns), and loss of deep tendon reflexes (due to peripheral nerve degeneration). Vitamin B12 deficiency may also present similarly due to subacute combined degeneration of the dorsal and lateral spinal columns.

(Choice A) Unlike Friedrich ataxia, acute intermittent porphyria does not result in progressive spinal cord degeneration. Instead, it usually causes intermittent acute attacks of abdominal pain and peripheral neuropathy.

(Choice B) Lead intoxication is seen in children more often than adults. It manifests with irritability, loss of developmental milestones (in infants), or learning problems (in older children). Gastrointestinal symptoms (eg, constipation, nausea, abdominal pain) also occur.

(Choice C) Poliomyelitis causes damage to the anterior horn cells and leads to asymmetric flaccid paralysis and hyporeflexia. Sensation is typically preserved.

(Choice D) Creutzfeldt-Jakob disease is a prion disease that presents with rapidly progressive dementia and myoclonic jerks of the extremities.

(Choice E) Thiamine (vitamin B1) deficiency occurs in alcoholics and malnourished patients. It is associated with peripheral neuropathy, high-output cardiac failure, and Wernicke encephalopathy (eg, ataxia, confusion, ophthalmoplegia).

Educational objective:
Vitamin E is a lipid-soluble vitamin that has antioxidative properties. Neurologic symptoms of vitamin E deficiency closely mimic Friedreich ataxia and include ataxia (due to degeneration of spinocerebellar tracts), loss of position and vibration sense (due to degeneration of the dorsal columns), and loss of deep tendon reflexes (due to peripheral nerve degeneration).

References

- Cerebellar ataxia due to isolated vitamin E deficiency.

Pathology	Nervous System	Vitamin e
Subject	System	Topic

Copyright © UWorld. All rights reserved.

Settings

1 2 3 4 5 6 7 8 9 10 11 12 13 14 15 16 17 18 19 20 21 22 23 24 25 26 27 28 29 30

Item 38 of 40
Question Id: 18543

Mark | Previous | Next | Full Screen | Tutorial | Lab Values | Notes | Calculator | Reverse Color | Text Zoom | Settings

A 45-year-old woman comes to the emergency department due to sudden-onset, severe headache. On arrival, the patient is alert and oriented and has no focal neurological deficits. CT scan of the head reveals subarachnoid hemorrhage, and she is admitted to the critical care unit. Over the next several hours, the patient gradually becomes somnolent and less responsive. She opens her eyes to painful stimuli only and does not follow commands. Repeat imaging of the brain shows no new hemorrhage, but there is enlargement of the entire ventricular system compared to the previous CT scan. Which of the following is the most likely cause of this patient's neurologic deterioration in the hospital?

- A. Blockage of the cerebral aqueduct by blood products
- B. Cerebral vasospasm due to subarachnoid blood
- C. Edema from a disruption in the blood-brain barrier
- D. Excessive production of cerebrospinal fluid
- E. Impaired absorption of cerebrospinal fluid

Submit

Block Time Remaining: 00:01:24
TUTOR

0 | Feedback | Suspend | End Block

A 45-year-old woman comes to the emergency department due to sudden-onset, severe headache. On arrival, the patient is alert and oriented and has no focal neurological deficits. CT scan of the head reveals subarachnoid hemorrhage, and she is admitted to the critical care unit. Over the next several hours, the patient gradually becomes somnolent and less responsive. She opens her eyes to painful stimuli only and does not follow commands. Repeat imaging of the brain shows no new hemorrhage, but there is enlargement of the entire ventricular system compared to the previous CT scan. Which of the following is the most likely cause of this patient's neurologic deterioration in the hospital?

- A. Blockage of the cerebral aqueduct by blood products (20%)
- B. Cerebral vasospasm due to subarachnoid blood (20%)
- C. Edema from a disruption in the blood-brain barrier (5%)
- D. Excessive production of cerebrospinal fluid (0%)
- ✓ E. Impaired absorption of cerebrospinal fluid (52%)

Omitted
Correct answer
E

52%
Answered correctly

01 sec
Time Spent

02/19/2020
Last Updated

Explanation

Flow of cerebrospinal fluid

CSF reabsorbed into

Arachnoid

Settings

Item 38 of 40
Question Id: 18543

Mark | Previous | Next | Full Screen | Tutorial | Lab Values | Notes | Calculator | Reverse Color | Text Zoom | Settings

Explanation

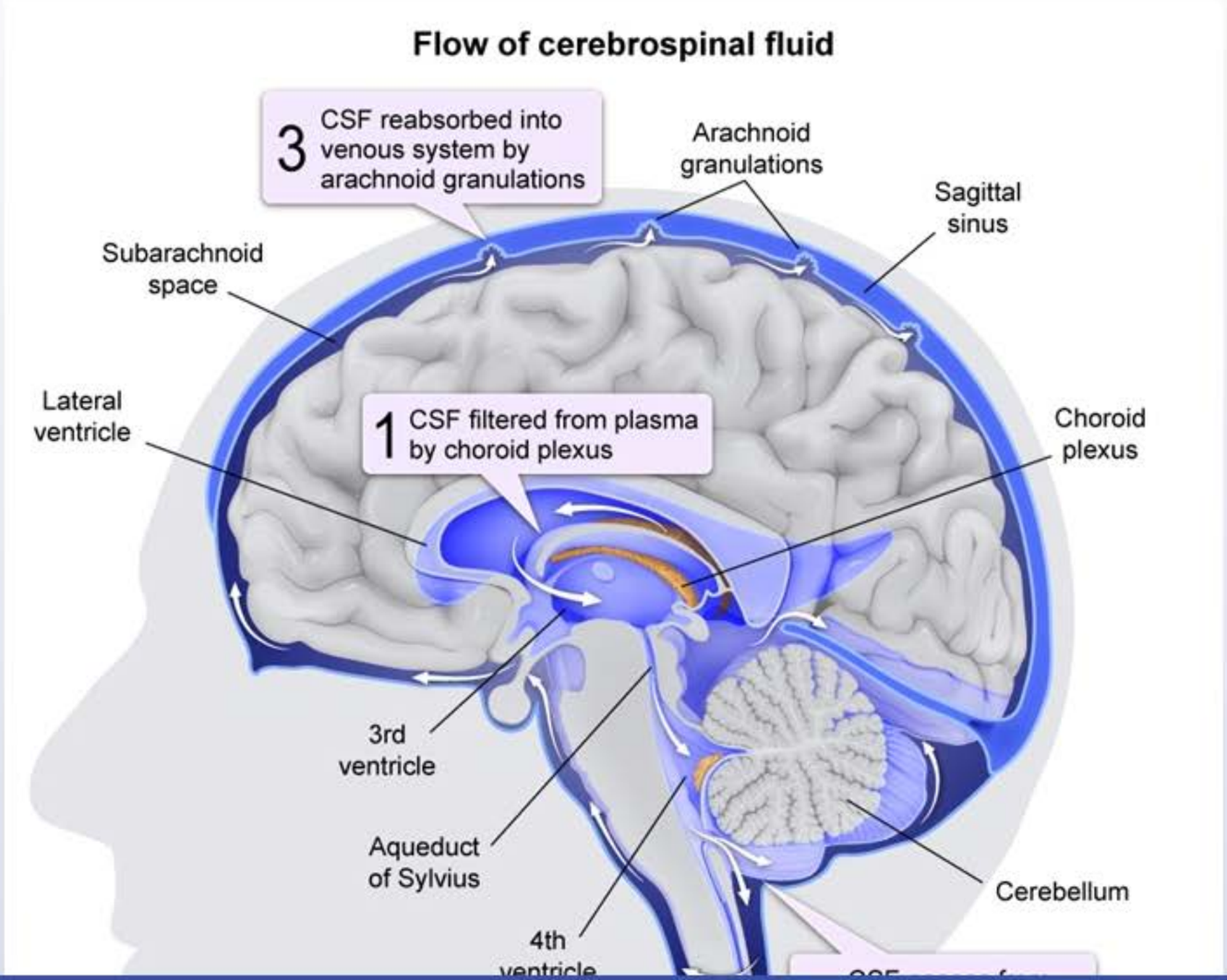

Block Time Remaining: 00:01:25
TUTOR

0 | Feedback | Suspend | End Block

Settings

Item 38 of 40
Question Id: 18543

Mark | Previous | Next | Full Screen | Tutorial | Lab Values | Notes | Calculator | Reverse Color | Text Zoom | Settings

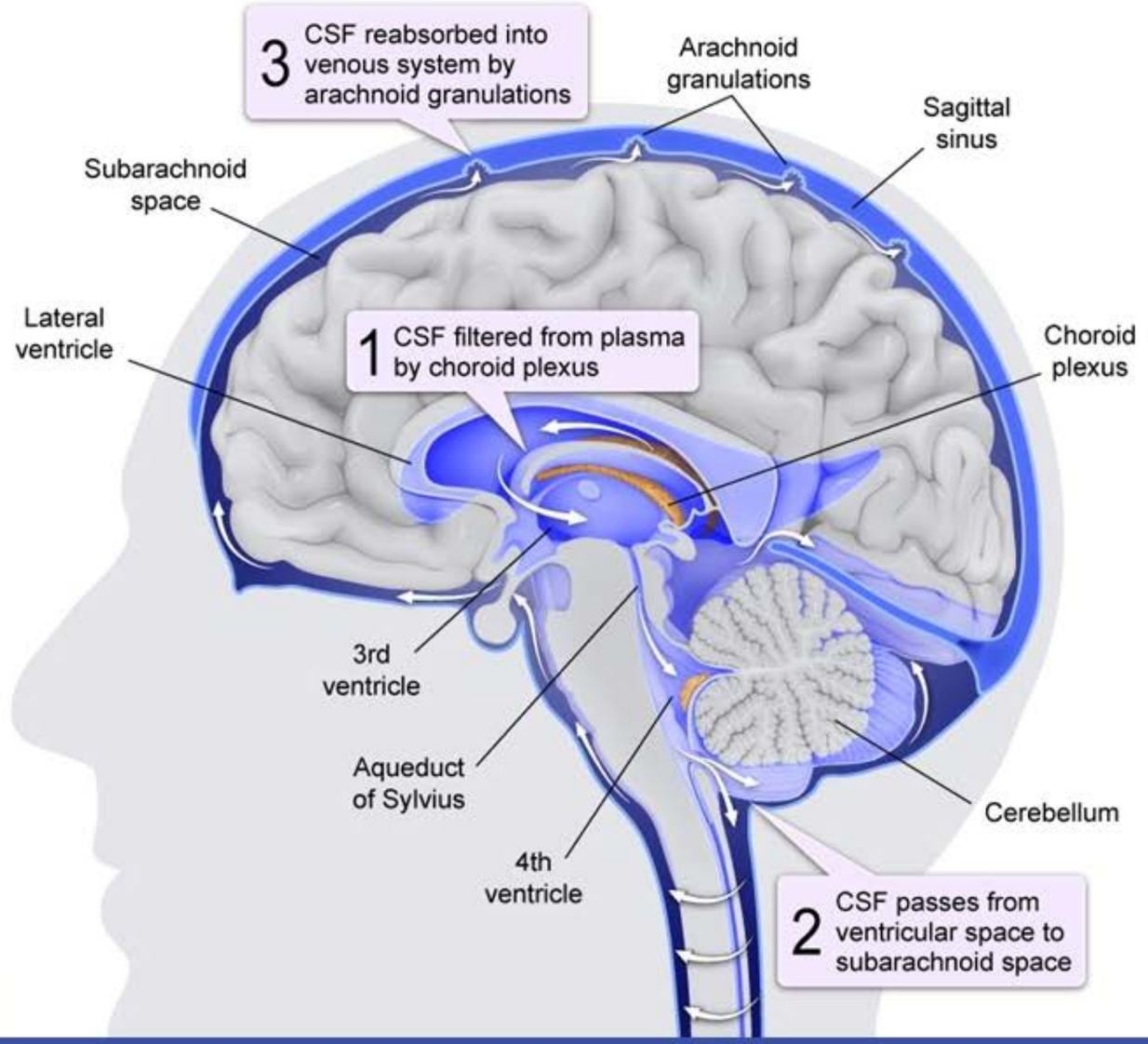

Block Time Remaining: 00:01:25
TUTOR

0 | Feedback | Suspend | End Block

Hydrocephalus is a common complication of **subarachnoid hemorrhage** (SAH). Blood in the subarachnoid space can acutely obstruct and **impair absorption** of cerebral spinal fluid (CSF) by the **arachnoid granulations**. Later, blood-induced inflammation can cause fibrosis of the arachnoid granulations that perpetuates the absorption impairment and leads to chronic hydrocephalus.

Impaired CSF absorption creates a **communicating** hydrocephalus. Because the blockage to flow is distal to the entire ventricular system, **enlargement of all 4 ventricles** occurs. The ventricular enlargement stretches adjacent nerve fibers and, in the acute setting, leads to **deteriorating mental status** (eg, somnolence, unresponsiveness). Treatment involves the placement of an external ventricular drain to relieve pressure in the ventricular system and subarachnoid space. Patients who develop chronic hydrocephalus may require placement of a permanent shunt (eg, ventriculoperitoneal shunt).

(Choice A) Blockage of the cerebral aqueduct (aqueduct of Sylvius) is less common with SAH and more typically occurs with intracerebral hemorrhage complicated by intraventricular bleeding. The resulting hydrocephalus is noncommunicating as there is no free passage of CSF from the ventricular space into the subarachnoid space. Enlargement of only the lateral and third ventricles is expected; the fourth ventricle is distal to the obstruction and remains normal in size.

(Choice B) Cerebral vasospasm is a common complication of SAH; however, it is typically delayed, occurring 4-14 days following the initial bleed, and leads to localized stroke with focal neurologic deficits rather than deteriorating mental status. Dilated ventricles are not seen.

(Choice C) Edema that occurs due to disruption of the blood-brain barrier (vasogenic cerebral edema) collects within the brain parenchyma and can result from stroke or trauma. It is not expected following SAH.

(Choice D) Excessive CSF production is a rare cause of communicating hydrocephalus that may result from a choroid plexus papilloma. Enlargement of all 4 ventricles is expected, but this patient's SAH makes impaired absorption of CSF far more likely.

Educational objective:
Communicating hydrocephalus is a common complication of subarachnoid hemorrhage that presents with deteriorating mental status. It typically results from blood-induced impairment of absorption of cerebrospinal fluid by the arachnoid granulations.

References

- Predictors of ventriculoperitoneal shunting following subarachnoid hemorrhage treated with external ventricular drainage.

deteriorating mental status (eg, somnolence, unresponsiveness). Treatment involves the placement of an external ventricular drain to relieve pressure in the ventricular system and subarachnoid space. Patients who develop chronic hydrocephalus may require placement of a permanent shunt (eg, ventriculoperitoneal shunt).

(Choice A) Blockage of the cerebral aqueduct (aqueduct of Sylvius) is less common with SAH and more typically occurs with intracerebral hemorrhage complicated by intraventricular bleeding. The resulting hydrocephalus is noncommunicating as there is no free passage of CSF from the ventricular space into the subarachnoid space. Enlargement of only the lateral and third ventricles is expected; the fourth ventricle is distal to the obstruction and remains normal in size.

(Choice B) Cerebral vasospasm is a common complication of SAH; however, it is typically delayed, occurring 4-14 days following the initial bleed, and leads to localized stroke with focal neurologic deficits rather than deteriorating mental status. Dilated ventricles are not seen.

(Choice C) Edema that occurs due to disruption of the blood-brain barrier (vasogenic cerebral edema) collects within the brain parenchyma and can result from stroke or trauma. It is not expected following SAH.

(Choice D) Excessive CSF production is a rare cause of communicating hydrocephalus that may result from a choroid plexus papilloma. Enlargement of all 4 ventricles is expected, but this patient's SAH makes impaired absorption of CSF far more likely.

Educational objective:
Communicating hydrocephalus is a common complication of subarachnoid hemorrhage that presents with deteriorating mental status. It typically results from blood-induced impairment of absorption of cerebrospinal fluid by the arachnoid granulations.

References

- Predictors of ventriculoperitoneal shunting following subarachnoid hemorrhage treated with external ventricular drainage.

Pathology	Nervous System	Hydrocephalus
Subject	System	Topic

Copyright © UWorld. All rights reserved.

Settings

1 2 3 4 5 6 7 8 9 10 11 12 13 14 15 16 17 18 19 20 21 22 23 24 25 26 27 28 29 30

Item 38 of 40
Question Id: 18543

Mark | Previous | Next | Full Screen | Tutorial | Lab Values | Notes | Calculator | Reverse Color | Text Zoom | Settings

Exhibit Display

Ventricular system

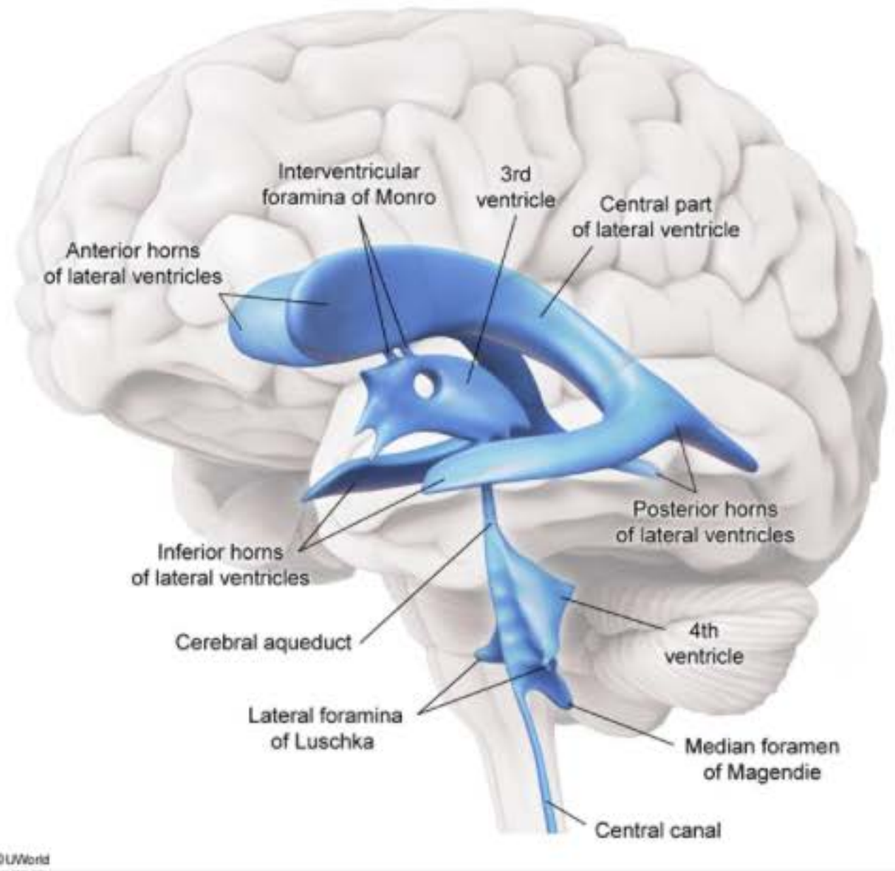

Zoom In | Zoom Out | Reset | Add To Flash Card

can result from stroke or trauma. It is not expected following SAH.

Block Time Remaining: 00:01:25
TUTOR

0 | Feedback | Suspend | End Block

Settings

1 2 3 4 5 6 7 8 9 10 11 12 13 14 15 16 17 18 19 20 21 22 23 24 25 26 27 28 29 30

Item 39 of 40
Question Id: 1962

Mark | Previous | Next | Full Screen | Tutorial | Lab Values | Notes | Calculator | Reverse Color | Text Zoom | Settings

A 34-year-old man comes to the emergency department due to severe headache. The patient describes unbearable, throbbing pain around his right eye that awakened him. Over the past week, he has had several similar episodes, which spontaneously resolved after 20-30 minutes. He has no other medical conditions and takes no medications. The patient smokes a pack of cigarettes daily and drinks alcohol on social occasions. On physical examination, he appears restless and paces in the room. There is mild conjunctival injection and miosis of the right eye. Neurologic examination shows no abnormalities. Which of the following is the most likely cause of this patient's current symptoms?

A. Cavernous sinus thrombosis

B. Cluster headache

C. Migraine without aura

D. Opiate withdrawal

E. Trigeminal neuralgia

F. Vertebrobasilar ischemia

Submit

Block Time Remaining: 00:01:25
TUTOR

3 | Feedback | Suspend | End Block

A 34-year-old man comes to the emergency department due to severe headache. The patient describes unbearable, throbbing pain around his right eye that awakened him. Over the past week, he has had several similar episodes, which spontaneously resolved after 20-30 minutes. He has no other medical conditions and takes no medications. The patient smokes a pack of cigarettes daily and drinks alcohol on social occasions. On physical examination, he appears restless and paces in the room. There is mild conjunctival injection and miosis of the right eye. Neurologic examination shows no abnormalities. Which of the following is the most likely cause of this patient's current symptoms?

- A. Cavernous sinus thrombosis (7%)
- ✓ B. Cluster headache (81%)
- C. Migraine without aura (3%)
- D. Opiate withdrawal (2%)
- E. Trigeminal neuralgia (4%)
- F. Vertebrobasilar ischemia (0%)

Omitted
Correct answer
B

81%
Answered correctly

02 secs
Time Spent

02/23/2020
Last Updated

Explanation

	Types of headache		

	Types of headache		
	Migraine	**Cluster**	**Tension**
Sex predilection	Female > male	Male > female	Female > male
Family history	Often present	±	None
Onset	Variable	During sleep or similar timing daily	Under stress
Location	Often unilateral	Behind one eye	Band-like pattern around the head (bilateral)
Character	Pulsatile & throbbing	Excruciating, sharp & steady	Dull, tight & persistent
Duration	4-72 hours	15-180 minutes	30 minutes to months/years
Associated symptoms	Photophobia, phonophobia & nausea, ± aura	Ipsilateral sweating, facial flushing, nasal congestion & pupillary changes	Muscle tenderness in the head, neck, or shoulders

This young man with throbbing, unilateral periorbital headache associated with conjunctival injection and miosis has **cluster headaches**. The pathogenesis of cluster headaches is poorly understood but likely includes genetic predisposition, vascular dilation, and activation of the trigeminal-autonomic reflex. Males are affected more commonly than females.

Cluster headaches present with rapid-onset, severe, **unilateral periorbital** and temporal pain; patients are often restless or agitated during episodes. **Ipsilateral autonomic symptoms** due to parasympathetic hyperactivity are common and include nasal congestion, lacrimation, ptosis, miosis, and conjuntival injection. The headaches typically last 15-180 minutes and tend to occur in clusters (often at the same time each day, even if asleep) over a period of several weeks.

(Choice A) Cavernous sinus thrombosis typically occurs in patients with thrombophilia (eg, malignancy, antithrombin deficiency) or as a septic thrombosis related to a sinus infection or facial cellulitis. Orbital pain is common; however, it is typically worsened with eye movement. Periorbital

Symptoms	nausea, ± aura	congestion & pupillary changes	neck, or shoulders

This young man with throbbing, unilateral periorbital headache associated with conjunctival injection and miosis has **cluster headaches**. The pathogenesis of cluster headaches is poorly understood but likely includes genetic predisposition, vascular dilation, and activation of the trigeminal-autonomic reflex. Males are affected more commonly than females.

Cluster headaches present with rapid-onset, severe, **unilateral periorbital** and temporal pain; patients are often restless or agitated during episodes. **Ipsilateral autonomic symptoms** due to parasympathetic hyperactivity are common and include nasal congestion, lacrimation, ptosis, miosis, and conjuntival injection. The headaches typically last 15-180 minutes and tend to occur in clusters (often at the same time each day, even if asleep) over a period of several weeks.

(Choice A) Cavernous sinus thrombosis typically occurs in patients with thrombophilia (eg, malignancy, antithrombin deficiency) or as a septic thrombosis related to a sinus infection or facial cellulitis. Orbital pain is common; however, it is typically worsened with eye movement. Periorbital swelling, fever, and proptosis are other frequent findings.

(Choice C) Migraine without aura typically causes severe, pulsatile, unilateral headache often associated with photophobia, phonophobia, nausea, and vomiting. Miosis and lacrimation are unexpected.

(Choice D) Opiate withdrawal can cause lacrimation, rhinorrhea, and diaphoresis, but would usually cause bilateral symptoms. It typically also causes gastrointestinal symptoms (eg, diarrhea, nausea), piloerection, and mydriasis; orbital pain is unexpected.

(Choice E) Trigeminal neuralgia (tic douloureux) causes sudden, "electric" pain in the distribution of the maxillary and/or mandibular divisions of the trigeminal nerve, often preceded by light touch. Episodes last for seconds and do not typically occur during sleep.

(Choice F) Vertebrobasilar ischemia can cause headaches but also typically causes dizziness, double vision or vision loss, and ataxia.

Educational objective:
Cluster headaches cause severe, episodic, unilateral periorbital and temporal pain associated with ipsilateral autonomic symptoms (eg, lacrimation, nasal congestion, miosis, conjunctival injection). The headaches typically last 15-180 minutes and tend to occur in clusters (often at the same time each day). Males are affected more commonly than females.

Cluster headaches present with rapid-onset, severe, **unilateral periorbital** and temporal pain; patients are often restless or agitated during episodes. **Ipsilateral autonomic symptoms** due to parasympathetic hyperactivity are common and include nasal congestion, lacrimation, ptosis, miosis, and conjuntival injection. The headaches typically last 15-180 minutes and tend to occur in clusters (often at the same time each day, even if asleep) over a period of several weeks.

(Choice A) Cavernous sinus thrombosis typically occurs in patients with thrombophilia (eg, malignancy, antithrombin deficiency) or as a septic thrombosis related to a sinus infection or facial cellulitis. Orbital pain is common; however, it is typically worsened with eye movement. Periorbital swelling, fever, and proptosis are other frequent findings.

(Choice C) Migraine without aura typically causes severe, pulsatile, unilateral headache often associated with photophobia, phonophobia, nausea, and vomiting. Miosis and lacrimation are unexpected.

(Choice D) Opiate withdrawal can cause lacrimation, rhinorrhea, and diaphoresis, but would usually cause bilateral symptoms. It typically also causes gastrointestinal symptoms (eg, diarrhea, nausea), piloerection, and mydriasis; orbital pain is unexpected.

(Choice E) Trigeminal neuralgia (tic douloureux) causes sudden, "electric" pain in the distribution of the maxillary and/or mandibular divisions of the trigeminal nerve, often preceded by light touch. Episodes last for seconds and do not typically occur during sleep.

(Choice F) Vertebrobasilar ischemia can cause headaches but also typically causes dizziness, double vision or vision loss, and ataxia.

Educational objective:
Cluster headaches cause severe, episodic, unilateral periorbital and temporal pain associated with ipsilateral autonomic symptoms (eg, lacrimation, nasal congestion, miosis, conjunctival injection). The headaches typically last 15-180 minutes and tend to occur in clusters (often at the same time each day). Males are affected more commonly than females.

Pathology	Nervous System	Cluster headache
Subject	System	Topic

Copyright © UWorld. All rights reserved.

Settings

1 2 3 4 5 6 7 8 9 10 11 12 13 14 15 16 17 18 19 20 21 22 23 24 25 26 27 28 29 30

Item 40 of 40
Question Id: 15649

Mark | Previous | Next | Full Screen | Tutorial | Lab Values | Notes | Calculator | Reverse Color | Text Zoom | Settings

A 70-year-old man is brought to the emergency department due to left-sided weakness and slurred speech upon awakening 30 minutes ago. The patient was asymptomatic when he went to bed last night. Medical history includes type 2 diabetes mellitus, hypertension, and hyperlipidemia. The patient is a former smoker with a 30-pack-year history. Physical examination shows a right gaze preference, left lower facial droop, and hemiplegia and hemisensory loss on the left. CT scan of the brain reveals early infarction in the right middle cerebral artery territory with no acute hemorrhage. The patient is hospitalized for further management. Several hours later, he becomes progressively obtunded with elevated intracranial pressure. A repeat CT scan reveals edema in the region of acute infarction causing mass effect. Which of the following is the primary contributor to the pathogenesis of this patient's raised intracranial pressure?

A. Decrease in plasma oncotic pressure

B. Failure of ATP-dependent ion transporters

C. Inadequate absorption of cerebrospinal fluid

D. Increase in capillary hydrostatic pressure

E. Proliferation of astrocytes and microglia

Submit

Block Time Remaining: 00:01:27
TUTOR

0 | Feedback | Suspend | End Block

A 70-year-old man is brought to the emergency department due to left-sided weakness and slurred speech upon awakening 30 minutes ago. The patient was asymptomatic when he went to bed last night. Medical history includes type 2 diabetes mellitus, hypertension, and hyperlipidemia. The patient is a former smoker with a 30-pack-year history. Physical examination shows a right gaze preference, left lower facial droop, and hemiplegia and hemisensory loss on the left. CT scan of the brain reveals early infarction in the right middle cerebral artery territory with no acute hemorrhage. The patient is hospitalized for further management. Several hours later, he becomes progressively obtunded with elevated intracranial pressure. A repeat CT scan reveals edema in the region of acute infarction causing mass effect. Which of the following is the primary contributor to the pathogenesis of this patient's raised intracranial pressure?

- A. Decrease in plasma oncotic pressure (3%)
- ✓ B. Failure of ATP-dependent ion transporters (46%)
- C. Inadequate absorption of cerebrospinal fluid (15%)
- D. Increase in capillary hydrostatic pressure (28%)
- E. Proliferation of astrocytes and microglia (5%)

Omitted
Correct answer
B

46%
Answered correctly

01 sec
Time Spent

04/07/2020
Last Updated

Explanation

This patient had a right hemispheric **ischemic stroke** and developed altered mental status and increased intracranial pressure (ICP) secondary to **cerebral edema**. The fixed volume of the skull necessitates that a significant increase in volume of any component of the CNS (eg, brain tissue,

This patient had a right hemispheric **ischemic stroke** and developed altered mental status and increased intracranial pressure (ICP) secondary to **cerebral edema**. The fixed volume of the skull necessitates that a significant increase in volume of any component of the CNS (eg, brain tissue, blood, cerebrospinal fluid) will raise ICP. This increased ICP can cause progressive **neurologic impairment** through direct pressure-induced cell injury or mechanical damage due to brain herniation.

Irreversible ischemic neural and glial cell injury initiates a sequence of chemical changes that promote edema:

- **Cytotoxic (ionic) edema** begins hours after the ischemic injury due to decreased ATP. The failure of **ATP-dependent ion pumps**, combined with the release of excitatory amino acids (eg, glutamate), leads to the accumulation of intracellular Na^+ and water in neural and glial cells despite an intact blood-brain barrier.
- **Vasogenic edema** follows 24-48 hours later, when the release of inflammatory mediators disrupts the tight junctions of the blood-brain barrier, allowing proteins (eg, albumin) and water to enter the interstitial space. This vasogenic phase can cause persistent cerebral edema for weeks after the initial injury.

(Choice A) Although a decrease in oncotic pressure can cause peripheral edema (eg, nephrotic syndrome), it is not a significant factor in the development of cerebral edema. Mannitol is used in the treatment of cerebral edema because it increases plasma oncotic pressure and temporarily disrupts the blood-brain barrier, allowing movement of fluid out of the CNS to decrease ICP.

(Choice C) Inadequate absorption of cerebrospinal fluid at the arachnoid granulations can cause communicating hydrocephalus. Although this process raises ICP, ventriculomegaly would likely be prominent on CT scan.

(Choice D) Increased hydrostatic pressure secondary to central venous thrombosis or hypertensive encephalopathy can cause cerebral edema and increased ICP. However, patients typically have gradually worsening headache before development of neurologic abnormalities.

(Choice E) Gliosis is the process of repairing damaged tissue in the CNS by proliferating astrocytes and microglia. This process occurs slowly in the months to years after CNS injury and would not be expected to cause acute changes in ICP.

Educational objective:
The primary mechanism underlying cytotoxic (early) edema following cerebral ischemia is the accumulation of intracellular Na^+ and water due to the failure of ATP-dependent ion transporters in hypoxic cells. Cerebral edema causes progressive neurologic decline by raising intracranial

This patient had a right hemispheric **ischemic stroke** and developed altered mental status and increased intracranial pressure (ICP) secondary to

Exhibit Display

Types of brain herniations

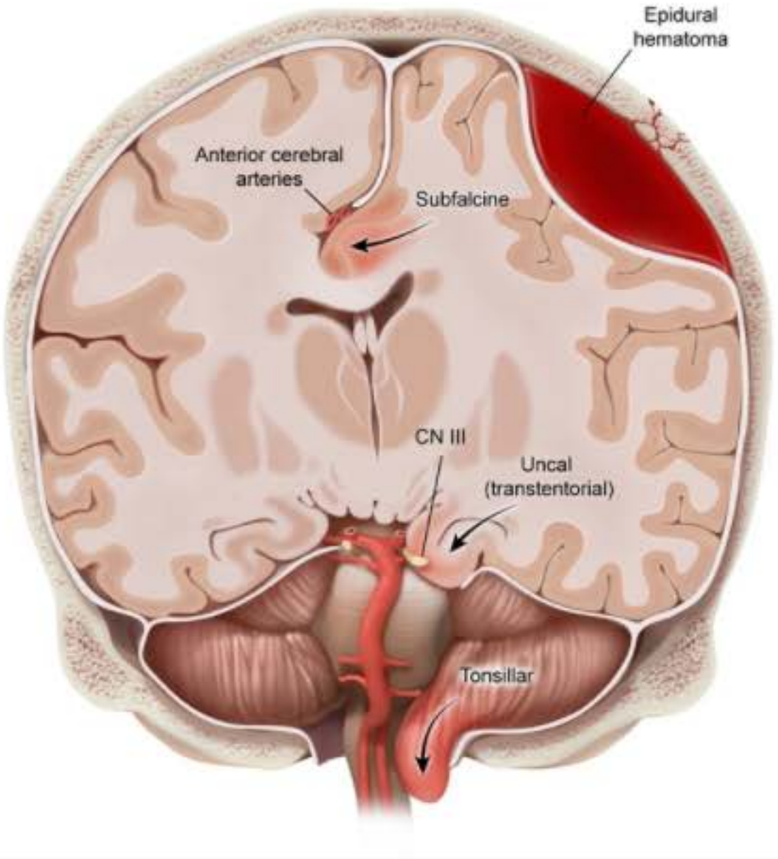

Zoom In | Zoom Out | Reset | Add To Flash Card

the failure of ATP-dependent ion transporters in hypoxic cells. Cerebral edema causes progressive neurologic decline by raising intracranial

- **Vasogenic edema** follows 24-48 hours later, when the release of inflammatory mediators disrupts the tight junctions of the blood-brain barrier, allowing proteins (eg, albumin) and water to enter the interstitial space. This vasogenic phase can cause persistent cerebral edema for weeks after the initial injury.

(Choice A) Although a decrease in oncotic pressure can cause peripheral edema (eg, nephrotic syndrome), it is not a significant factor in the development of cerebral edema. Mannitol is used in the treatment of cerebral edema because it increases plasma oncotic pressure and temporarily disrupts the blood-brain barrier, allowing movement of fluid out of the CNS to decrease ICP.

(Choice C) Inadequate absorption of cerebrospinal fluid at the arachnoid granulations can cause communicating hydrocephalus. Although this process raises ICP, ventriculomegaly would likely be prominent on CT scan.

(Choice D) Increased hydrostatic pressure secondary to central venous thrombosis or hypertensive encephalopathy can cause cerebral edema and increased ICP. However, patients typically have gradually worsening headache before development of neurologic abnormalities.

(Choice E) Gliosis is the process of repairing damaged tissue in the CNS by proliferating astrocytes and microglia. This process occurs slowly in the months to years after CNS injury and would not be expected to cause acute changes in ICP.

Educational objective:
The primary mechanism underlying cytotoxic (early) edema following cerebral ischemia is the accumulation of intracellular Na^+ and water due to the failure of ATP-dependent ion transporters in hypoxic cells. Cerebral edema causes progressive neurologic decline by raising intracranial pressure, which can directly damage neural tissue or result in mechanical damage due to brain herniation.

References

- Brain edema after ischaemic stroke.

Pathology	Nervous System	Ischemic stroke
Subject	System	Topic

Copyright © UWorld. All rights reserved.